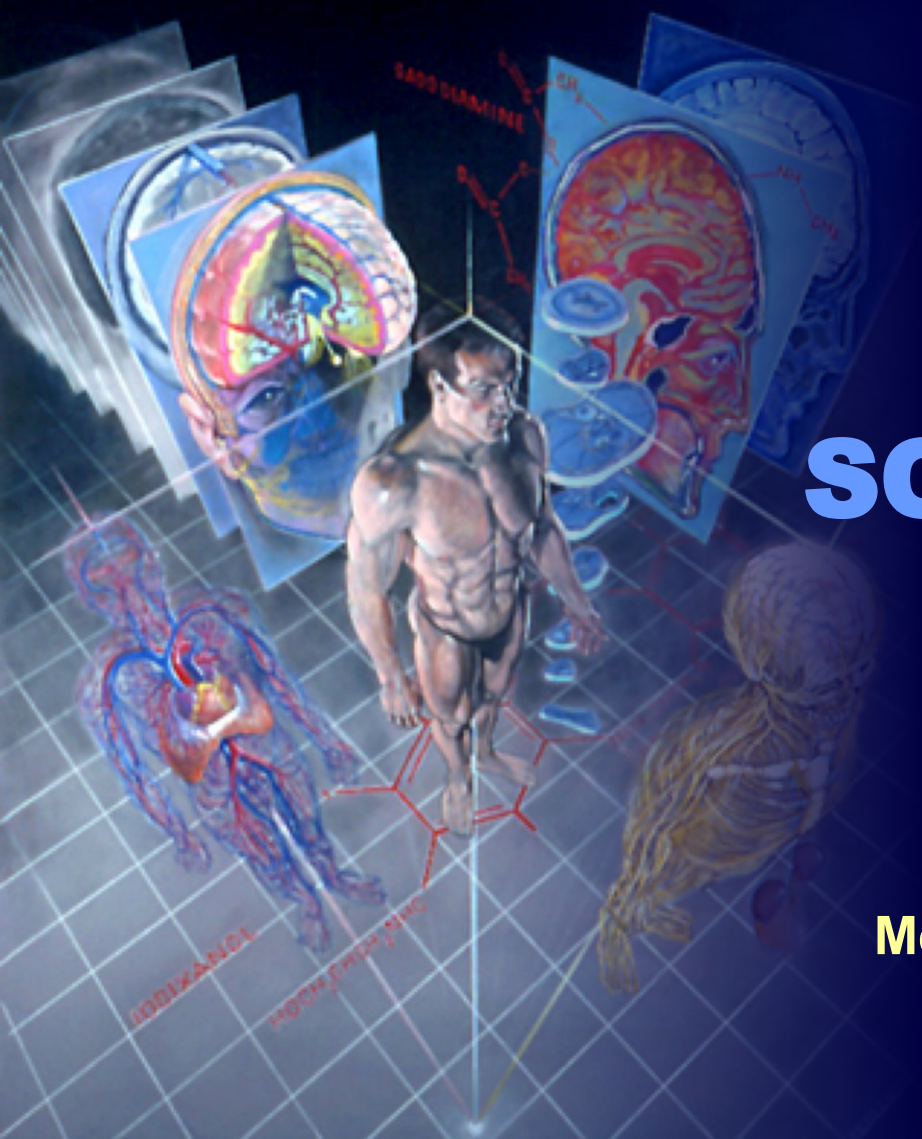

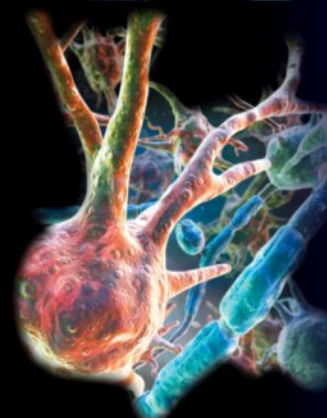
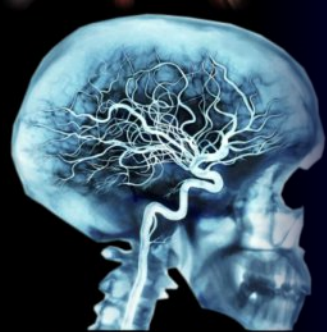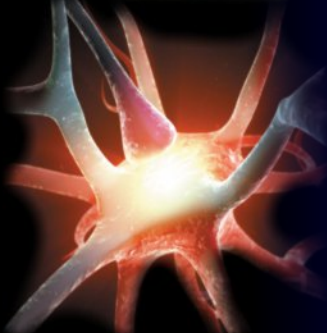
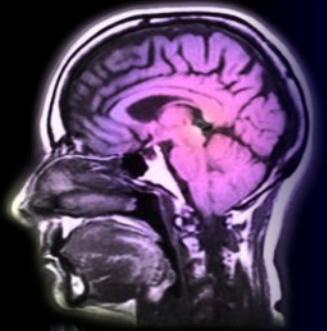# SOMATOSENSORY DISORDERS

**R. BENACKA**

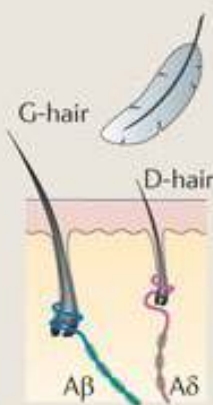


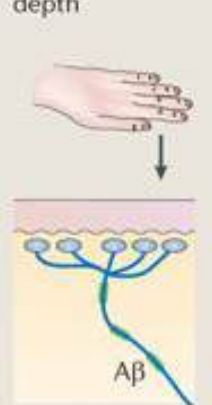

















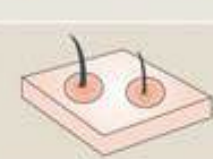






Department of Pathophysiology  
Medical Faculty, P.J. Safarik University,  
Košice, Slovakia

# Notes

- **Brain creates the world** = everything what we perceive is a product of the brain. Brain not only process and explains the stimuli of „real“ world (**projection**), it creates the perceptions without stimuli (**hallucinations**).
- Somesthetic apparatus **is a projection system** - providing information on somatotopic organisation of different parts of the body
- The number of perceived qualities always exceeds the number of known receptoric modalities; i.e. there is a **integration of perceptions** (spinal cord, stem, thalamus, cortex, parietal cortex)
- Topical organization - the ability of **spatial and temporal discrimination**;
- Topical integrative is important for building of **selfawareness**
- Perception is always subjective



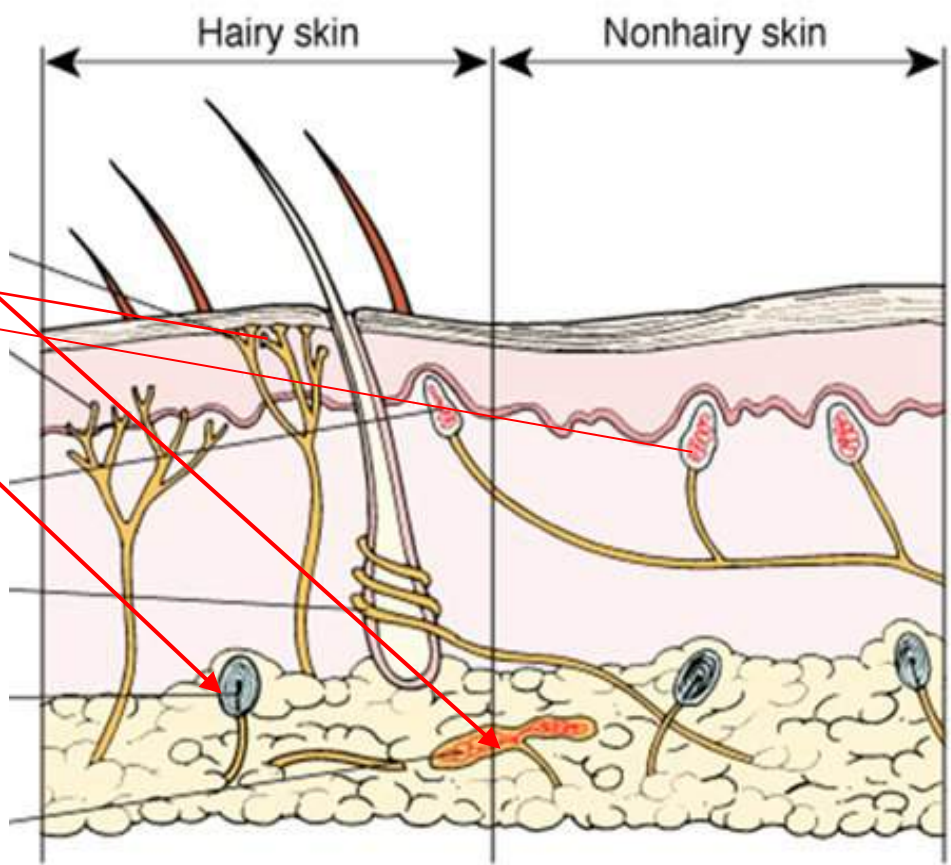
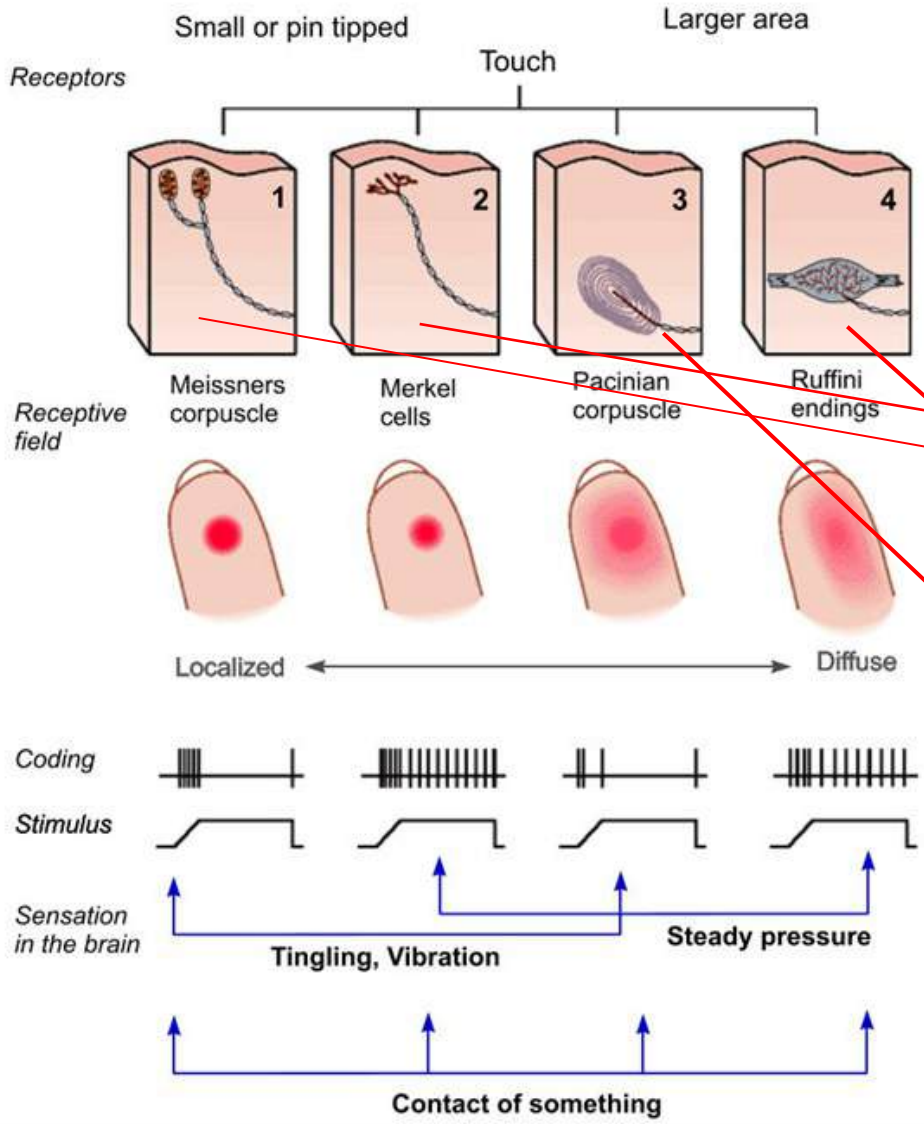
# Mechanosensitive receptors

Receptor subtype	Hair follicles	Meissner corpuscle	Pacinian corpuscle	Merkel cell-neurite complex	Ruffini corpuscle	C-fibre LTM	Mechano-nociceptor Polymodal nociceptor
<b>Skin stimulus</b>	Light brush 	Dynamic deformation 	Vibration 	Indentation depth 	Stretch 	Touch 	Injurious forces 
<b>Afferent response</b>	RA, LT 	RA, LT 	RA, LT 	SA, LT 	SA, LT 	SA, LT 	SA, HT 
<b>Stimulus</b>							
<b>Receptive field</b>							
<b>Perceptual functions</b>	Skin movement	Skin motion; detecting slipping objects	Vibratory cues transmitted by body contact when grasping an object	Fine tactile discrimination; form and texture perception	Skin stretch; direction of object motion, hand shape and finger position	Pleasant contact; social interaction	Skin injury; pain

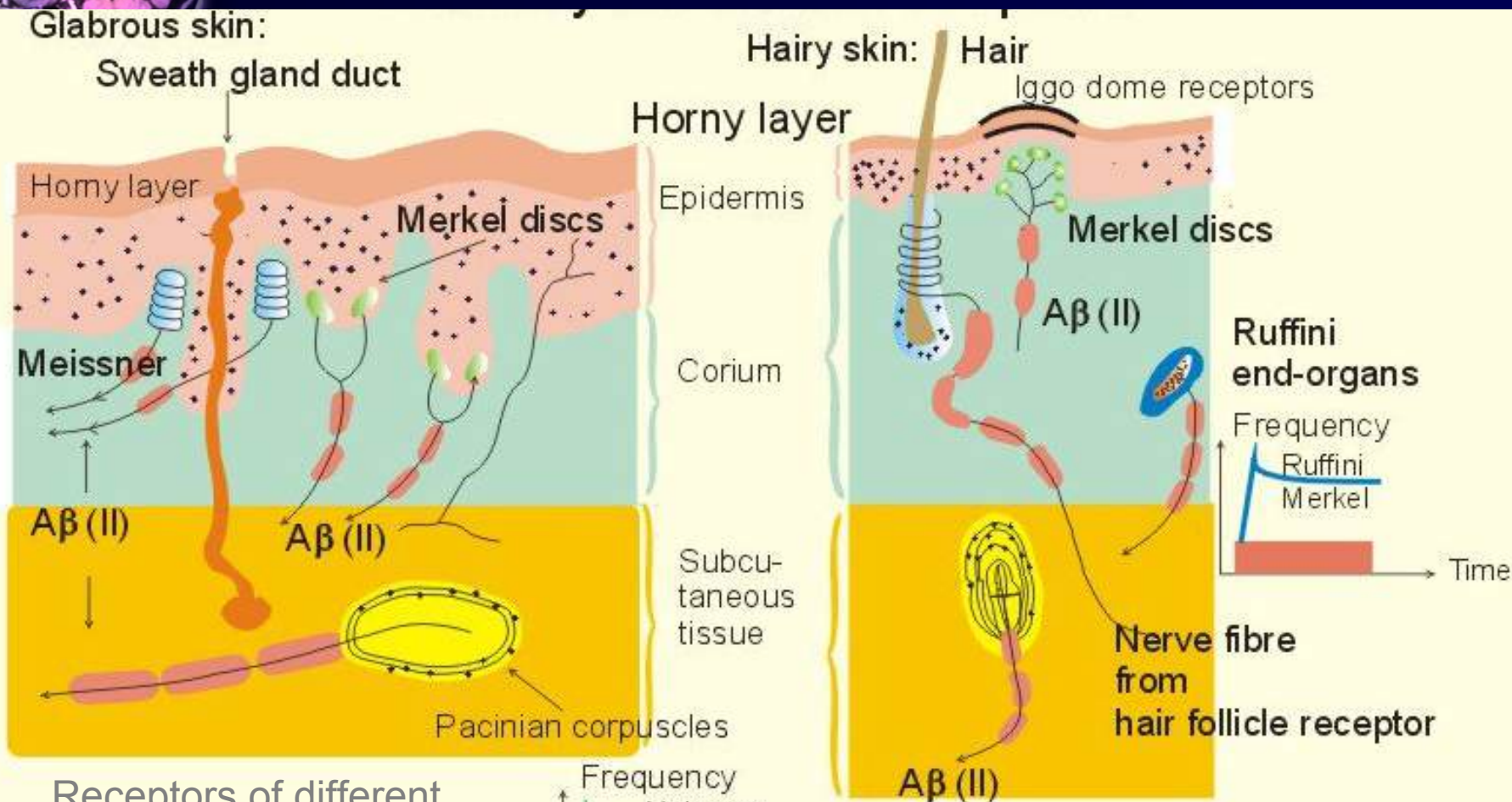
# Integration of various modalities of somatosensitivity



Stimulus



# Somatosensory receptors



Receptors of different types, subtypes (threshold, duration), of various modalities

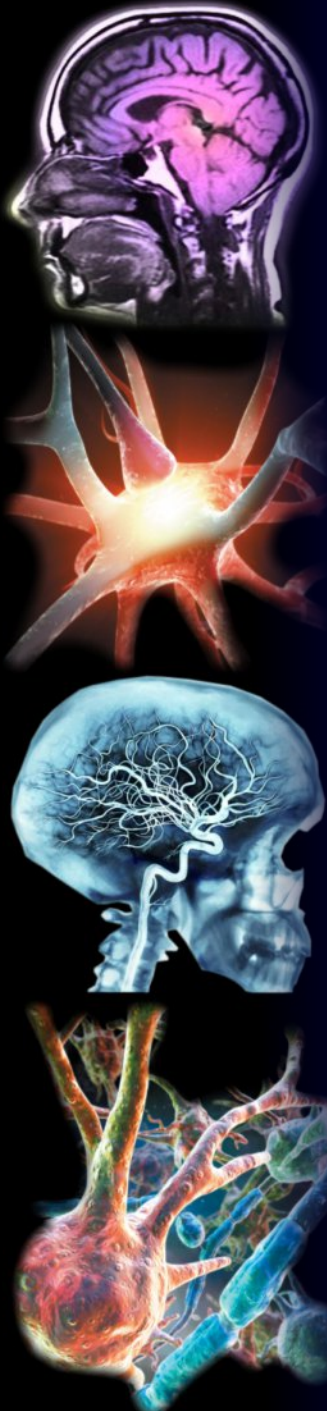cutaneous, intradermal, tissue, muscles, bones, tendons

# Somatosensory pathways

## Spinal pathways

- **Ventrolateral system** (tr. spino-reticulo-thalamicus in ventrolateral part)
  - Heat, cold, pain, deeper, coarser tactile or pressure stimuli, so called protopathic sensitivity
  - Contralateral half of the body + 2 segments down
- **Posterior system** (fasciculus gracilis et cuneatus) –
  - Proprioception - joints, tendons, muscles (stathesia, kinesthesia)
  - Integrative sensations – palesthesia, baresthesia, so called epicritic sensation
  - Homolateral part of the body – segments + dermatomes
- **Paralateral bundles (Lissauer tract)** spinoreticular pathways
- **Spinocerebellar anterior et posterior** proprioceptive sensations ( kinesthesia, stathesia, pressure)

## Brainstem pathways



**Motor and descending (efferent) pathways (red)**

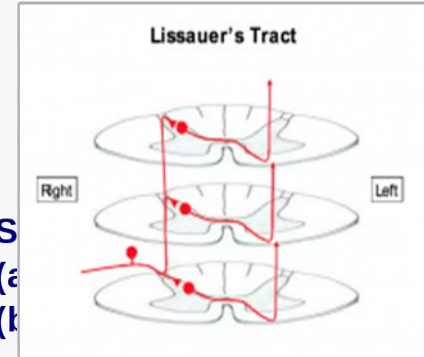
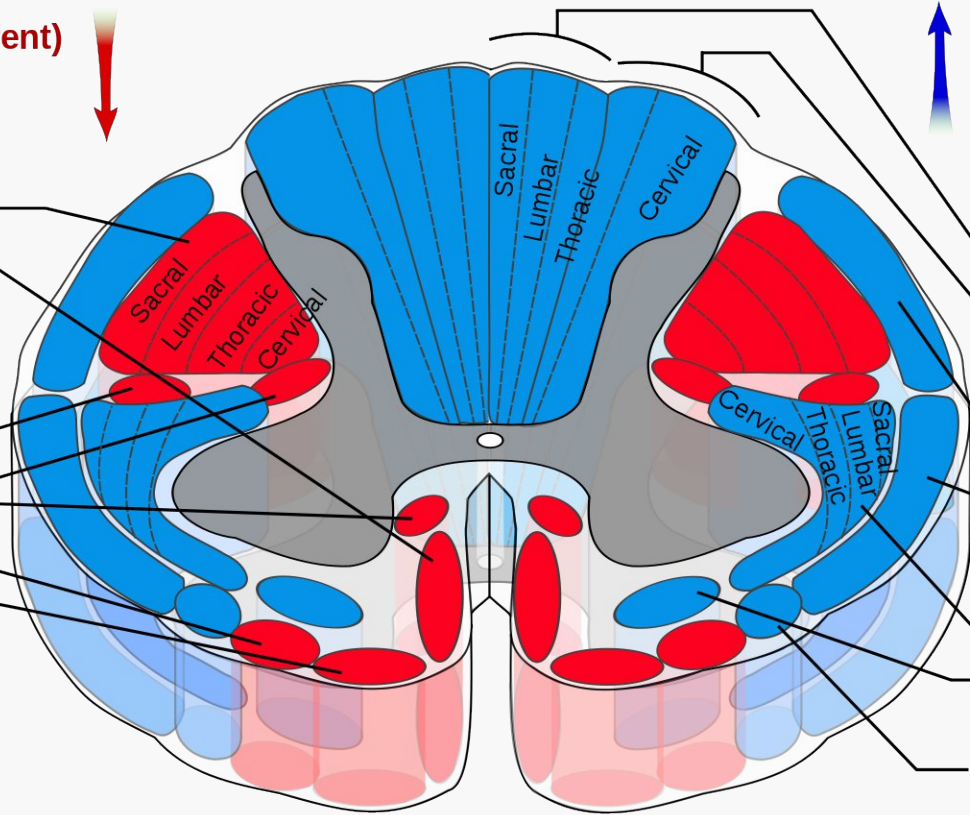


**Pyramidal tracts**

- Lateral corticospinal tract
- Anterior corticospinal tract

**Extrapyramidal Tracts**

- Rubrospinal tract
- Reticulospinal tracts
- Olivospinal tract
- Vestibulospinal tract



**Dorsal Column Medial Lemniscus System**

- Gracile fasciculus
- Cuneate fasciculus

**Spinocerebellar Tracts**

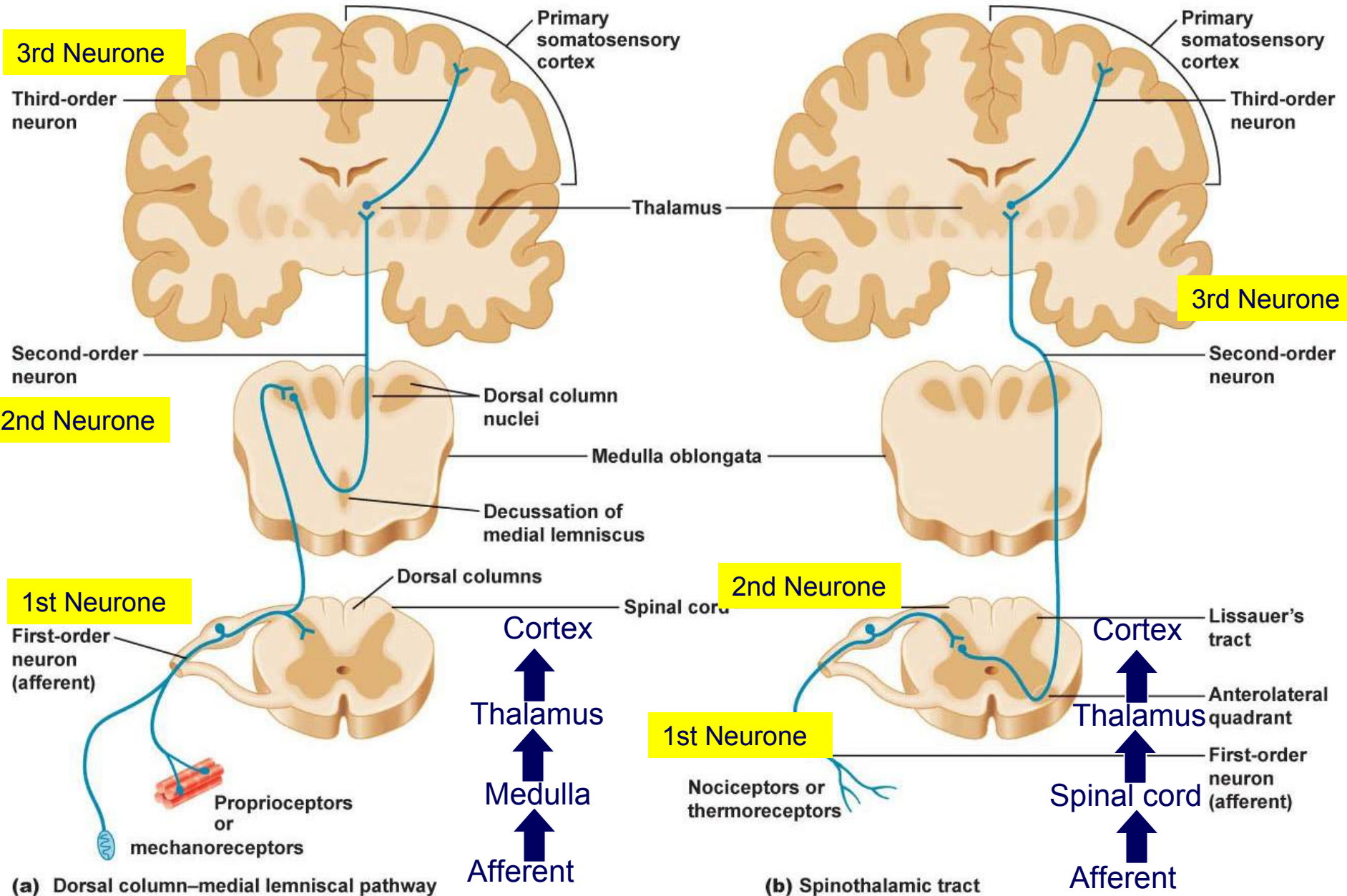
- Posterior spinocerebellar tract
- Anterior spinocerebellar tract

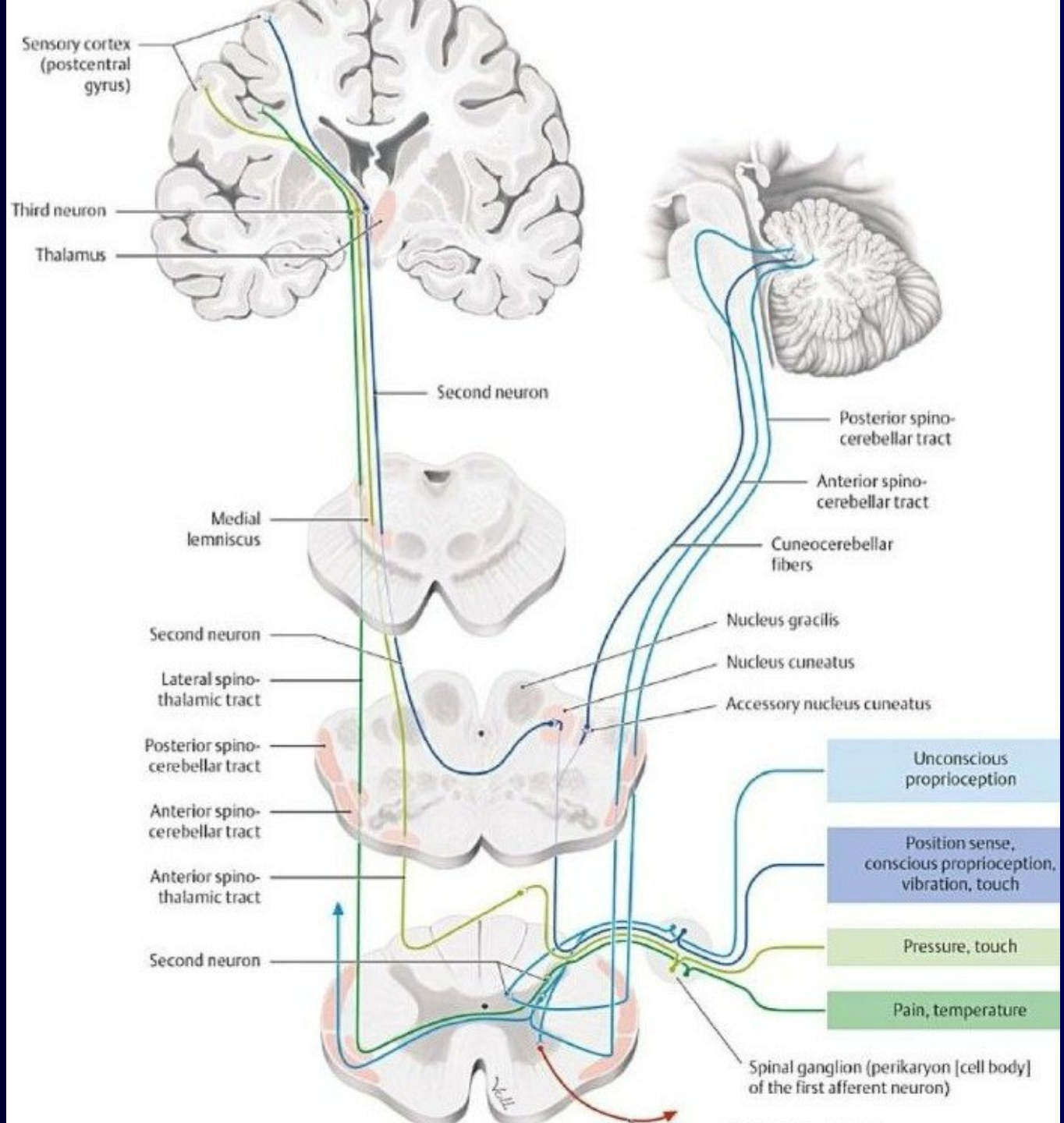
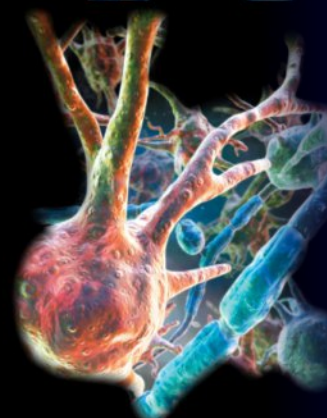
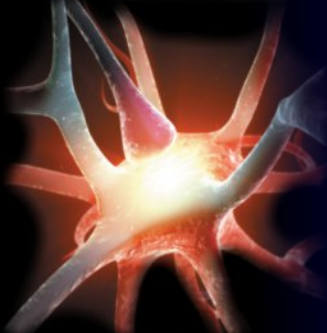
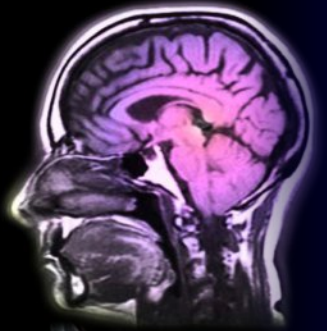
**Anterolateral System**

- Lateral spinothalamic tract
- Anterior spinothalamic tract

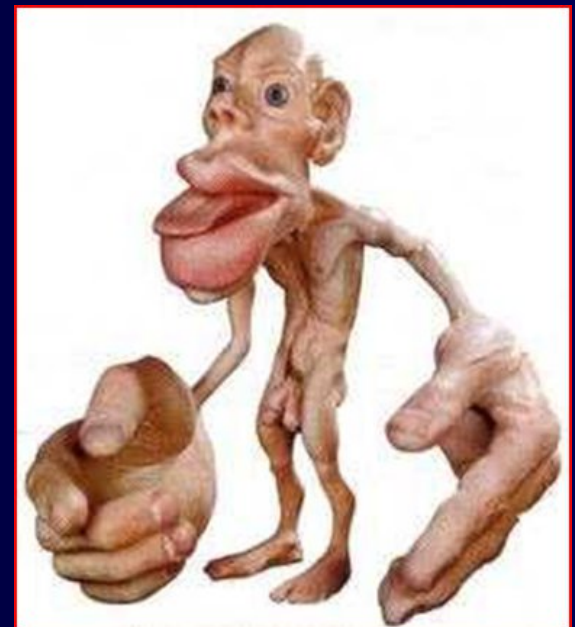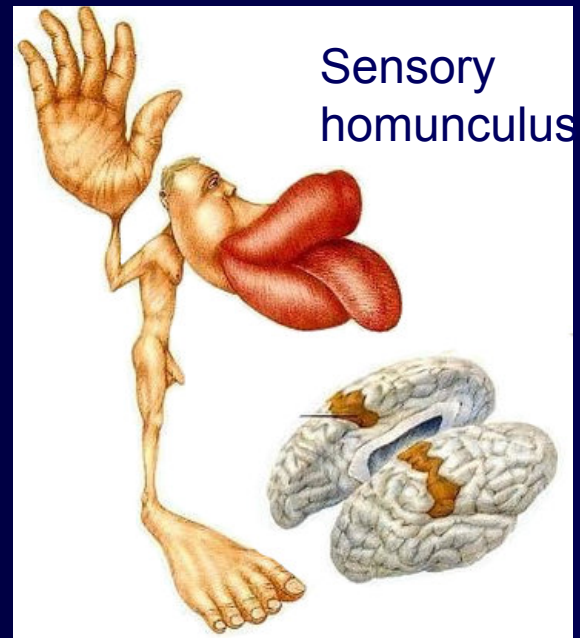
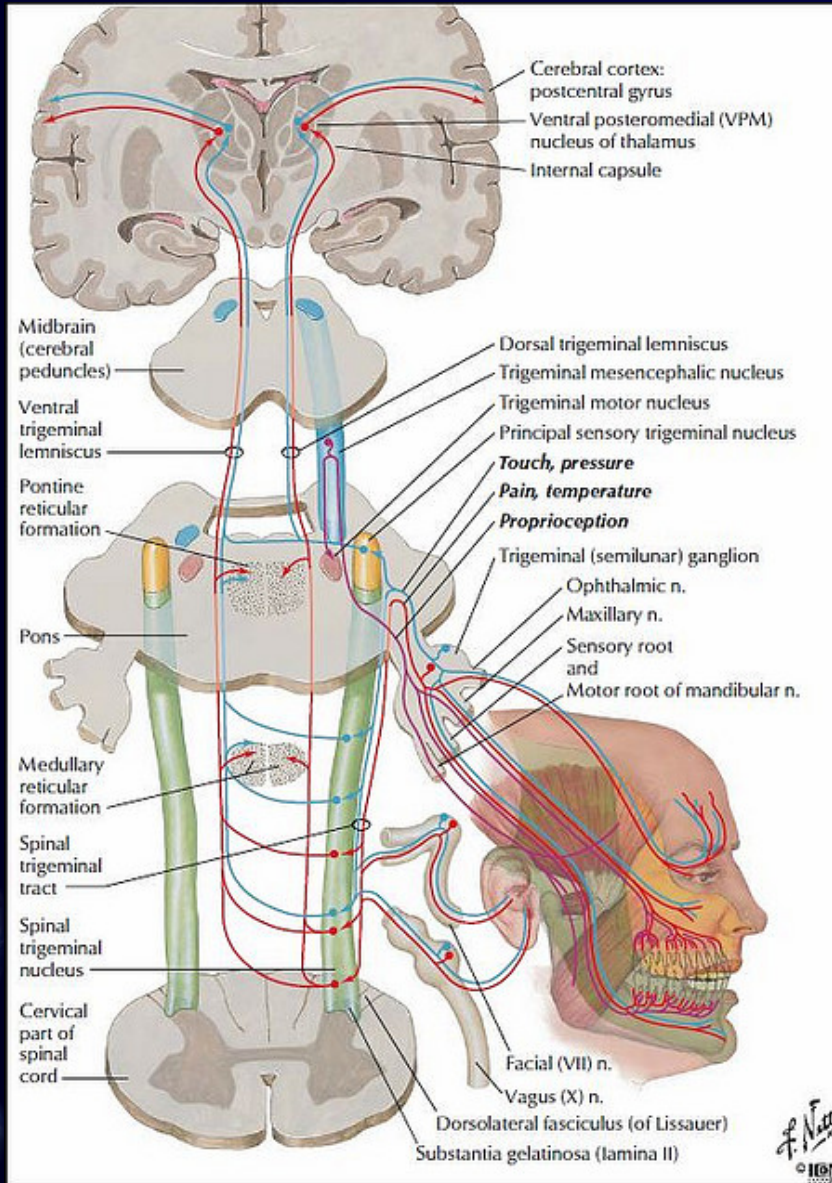
Spino-olivary fibers

# Anterior-lateral & dorsal sensory pathways





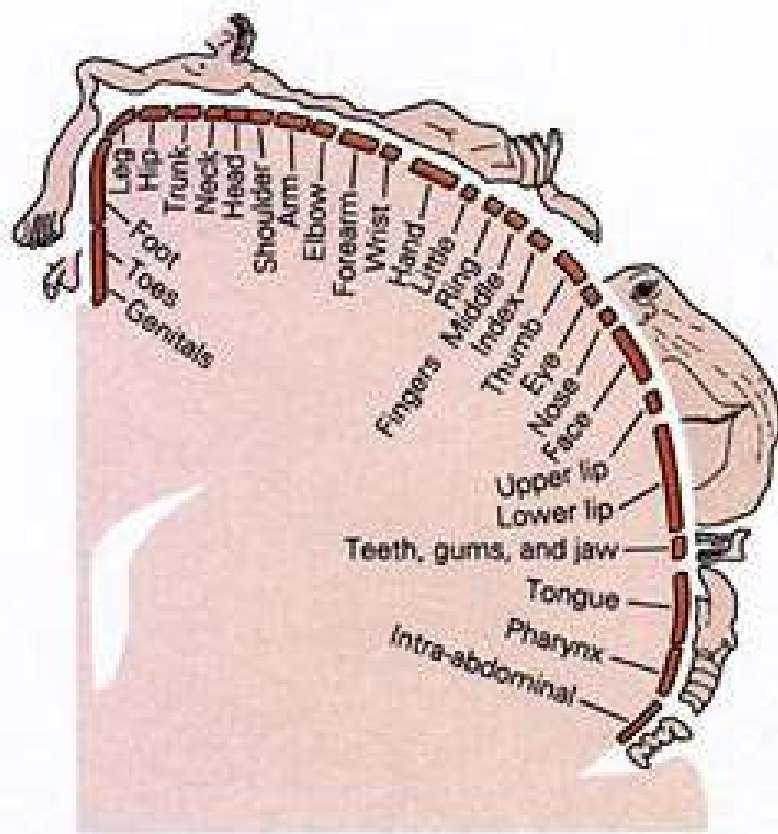
# Somatosensory system



# Comparison of cortical presentation

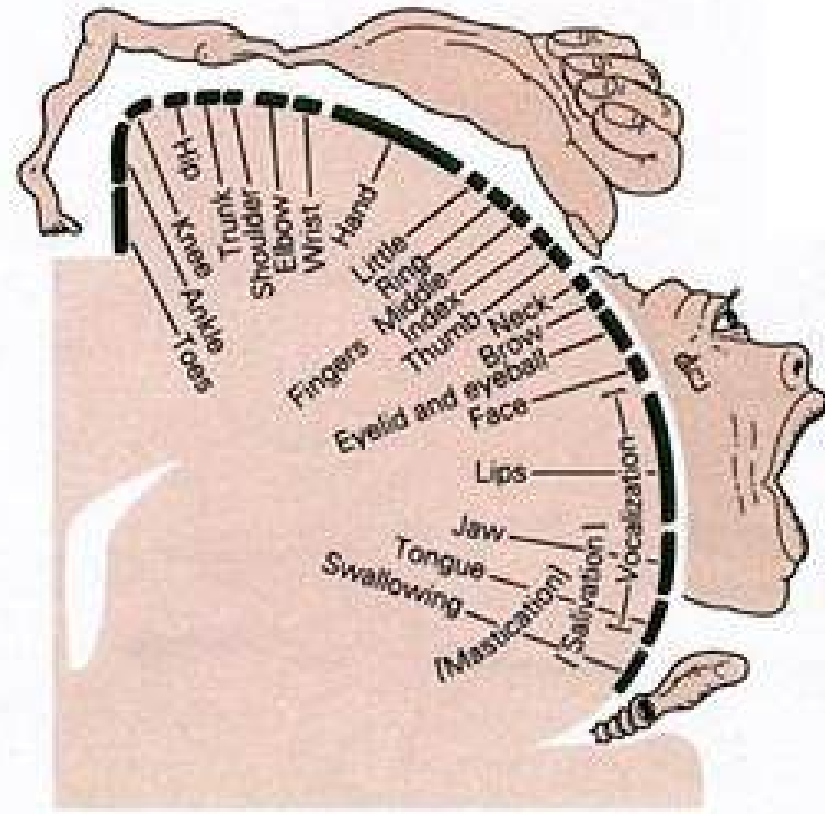
Sensory homonculus

Motor homonculus



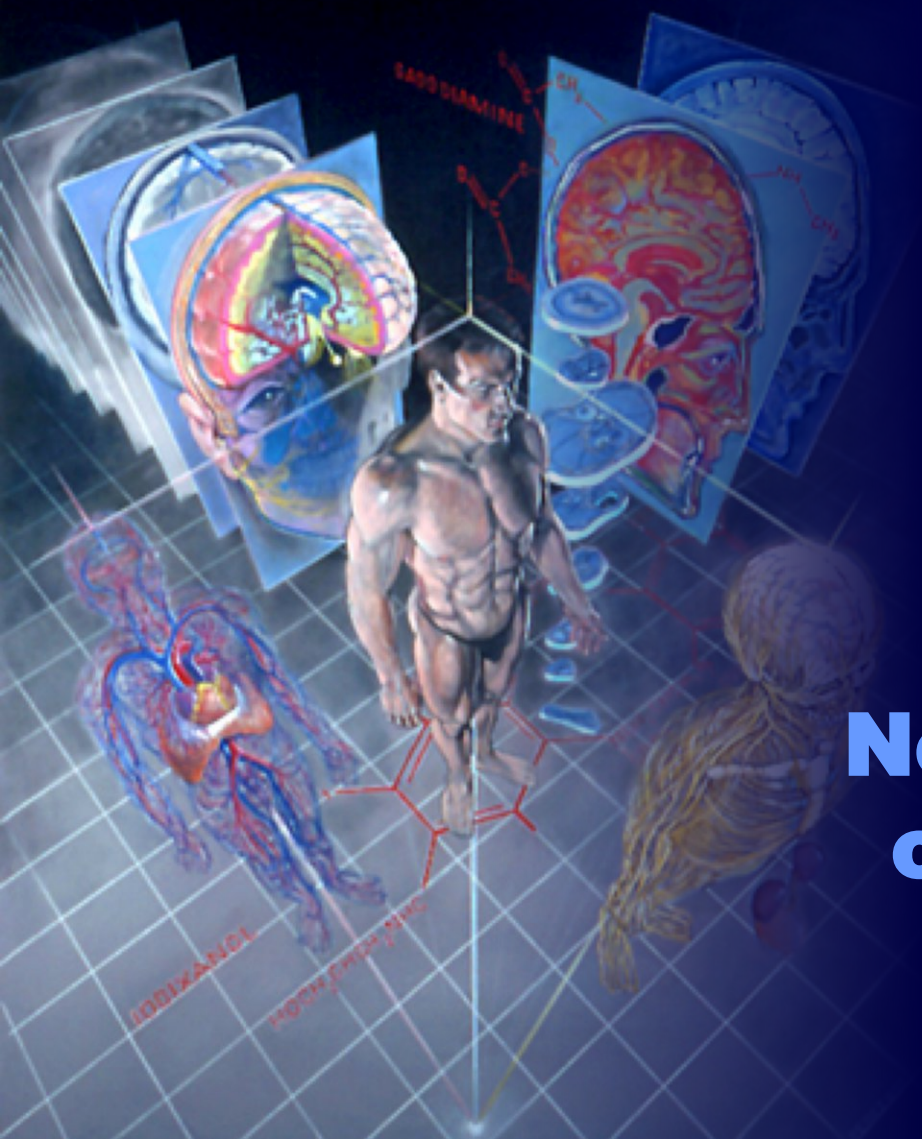
Medial

Lateral



Medial

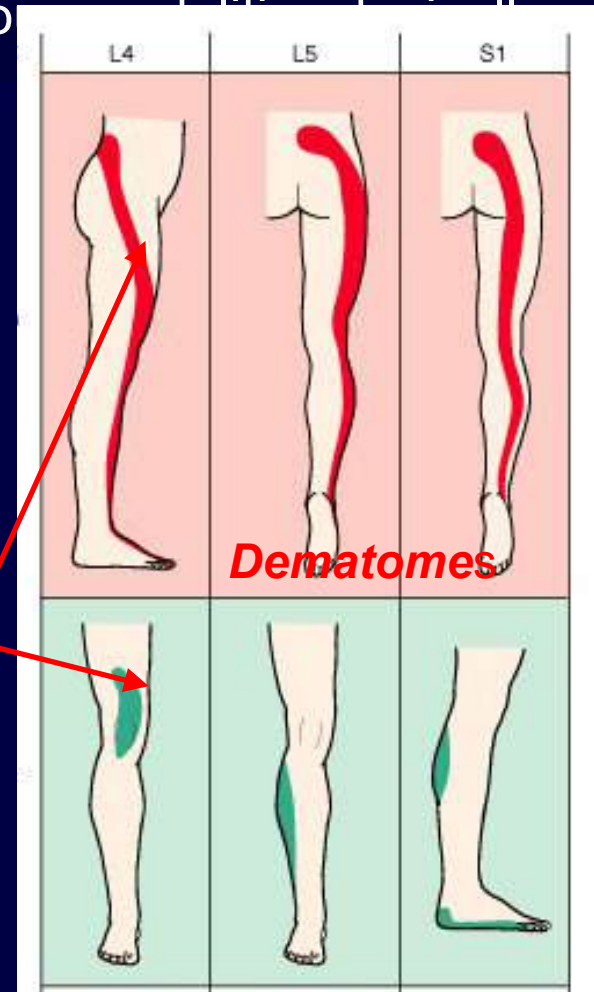
Lateral



# Clinical Neuropathophysiology of sensory disorders

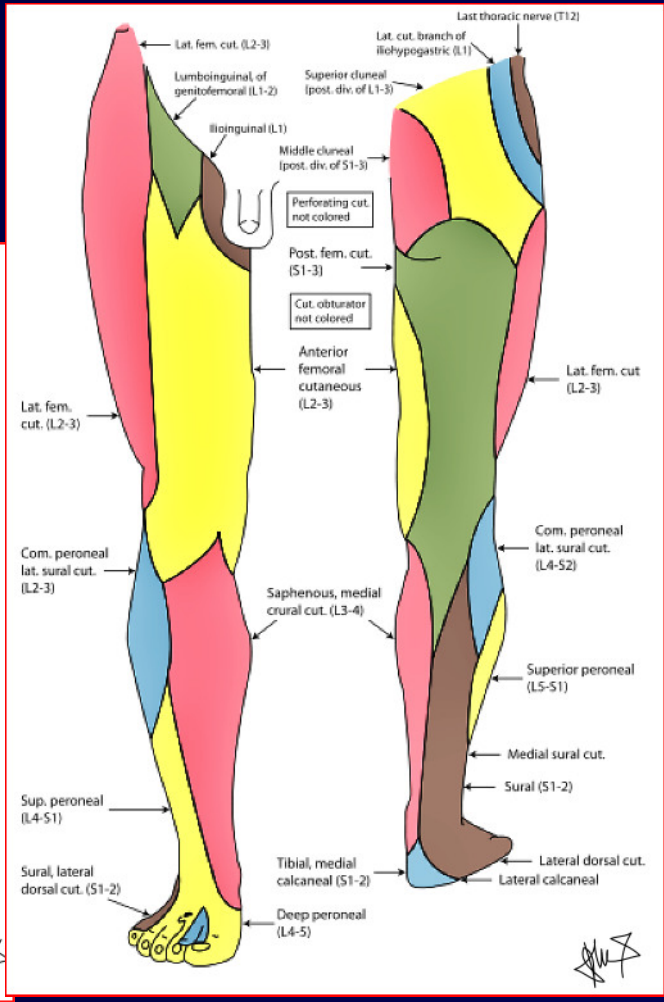
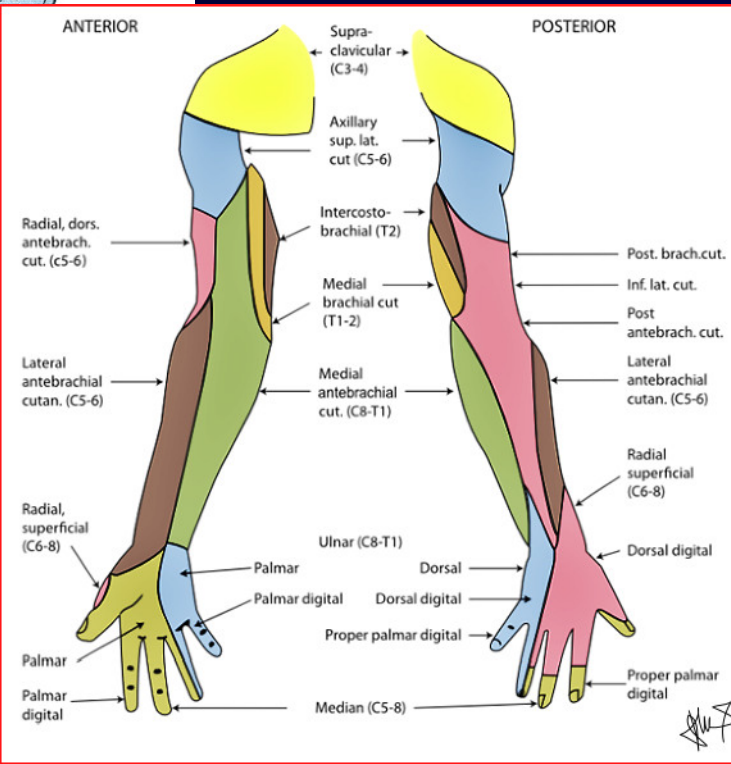
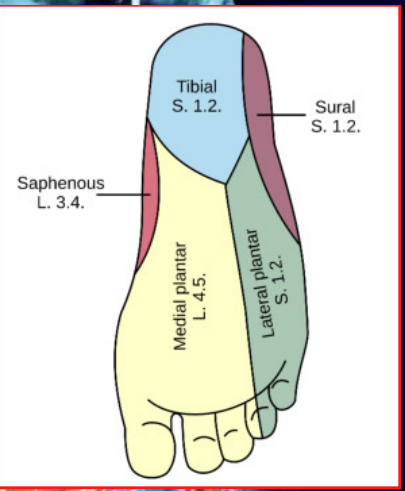
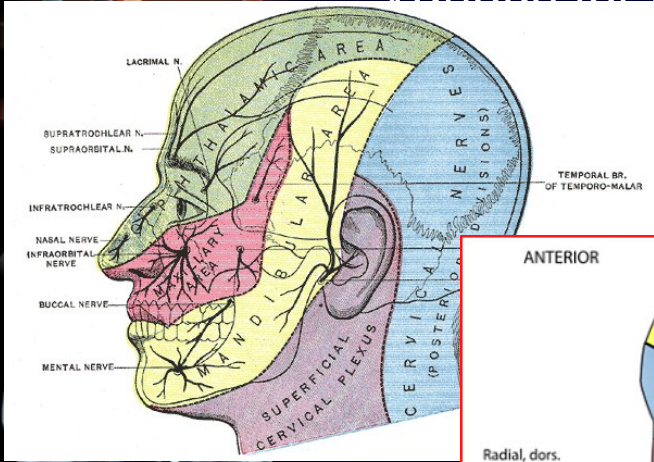
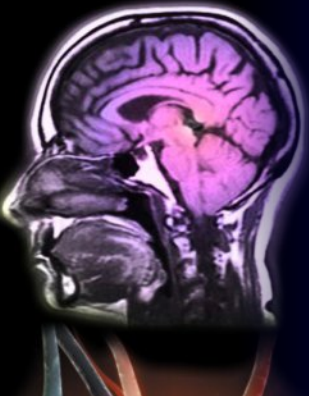# Sensory supply – principles

- **Lesions of peripheral sensory nerve = manifested in within area nervina** = area of the skin supplied by afferents from particular sensory nerve; symptoms differ according to **peripheral nerve laesion or irritation**
  - The border of area nervina may differ for vario  
largest area is for the pain
- **Lesion on the level of spinal segmenr or dorsal root = manifested over dermatome** = skin area supplied by affrents coming into one segment of the spinal cord; symptoms of **radicular nerve damage**
  - The border of area may slightly differ for various modalities – **largest dermatomes are for pain** nad temperature sensations;
  - The borders of neighboring dermatomes **overlap - largest overlap** is in between areas for pain
  - **Different „dermatome areas“ exist for irritation** symptoms (e.g hyperesthesia, pain; red) and for laesion symptoms (numbness: green)



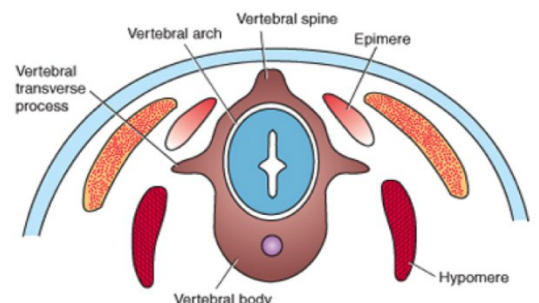
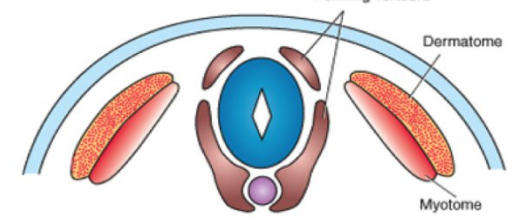
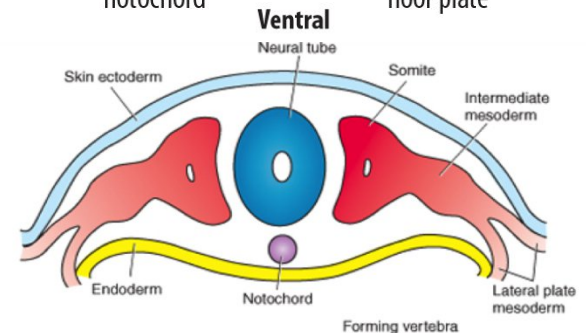
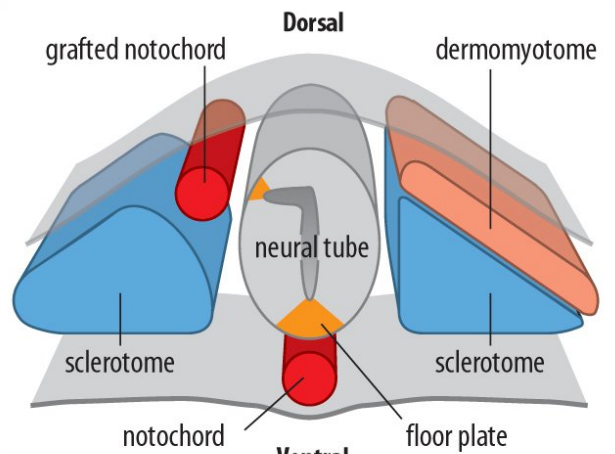
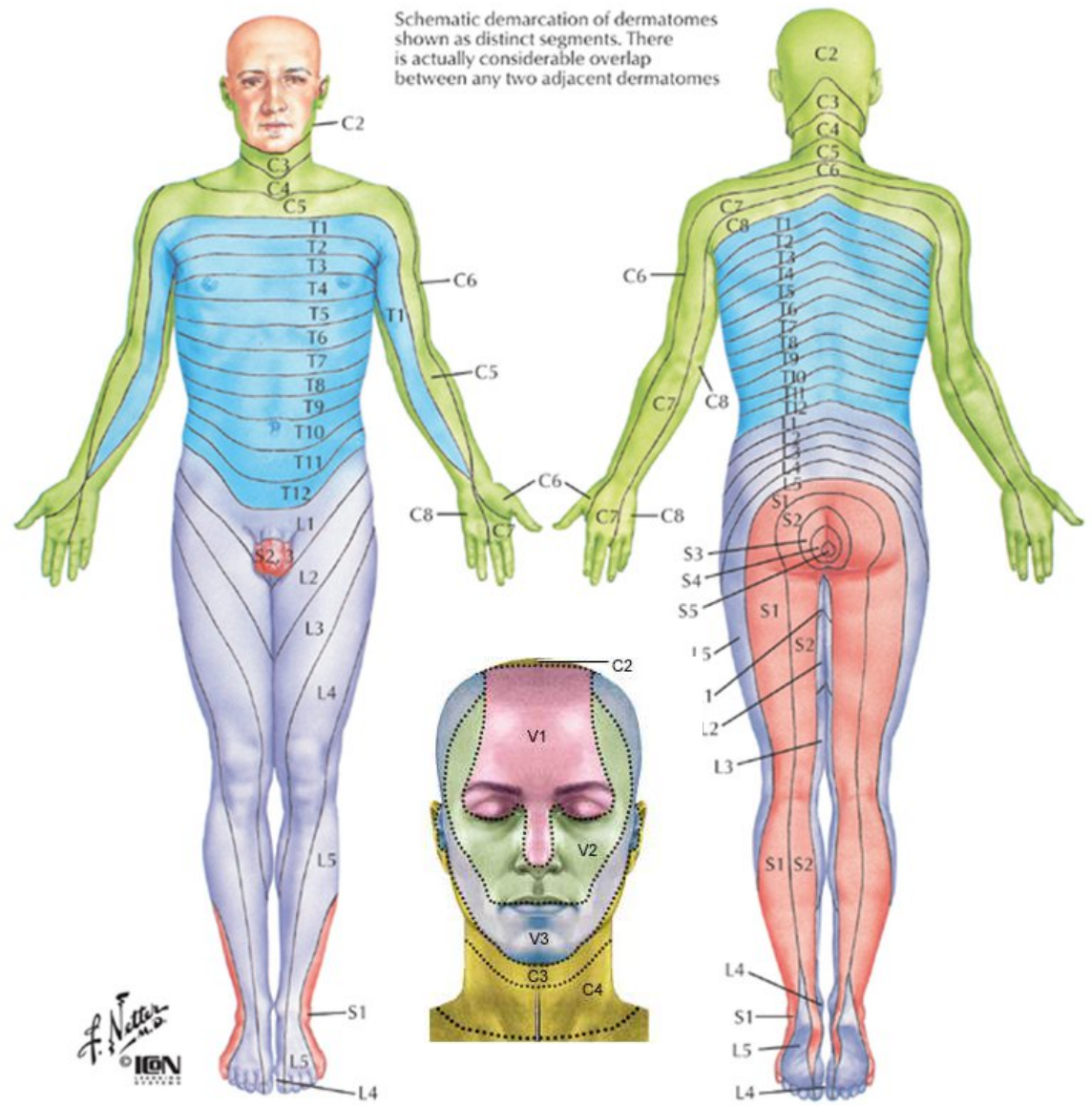
# Area nervina

- Skin area supplied and responding to thermal, pressure, chemical and other stimuli by specific sensory by one sensory nerve
- Various for different modalities



# Dermatomes

Schematic demarcation of dermatomes shown as distinct segments. There is actually considerable overlap between any two adjacent dermatomes



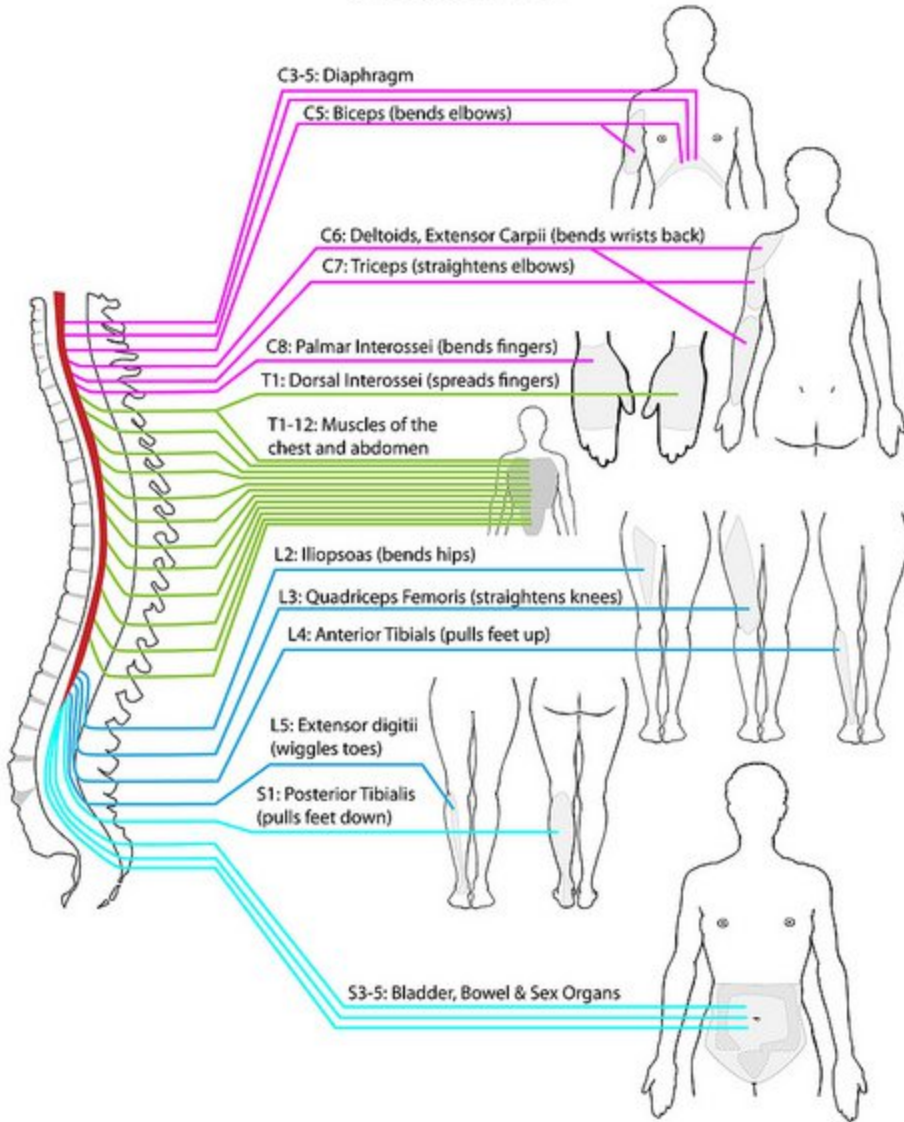
### Levels of principal dermatomes

- C5 Clavicles
- C5, 6, 7 Lateral parts of upper limbs
- C8, T1 Medial sides of upper limbs
- C6 Thumb
- C6, 7, 8 Hand
- C8 Ring and little fingers
- T4 Level of nipples

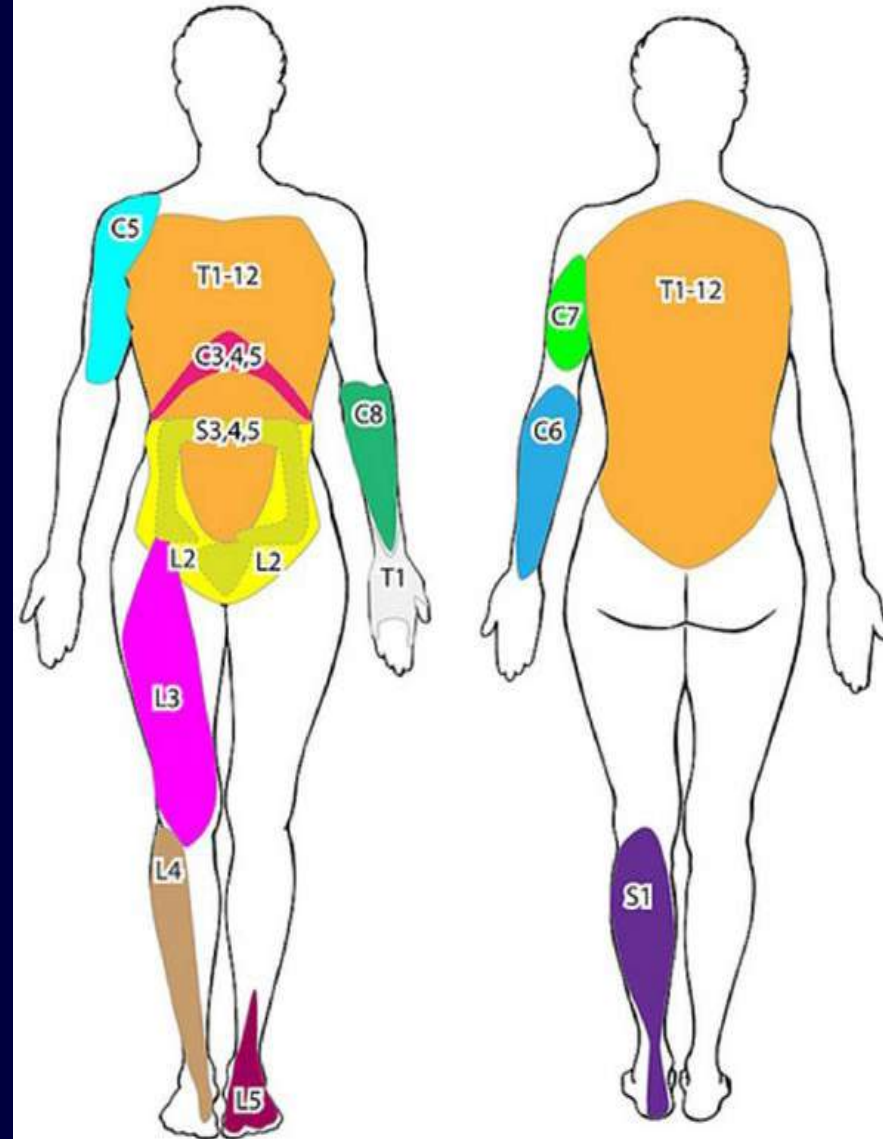
- T10 Level of umbilicus
- T12 Inguinal or groin regions
- L1, 2, 3, 4 Anterior and inner surfaces of lower limbs
- L4, 5, S1 Foot
- L4 Medial side of great toe
- S1, 2, L5 Posterior and outer surfaces of lower limbs
- S1 Lateral margin of foot and little toe
- S2, 3, 4 Perineum

# Myotomes

## MYOTOMES



## MYOTOMES



# Disorders of somatosensitivity

---

## Mechanism of disorder:

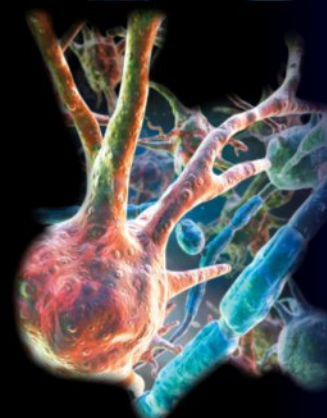
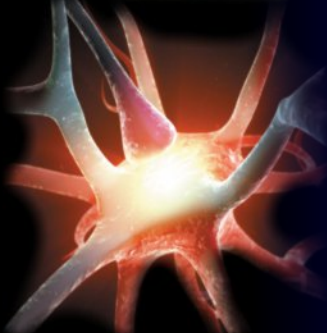
- **Functional changes** (e.g. transient disorders, decrease of nerve conductance or receptor activity)
- **Organic destruction of somesthetic structures** (nerves, plexuses, dorsal roots, columns, pathways, thalamus, cortex)

## According to a type of disorder:

- **Loss of function** (decrease or loss of sensitivity to normal stimuli; e.g. anaesthesia, hypesthesia)
- **Gain in function** (increase of sensitivity; suprathreshold or normal stimuli, e.g. hyperesthesia, hyperalgesia)

## According to quality:

- **Quantitative** (in terms of plus- minus)
- **Qualitative** (atypical locations, distribution,





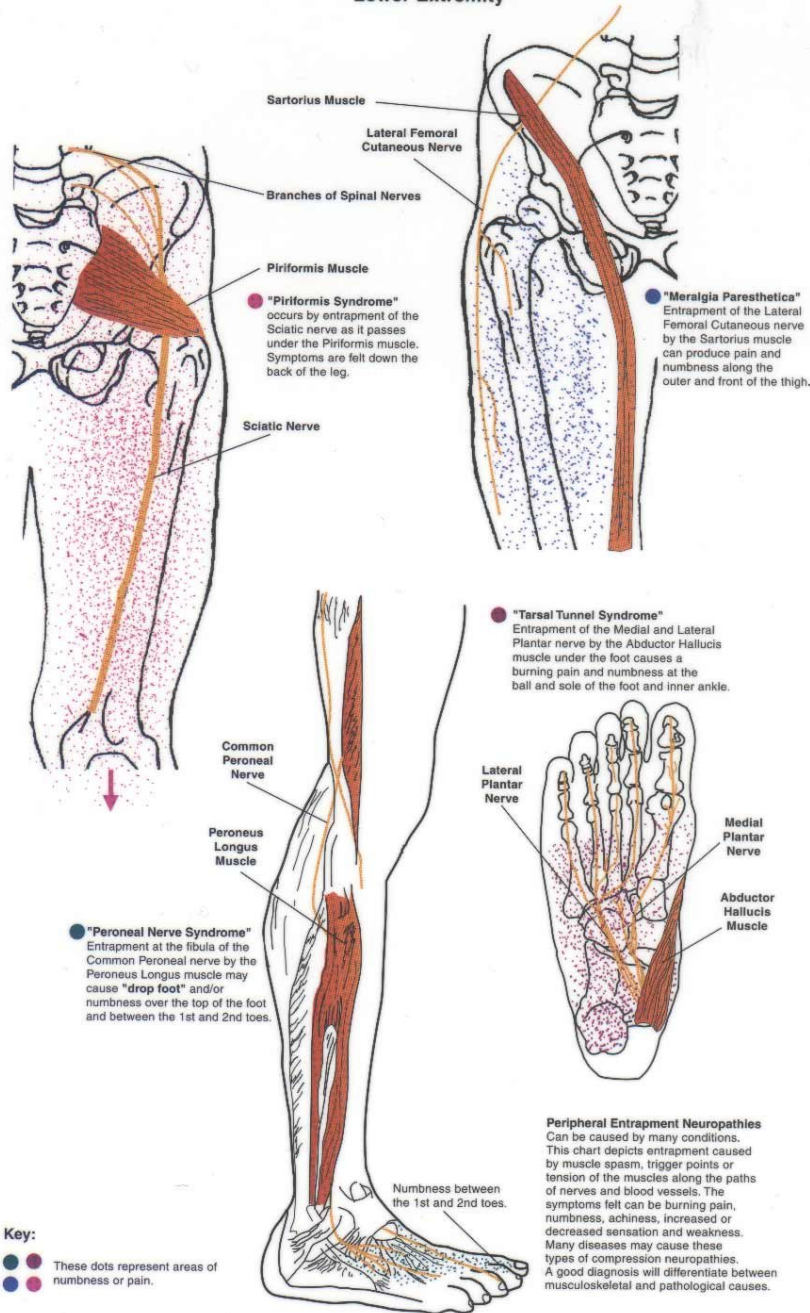
# Loss of function disorders

---

- **Hypesthesia & anesthesia** = decrease or loss of sensitivity for one or several sensory modalities (e.g. mechanical, thermal, pain).
- **Associated anesthesia** = contemporary disorders of all sensory modalities  
Cause: traumatic interruption of sensory or mixed nerve and dorsal root or temporary knockout (eg. local, a drain or epidural anesthesia). Anesthesia occurs in supplies to the nerves (Area nervina) or roots (dermatomes).
- **Dissociated anesthesia** = not all sensory modalities are affected  
Cause: partial damage, application of anesthetic drug  
Numbness occurs in the following order: **fine tactile sensitivity > thermosensation > coarser pressure sensitivity > perception of cold > pain.**  
Nociceptive sensitivity has the lowest threshold (the most difficult is to exclude it), and the largest attachment area (supply overlap).

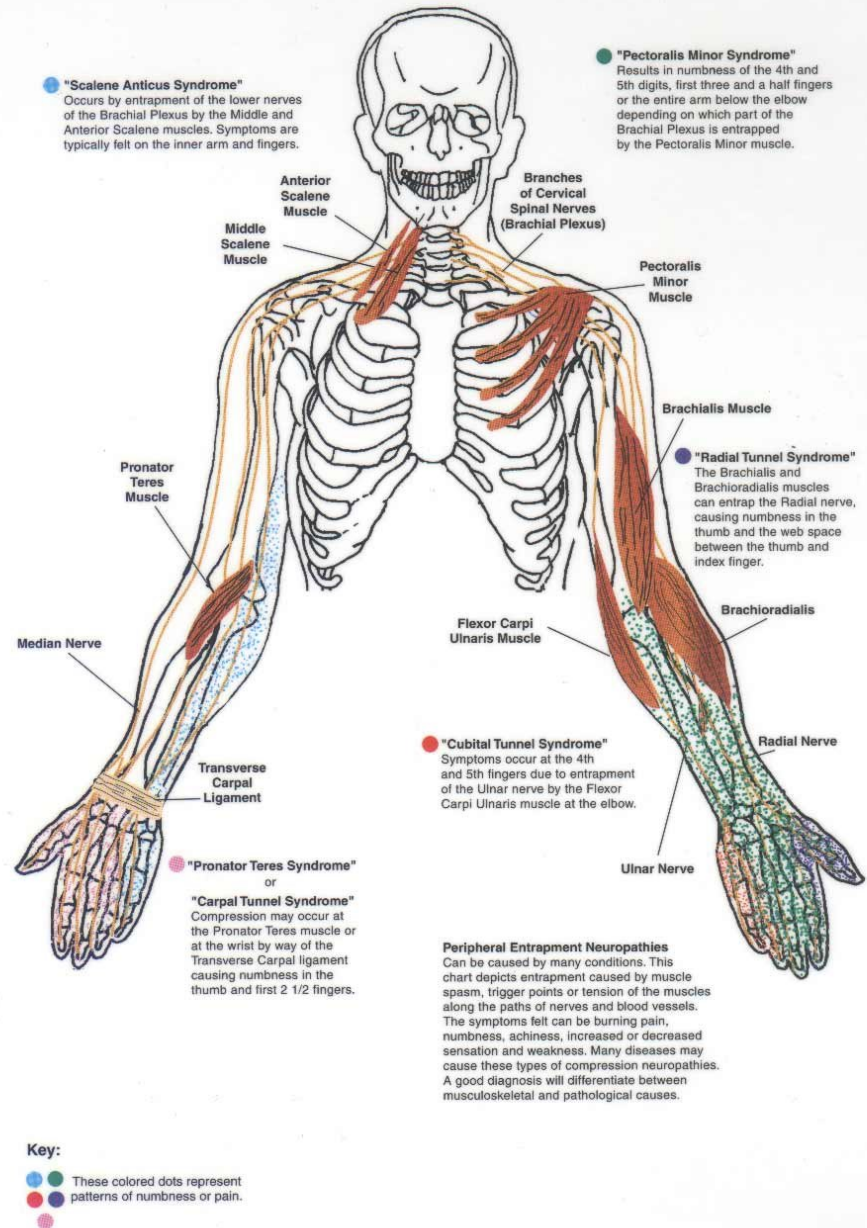
# Peripheral Entrapment Neuropathies

## Lower Extremity



# Peripheral Entrapment Neuropathies

## Upper Extremity

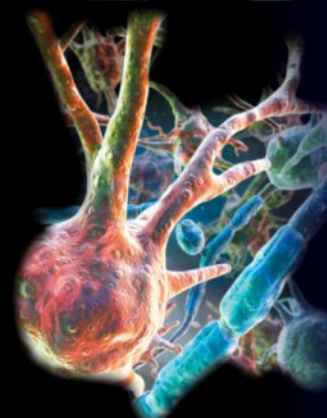
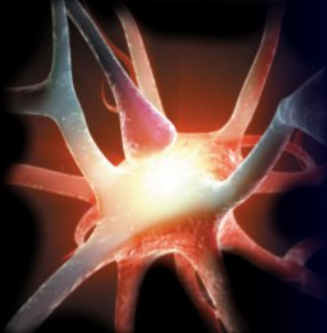
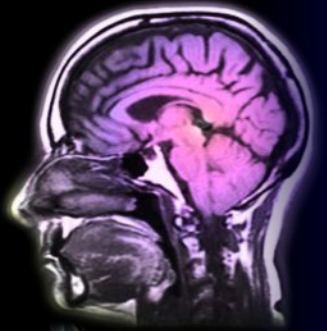


# Gain in function disorders of sensitivity

- **Peripheral disorders** - mechanical compression (oppression) and/or ischemia of nerves (vasa nervorum) and the surrounding tissue
- **Central disorders** is at the level of the spinal cord, the thalamus and the cerebral cortex.

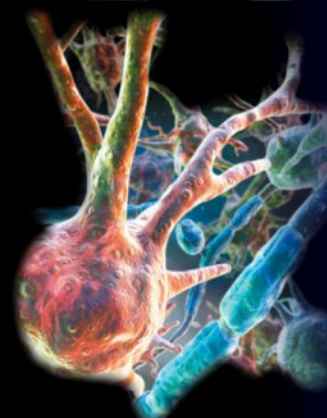
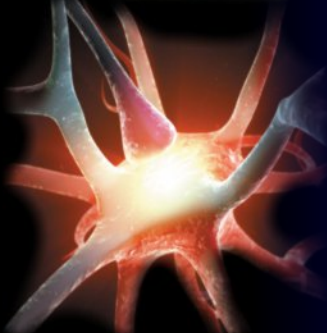
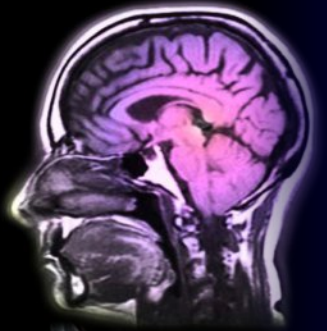
## Types:

- **Hyperesthesia** - it is pathologically increased excitability to any particular sensory stimuli or an all modalities.
- **Hyperpathia** - failure of perception, in which the stimuli of low intensity and different modalities are perceived as unpleasant and painful sensations,
- **Paraesthesia** – perception of the unobvious sensations (tingling, pinning, burning, etc. )

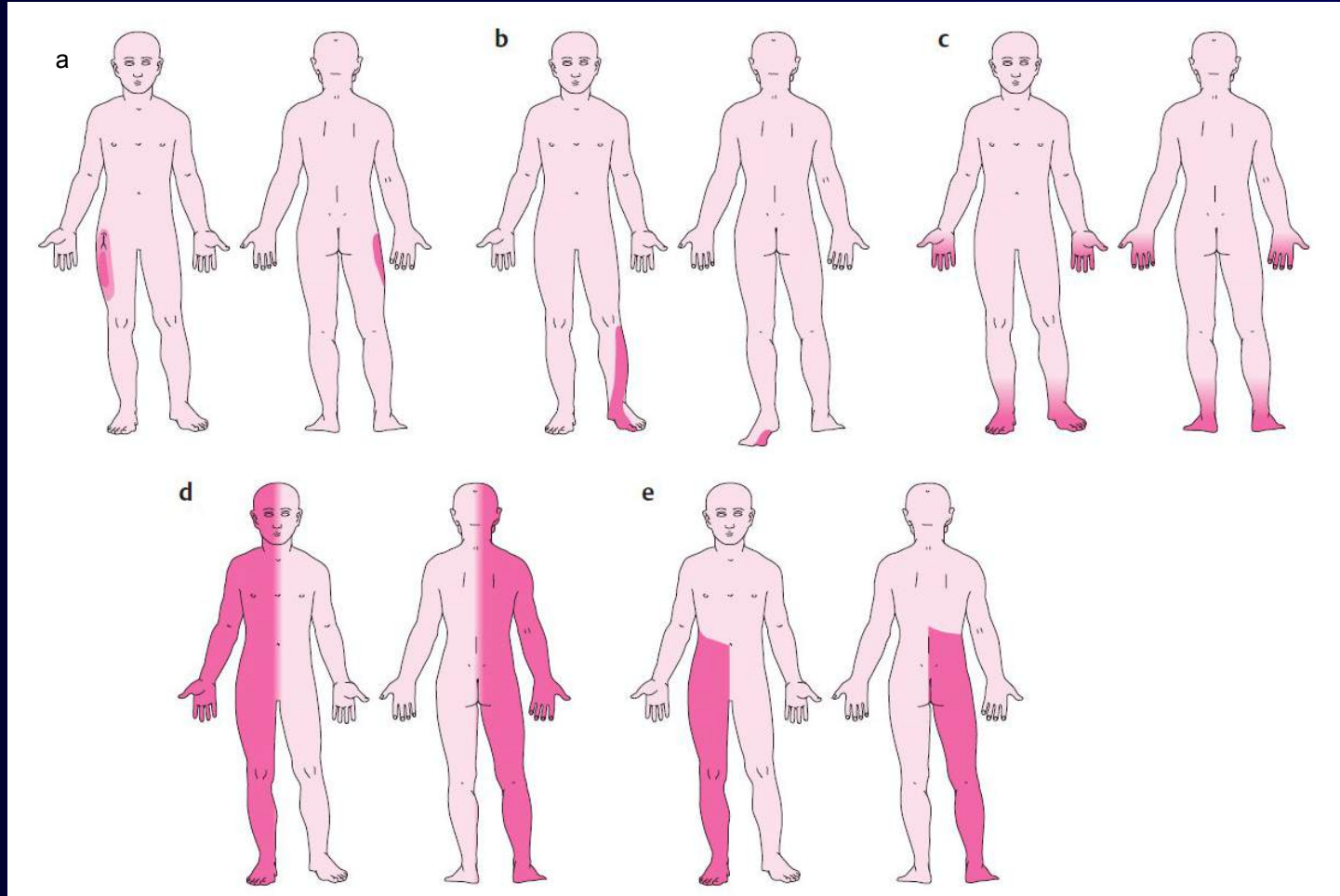


# Gain in function (irritative) disorders of sensitivity

- **Pruritus (itching)** – unpleasant sensation associated with scratching;  
Cause: epidermal receptor irritation (below the threshold of pain).
- **Titillatio (tickle)** - is somesthetic sensation like itching, but less intense. Generically considered as subthreshold form of pain.
- **Paresthesias** -
- **Algia (pain)** - is a special somesthetic sensation arising in cases when the intensity of external or internal stimulus of any kind is approaching the limits of destroying the integrity of a particular body part. Has its localisation value, informationaô value, emotional - motivational nature (subjectivity of perception).




# Skin location of sensory lesions




- a) **Peripheral nerve lesion** – paraesthesia (lateral femoral cutaneous n.) (**area nervina**)
- b) **Radicular lesion** – hypaesthesia (L5 radiculopathy) (**dermatome**)
- c) **Distal polyneuropathy** – paresthesia, numbness (**stocking&glove areas**)
- d) **Central lesion** – stroke med.cerebral artery (**contralateral hemisensory defect**)

**Corticospinal tracts (CSTs)** – these tracts include the descending axons of the motor neurons

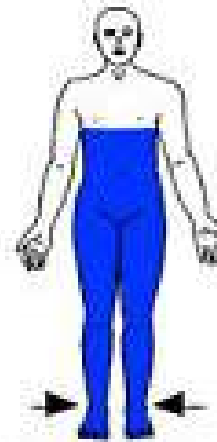
# Spinal sensory syndroms



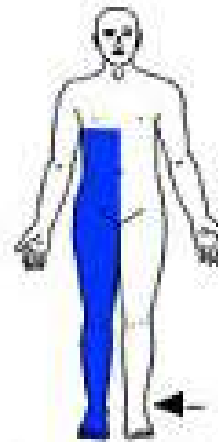
Peripheral nerve:  
carpal tunnel syndrome



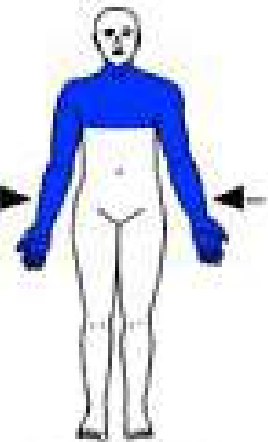
Nerve root:  
C6 radiculopathy



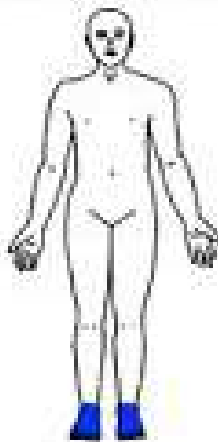
Complete spinal  
cord injury and  
anterior cord  
syndrome



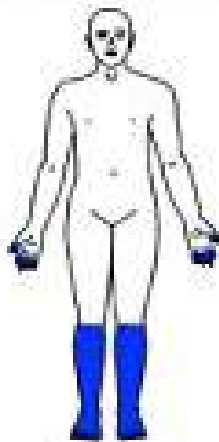
Brown-Séquard  
syndrome



Central cord  
syndrome  
(syringomyelia)



Mild

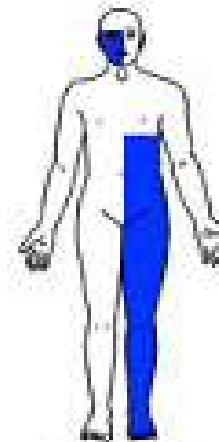


Moderate

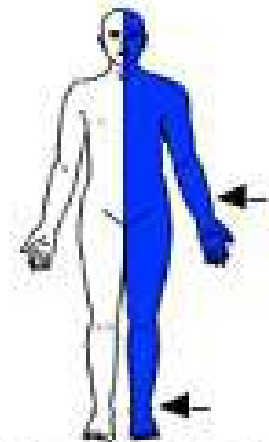


Severe

**Polyneuropathy**



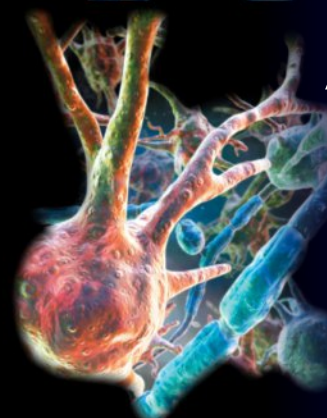
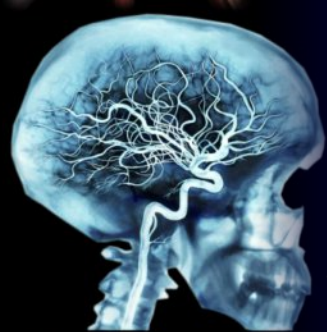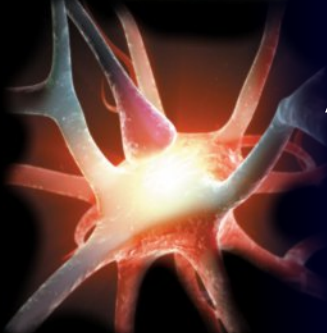
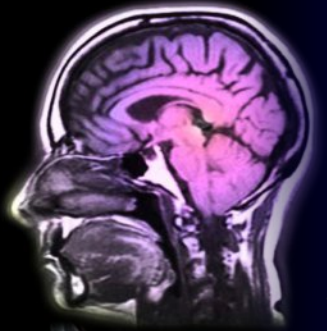
Brain stem  
injury



Thalamic or cerebral  
hemisphere injury

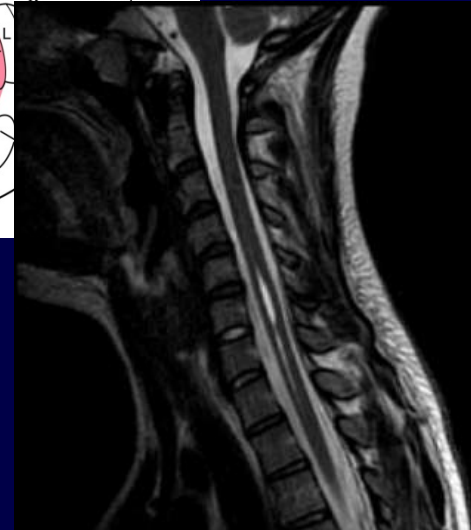
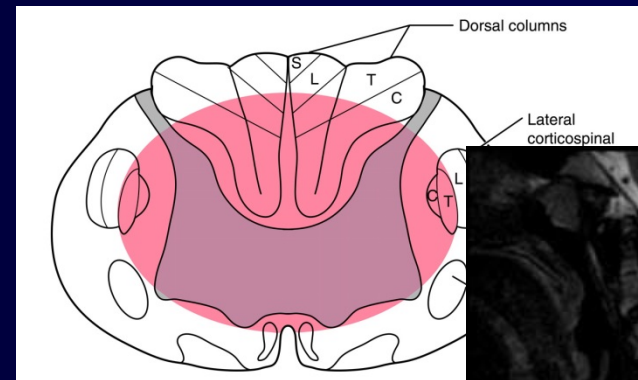
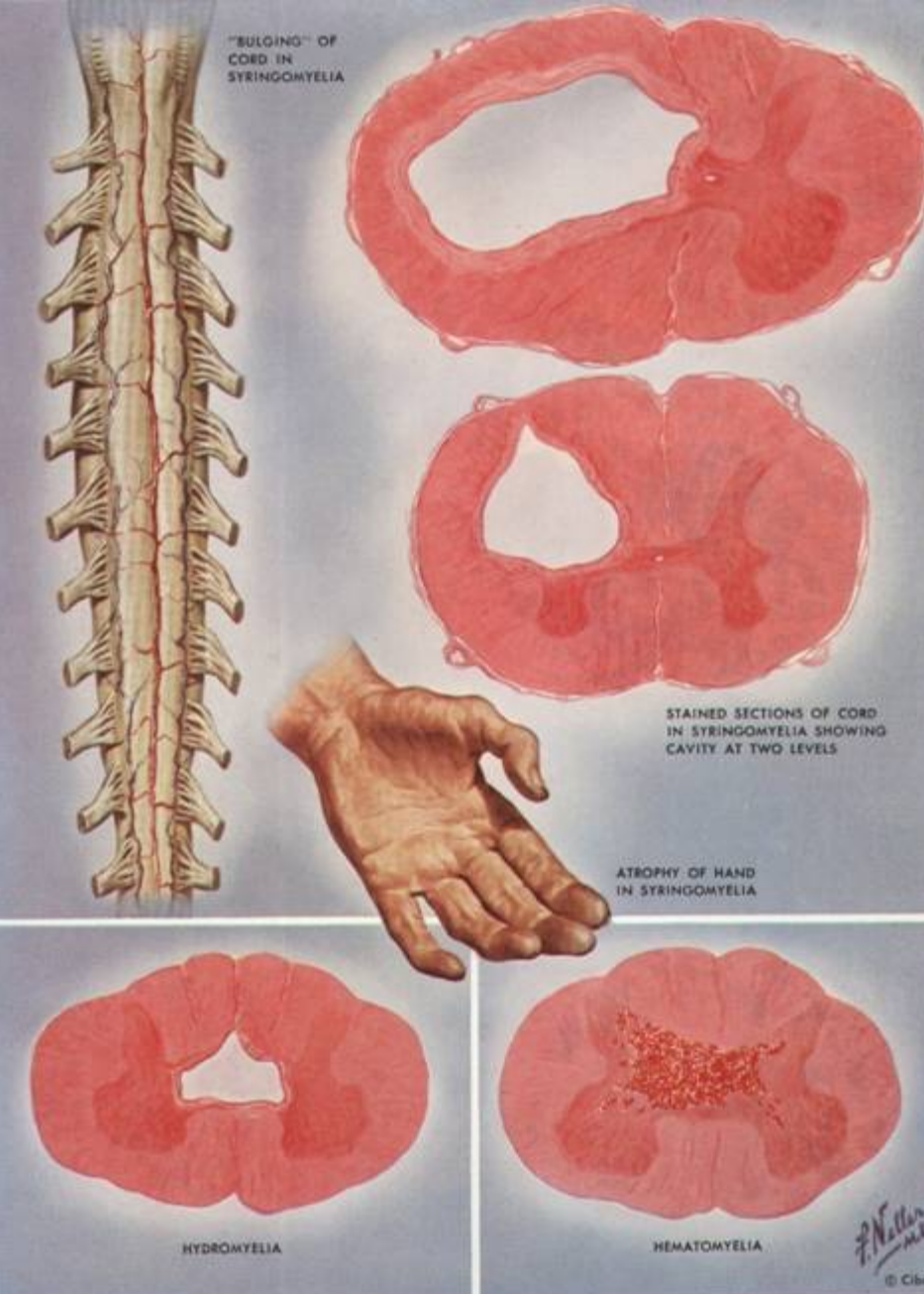
# Spinal dissociation syndromes

- **Syringomyelia-like sensory dissociation** – defect in ventral sensory tract
  - A) attenuation or loss of sensations of heat, cold, pain and pressure or coarser touch in the contralateral innervated areas of the spinal cord segment, app. 2 segments below the lesion.
  - B) Deep sensitivity (staeesthesia, pallesthesia, kinesthesia) and the so-called. epicritic (disriminative) touch sensitivity is maintained.
- **Tabes-like sensory dissociation** - dysfunction of dorsal column
  - A) attenuation or loss of deep proprio-sensitivity (stateesthesia, kinesthesia, pallesthesia, bareesthesia) and epicritic surface sensitivity (smoother tactile and thermal perception & discrimination).
  - B) The perception of pain and thickers, discriminative touch is maintained



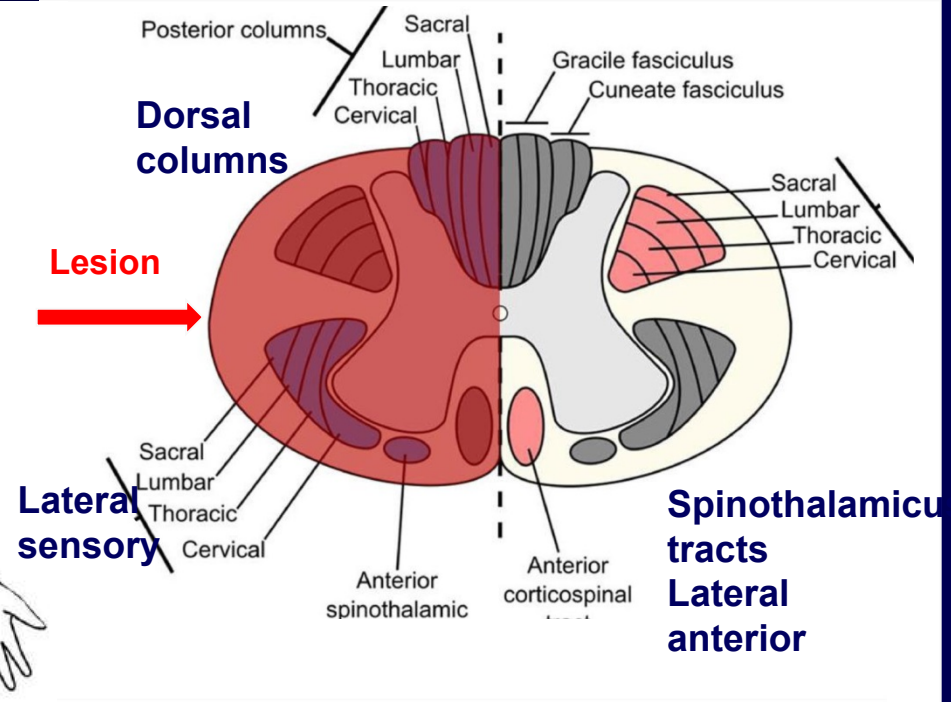
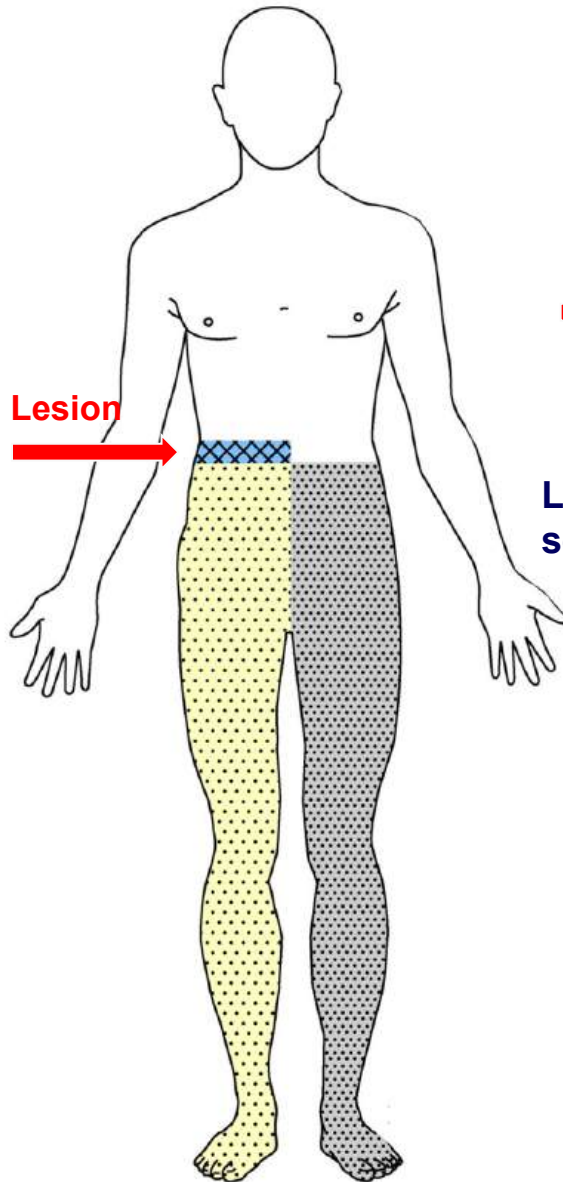
# Syringomyelia






- Spinal cord (thoracic scoliosis)
- Skull base
- Cerebellum and the brain (Chiari malformation) 90% of cases
- Lateral spinal syndrome
- Central spinal syndrome



Athrophy of hand

# Spinal hemisyndrome (Brown –Séguard sy.)



-  Ipsilateral loss of all sensory modalities at the level of the lesion
-  Ipsilateral flacid paralysis at the level of the lesion
-  Ipsilateral spastic paraparesis below the lesion
-  Ipsilateral loss of vibration and position sense below the lesion
-  Contralateral loss of pain and temperature below the lesion

# Qualitative sensory disorders

---



## Synesthesia

perception of a seminal folded for different parts of the body.

## Polyesthesia

perception of one complaint many times, i several times in a row without adequate irritability or in different, often quite distant parts of the body

## Autotopagnosia

inability to recognize the irritated spot on the body surface

## Dermoalexia

inability to reconstruct spatial maps of the body surface as seen from patients inability to read different shapes, letters drawn on the skin

## Alloesthesia

instability of the localisation of perceived stimuli ; stimulation in the same palce may be felt in different areas variably

## Dysesthesia

one modality of sensory stimuluas is misinterpreted as the perception of another modality, e.g. touch as burning, coldness and warmth as touch

## Stereoagnosia

loss of ability to recognize objects by touch with closed eyes. This disorder is manifested in two relatively independent forms

## Amorfiognosia

inability to recognize shapes of objects (eg. a cube, a sphere, a book) or matter from which the object is produced ( e.g. wood, metal, plastic, water etc) disorder of central integration of stimuli from mechanoreceptors and proprioceptors



# Qualitative sensory disorders

---

## Ahylognosia

inability to recognize the nature of the metabolism of touching objects (eg. bag with water, sand, etc.). Impaired is the central representation of incentives thermoreceptors cold, heat and surface mechanoreceptors

## Akinesthesia

inability to recognize the movement of the body and its individual segments, for example. walking, the movements of the arms and the legs.

## Stataneathesia

inability to to recognize the static position of the body or its parts, for example. headstand

## Apalesthesia

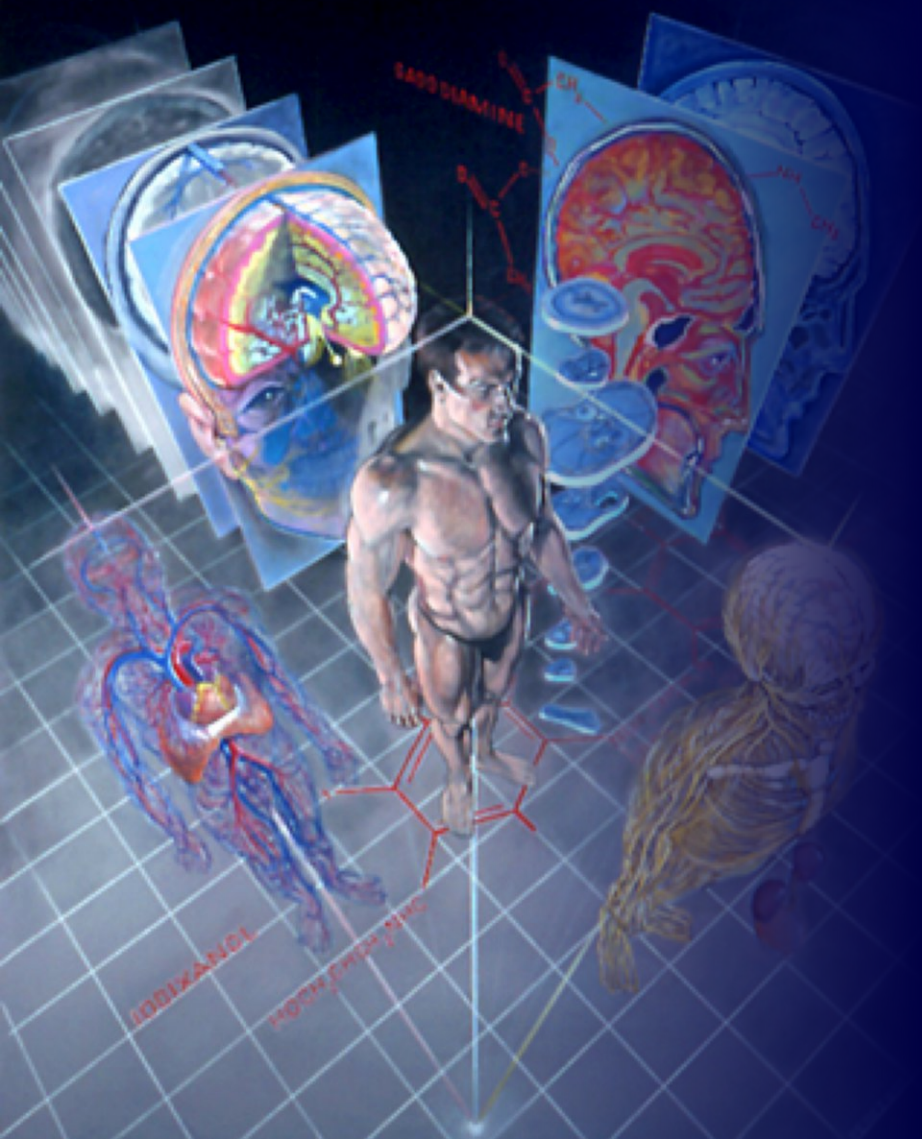
inability to perceive vibration sensitivity. A fault occurs in rapidly adapting vibrational mechanoreceptors in tissue around muscles and joints

## Abaresthesia

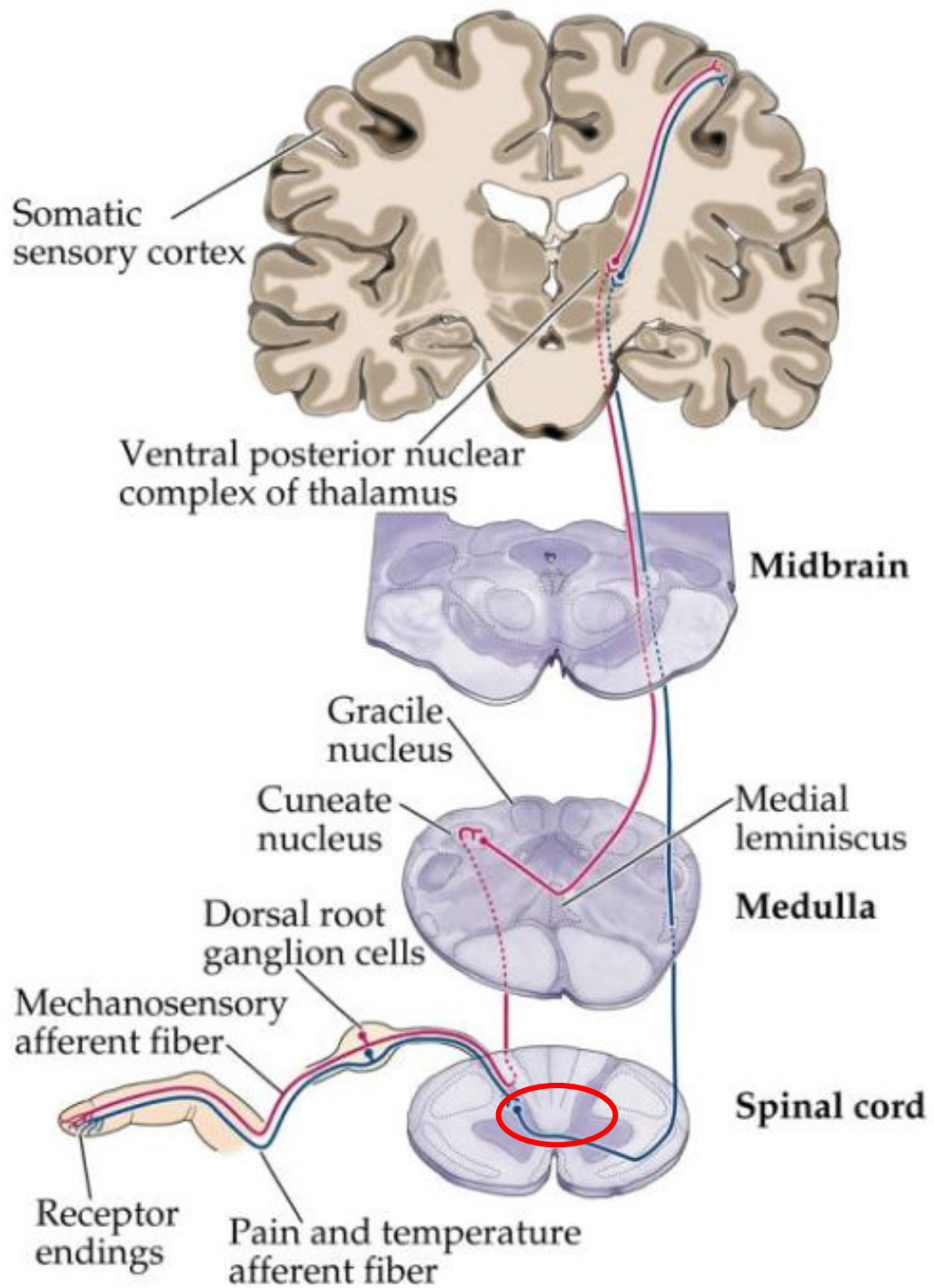
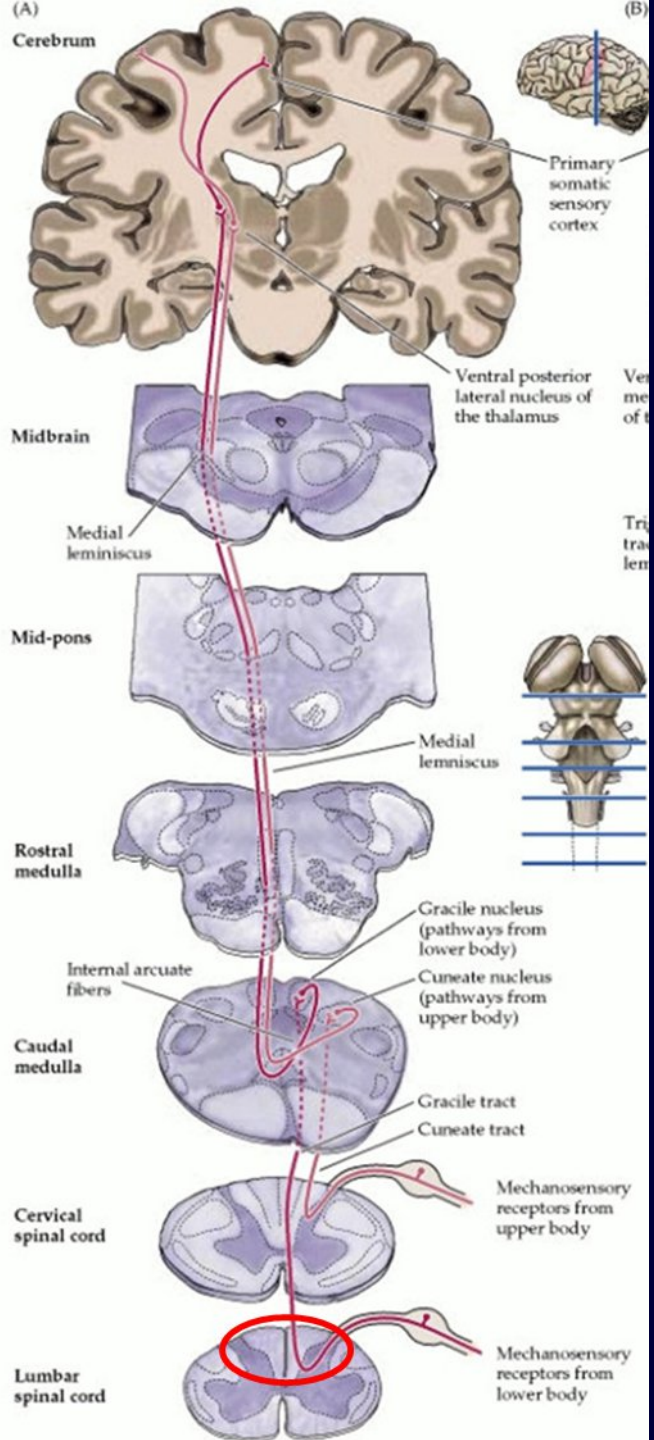
inability to perceive dull, deep-acting pressure. A fault occurs in deep subdermal slowly adapting low-threshold mechanoreceptors

## Acoenesthesia

inability to perceive their own body and its parts. Integrative disorder arises baroreception, thermoreception, surface and deep tactile mechanoreception, proprioception

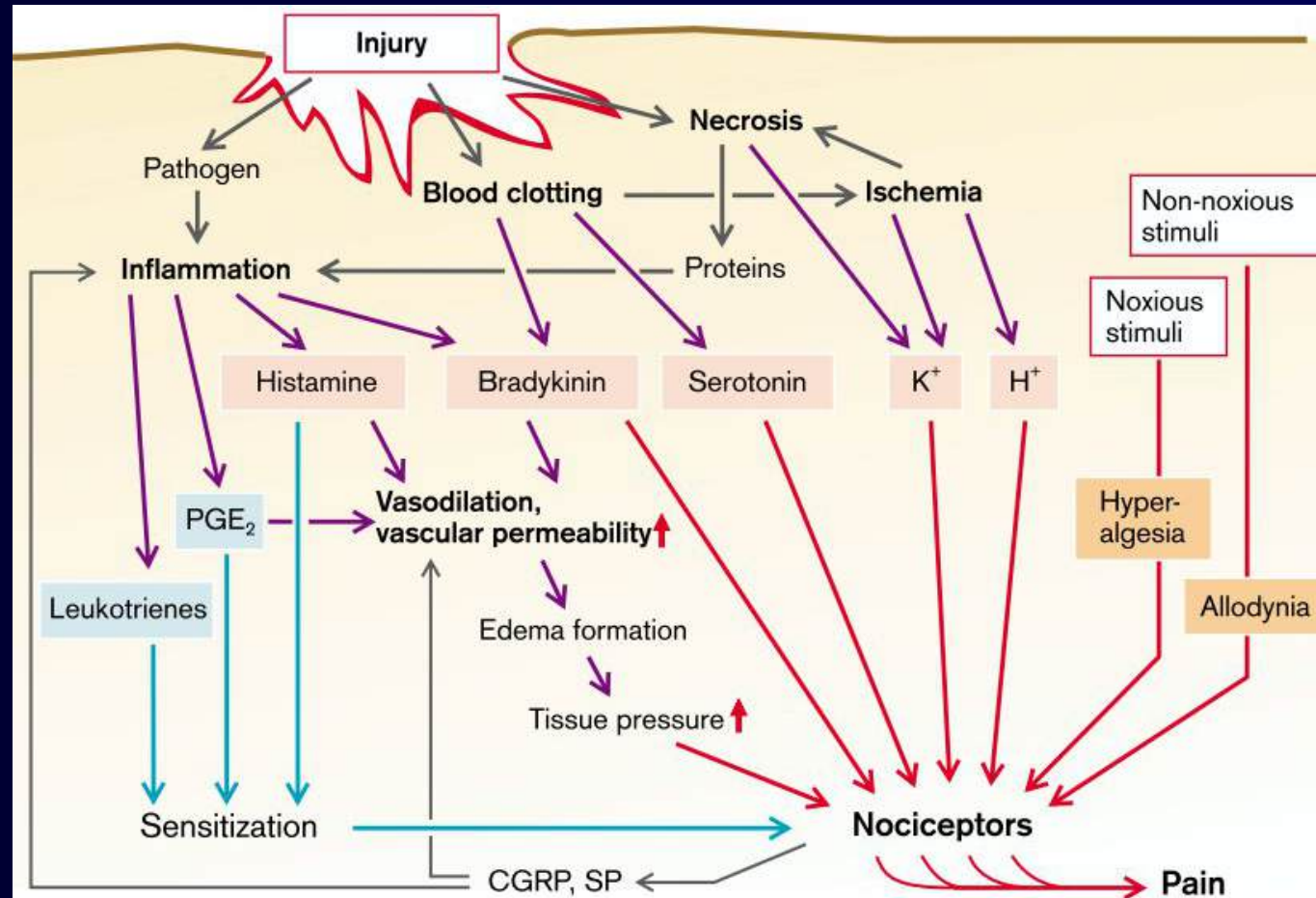


**PAIN**



# Neural components of pain

- Necrotic cells (K<sup>+</sup> leak, acidic content)
- Histiocytes
- PGE<sub>2</sub>
- Histamine
- Leukotrienes
- Trombocytes
- Serotonin
- Endothelium
- H<sup>+</sup>, K<sup>+</sup>
- GABA
- opiates
- bradykinin,
- capsaicin

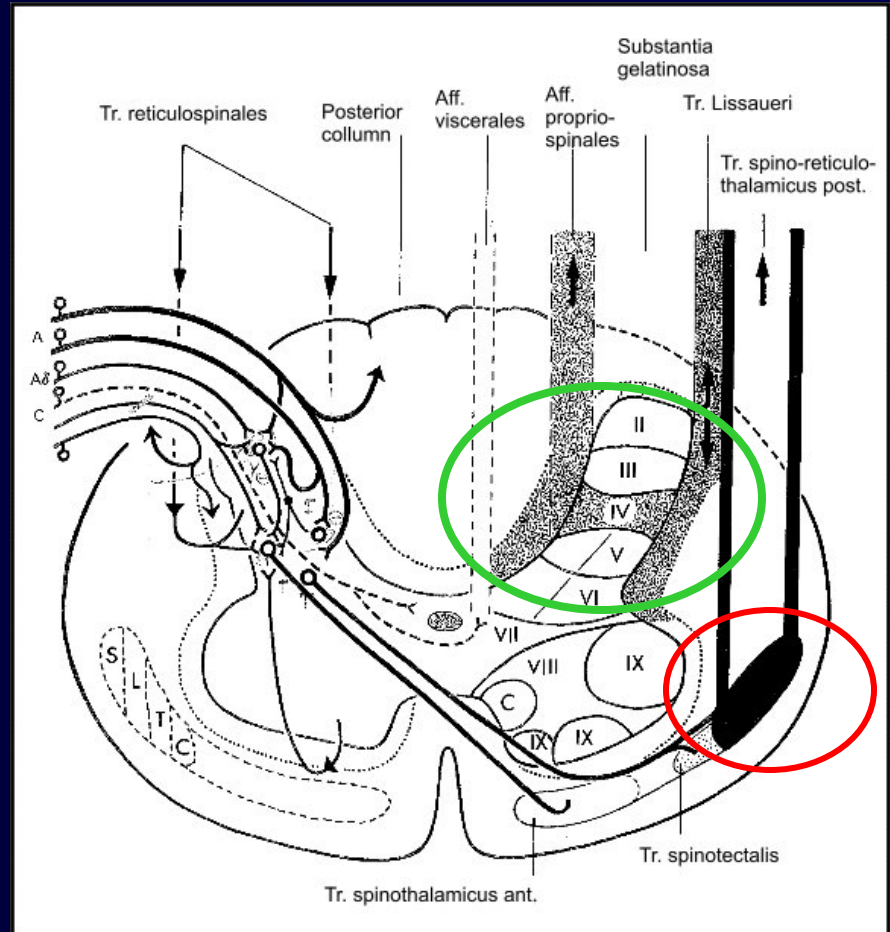


**Inflammatory locus**

# Neural components of pain 1

## Spinal cord

- Interneurons of posterior horns
- Pathways – ascendent:
  - neospinothalamic
  - spino-reticulo-thalamic (paleospinothalamic)
  - dorsal pathways
  - Lissauer tracts - spinoreticular – limbic system



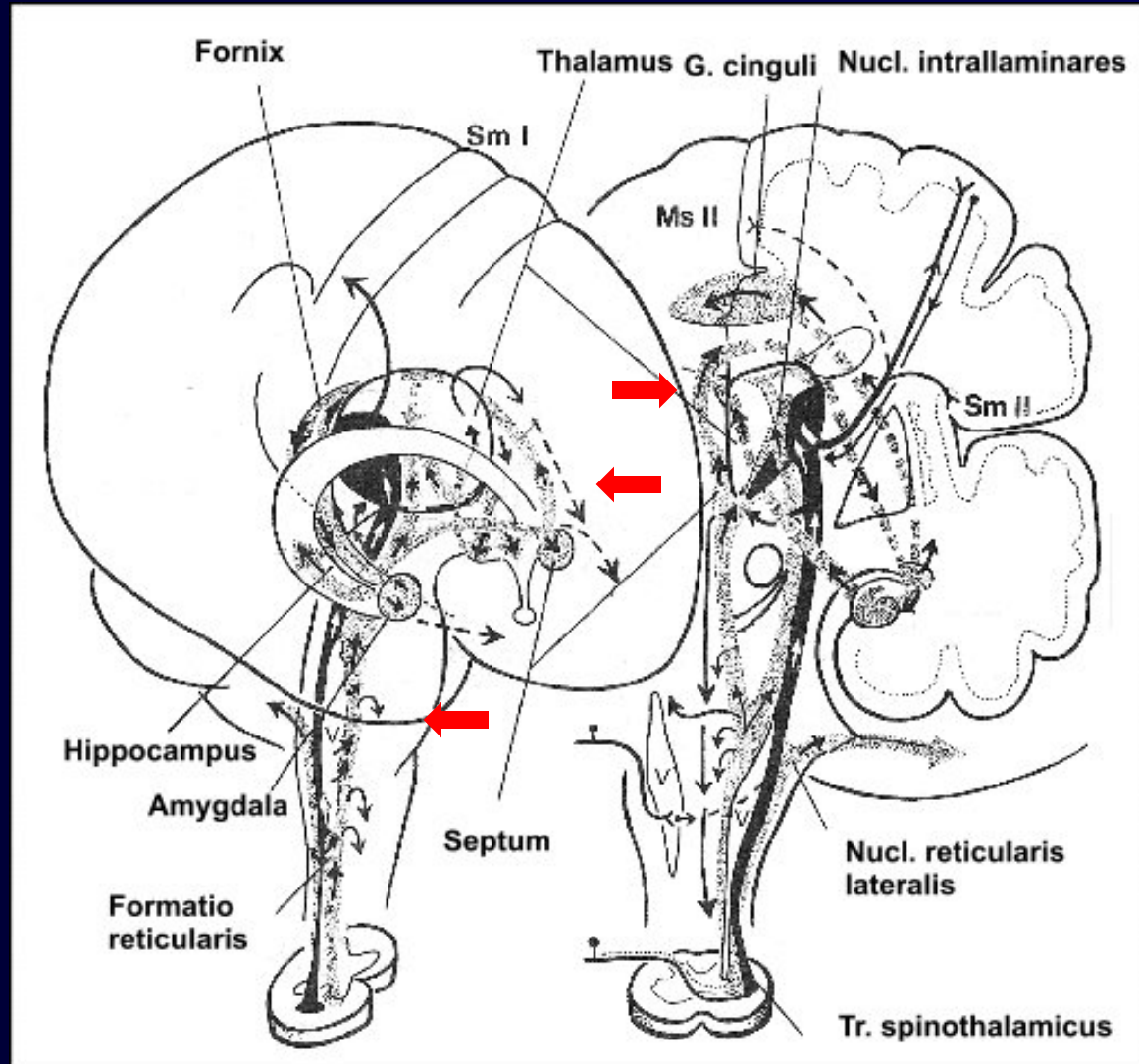
# Pathways in pain processing

## (1) Primary pain (pain)

- Oligosynaptic, younger
- Contralateral, fast, sharp, early transient, precisely localized
- Tr. spinothalamicus, Tr. spinotectalis, Tr. spinoreticularis

## (2) Secondary pain (ache)

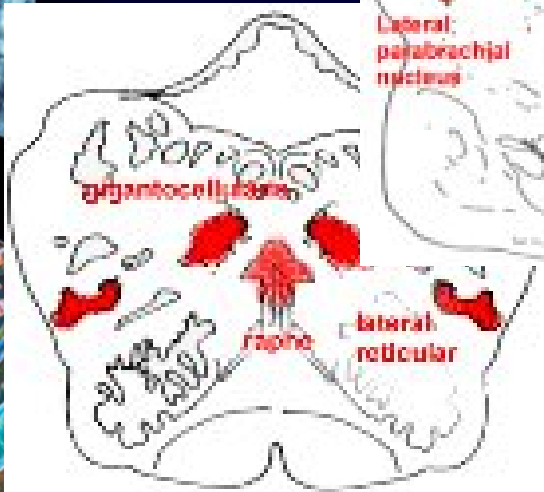
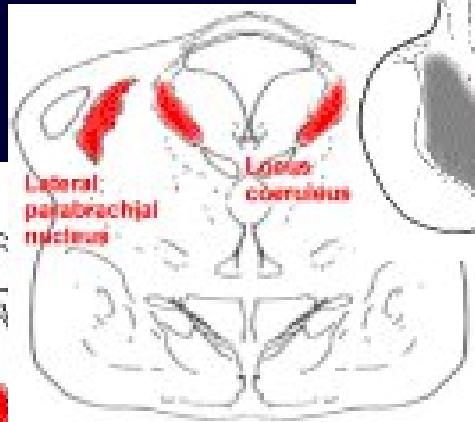
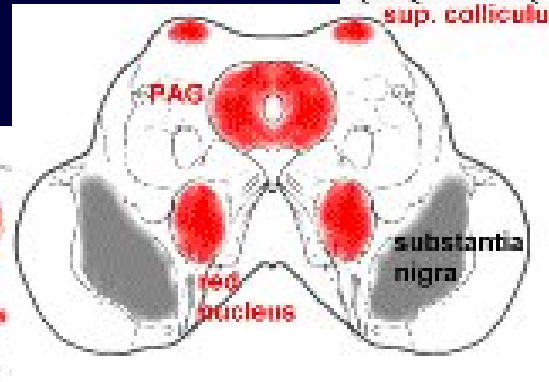
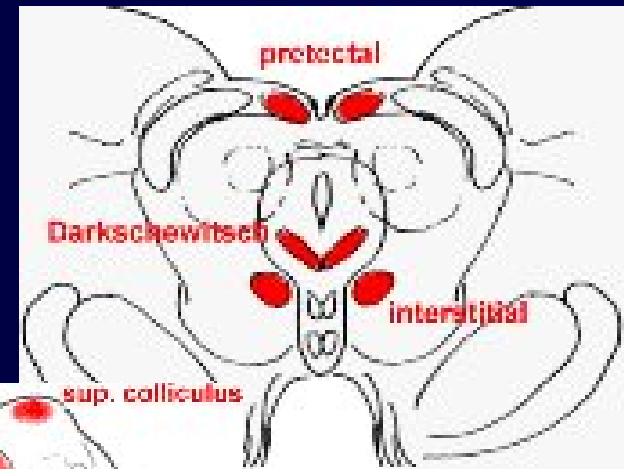- Polysynaptic, old, archaic
- Homolateral, slower
- Burning, dull, late-onset prolonged, Weakly localized
- Tr. spinoreticularis, Tr. reticulo-hypothalamicus  
① Amygdala, fornix (limbic system)



# Neural components of pain 2

## Brainstem

- Nucl. gigantocellularis
- Nucl. reticularis lat.
- Nucl. raphe (magnus),
- Locus coeruleus
- Periaqueductal gray (PAG)
- nucl. ruber
- Pretectal nuclei

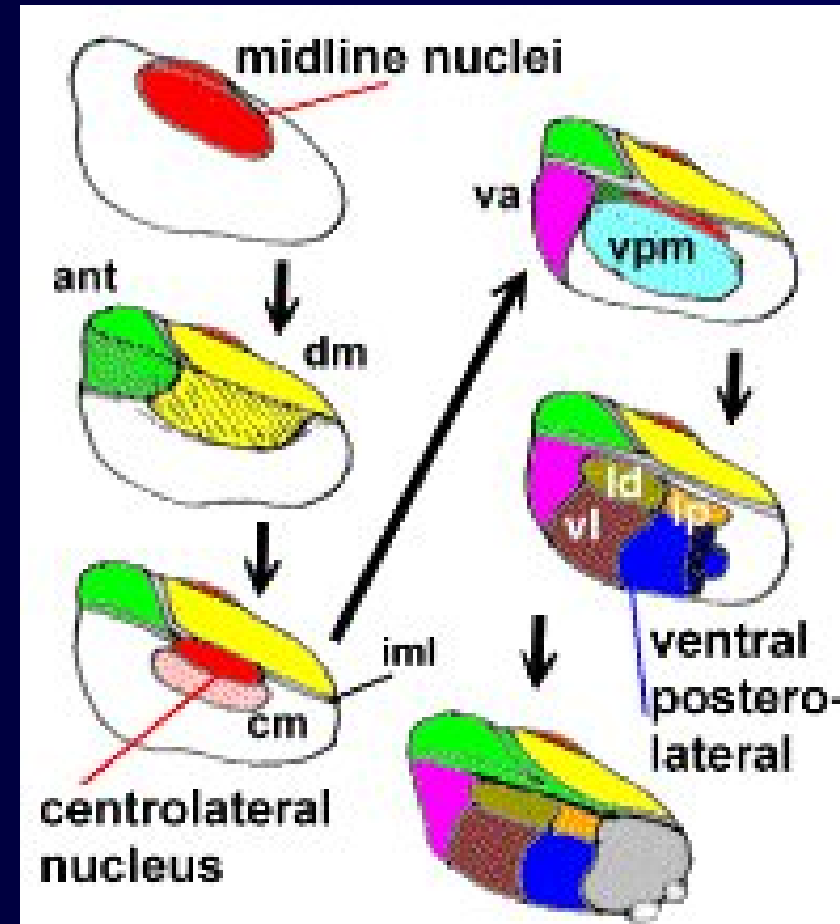
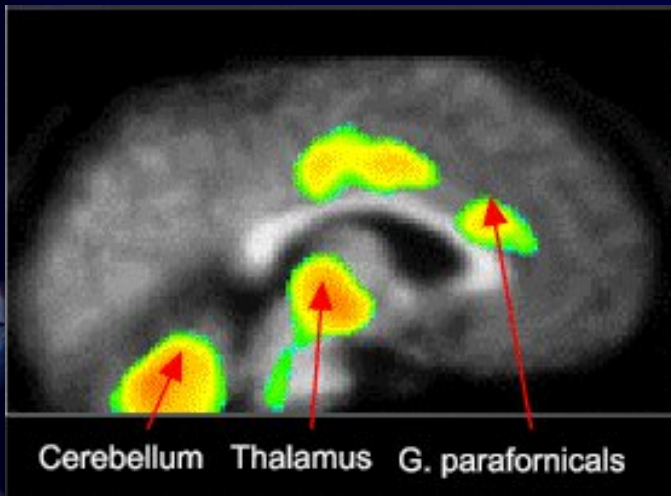


Pain –related structures as revealed by functional NMR imaging

# Neural components of pain 3

## Subcortical structures

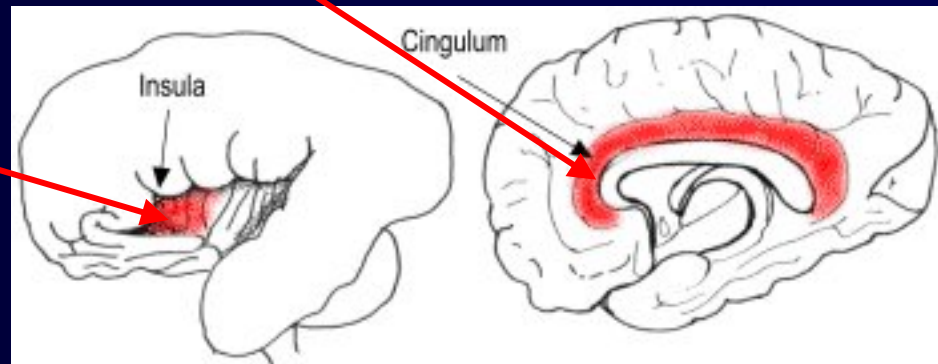
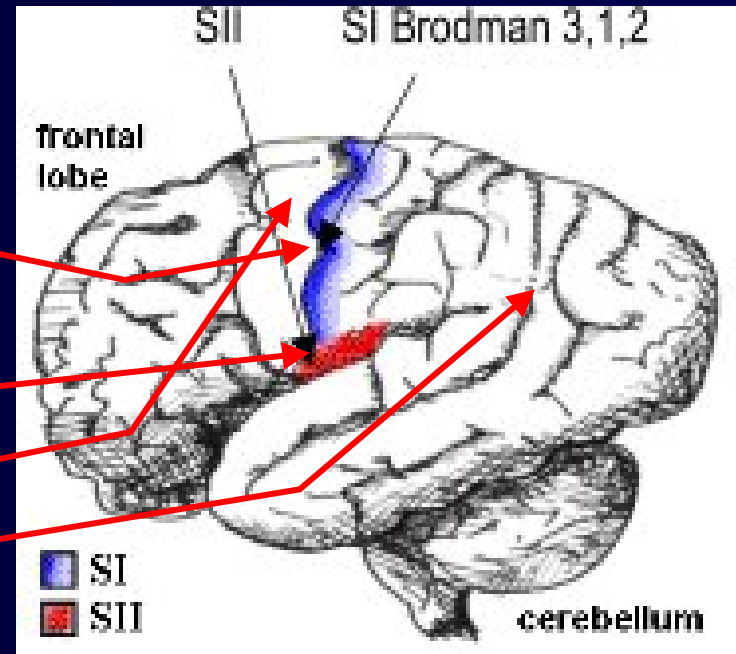
- Thalamus, pulvinar
- Vermis cerebelli
- Basal ganglia - putamen, nucl. caudatus
- Hypothalamus – basal portion
- Limbic system - amygdala, hippocampus



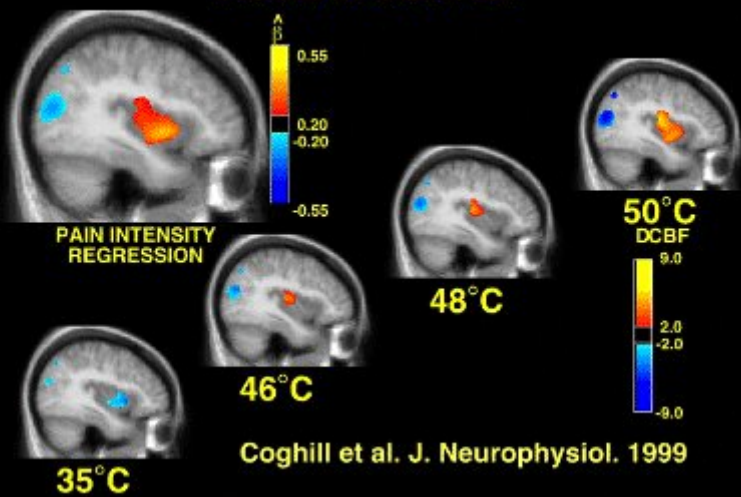
# Neural components of pain 4

## Cortex

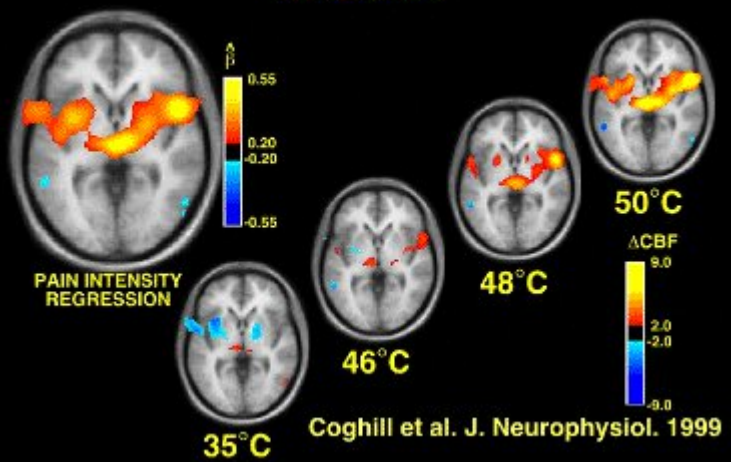
- Primary sensory cortex SI (3,1,2) ( localized pain)
- Secondary sensory cortexsenzorická SII (dull ache)
- Premotor (6),
- Parietal cortex ( 7, 37-40)
- Cingular cortex (24, 32)
- Anterior insula (14) (affective pain)



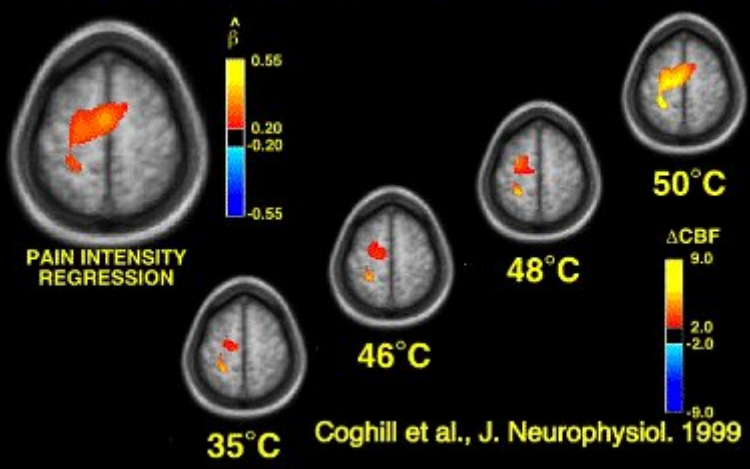
### INSULAR CORTEX



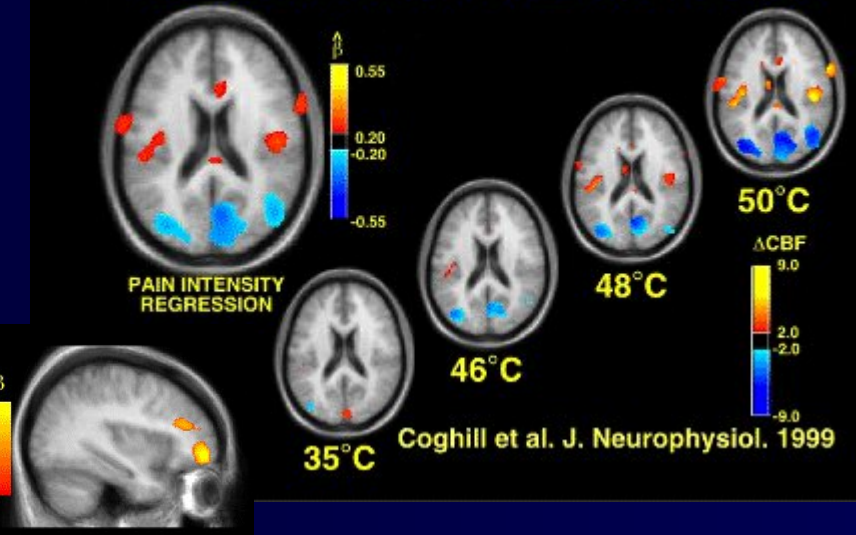
### THALAMUS



### PRIMARY SOMATOSENSORY CORTEX

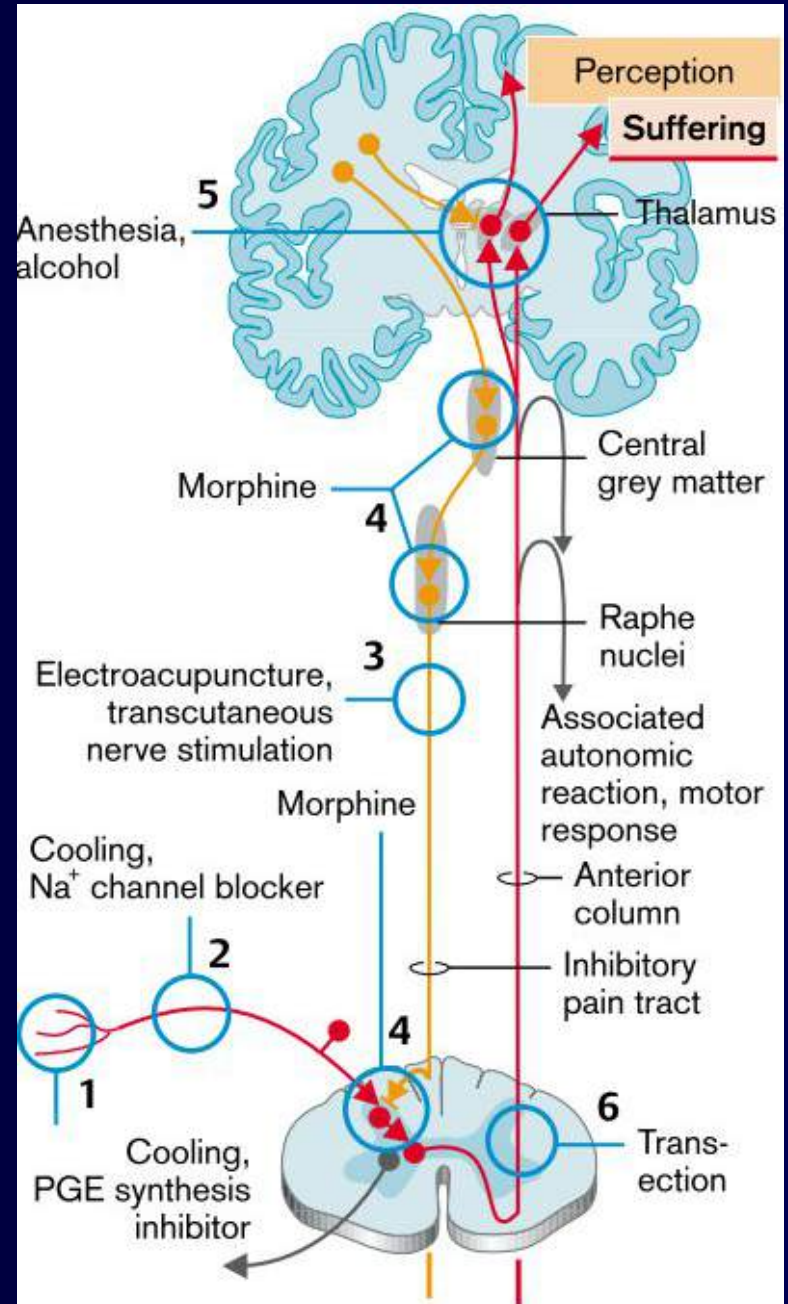
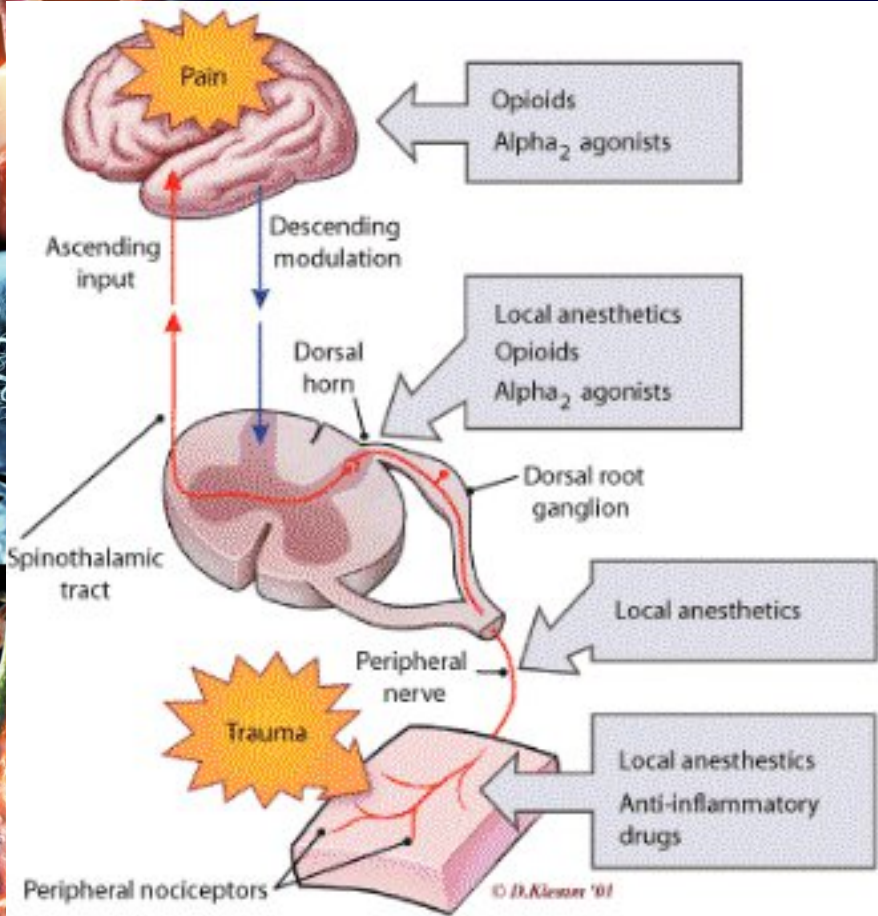


### SECONDARY SOMATOSENSORY CORTEX

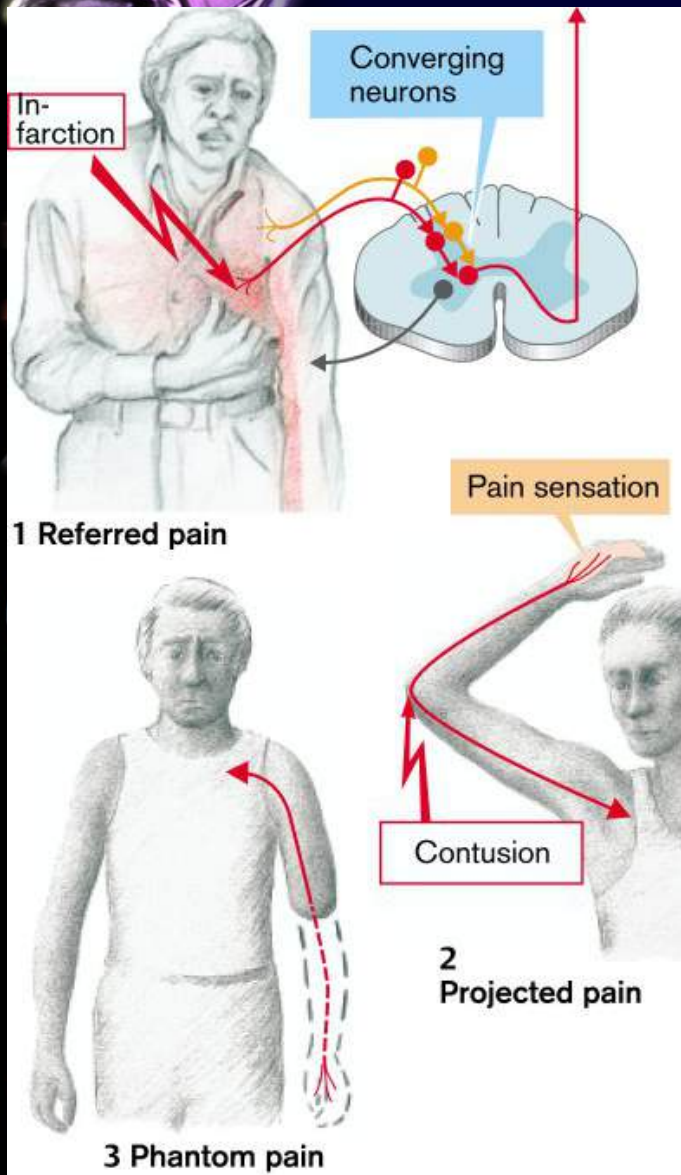




# Action of analgesics



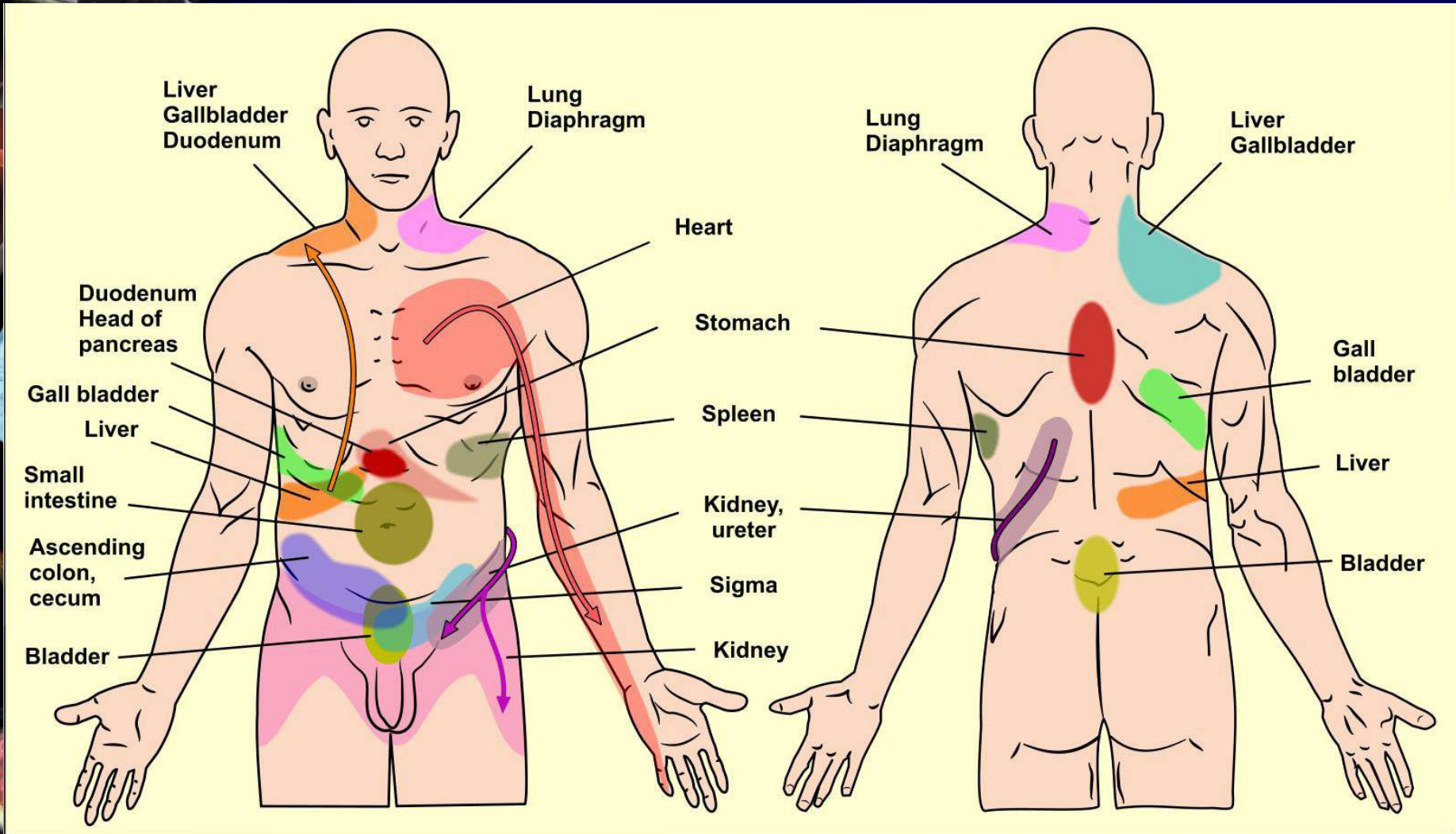
# Special forms of pain



- **Causalgia** - comprehensive irritable syndrome manifested **harsh tingling** - occur weeks and months after **stab wounds, contusion nerve, muscle, bone fracture or amputation**.
  - irritation of the fibers in the peripheral nerve surrounding scar, bone callus formation or faulty synapses between pain sympathetic afferent and efferent fibers
- **Neuralgia** - intractable **prolonged stabbing seizure-like stacks of pain** accompanied by vegetative signs
  - Causes: **ischemia, infection, metabolic and so on.**) trigeminal neuralgia
- **Phantom pain** - the perception of pain in the body part, most often the limb that has been lost. Although the peripheral part is missing, central somesthetic structures for a particular locus persist and receive excitation from neighboring areas

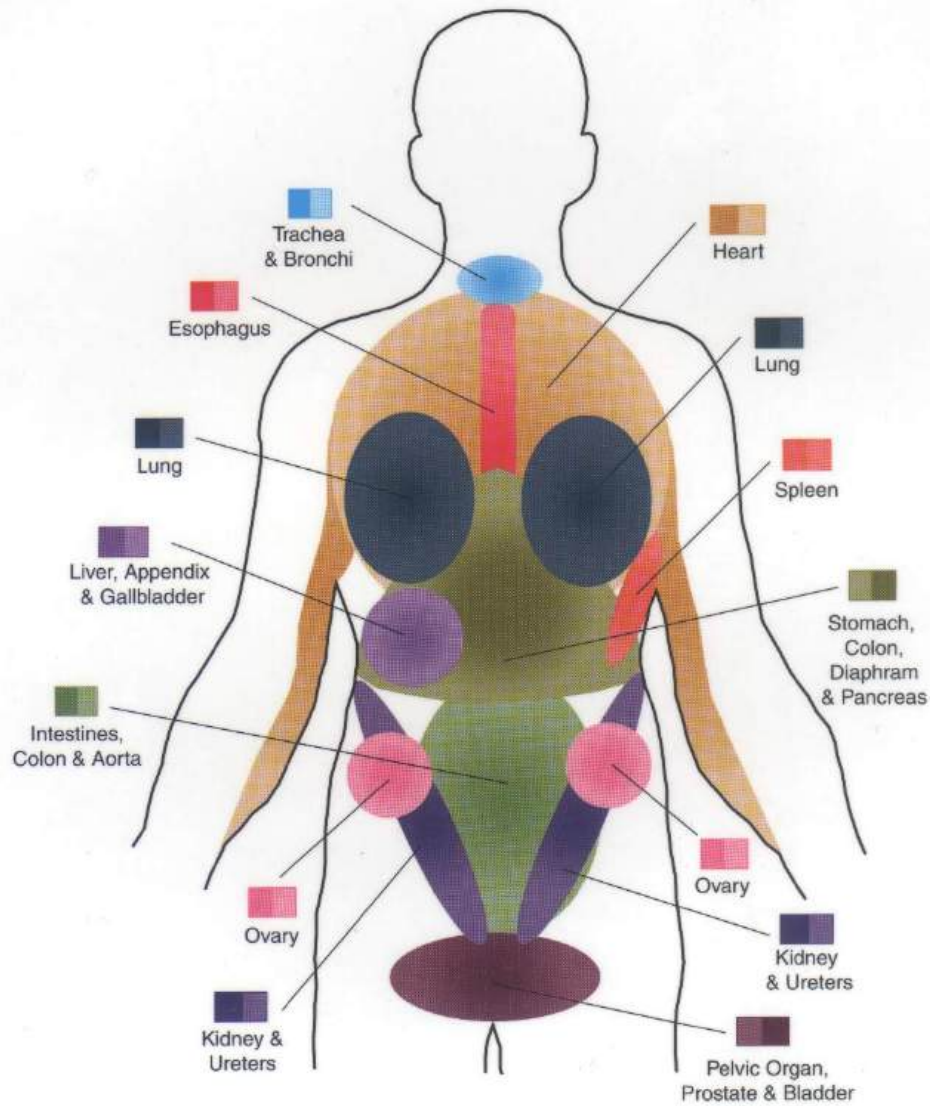
# Referred pain

- pain from inner organs is perceived on the surface of the body



# Visceral-Somatic Pain

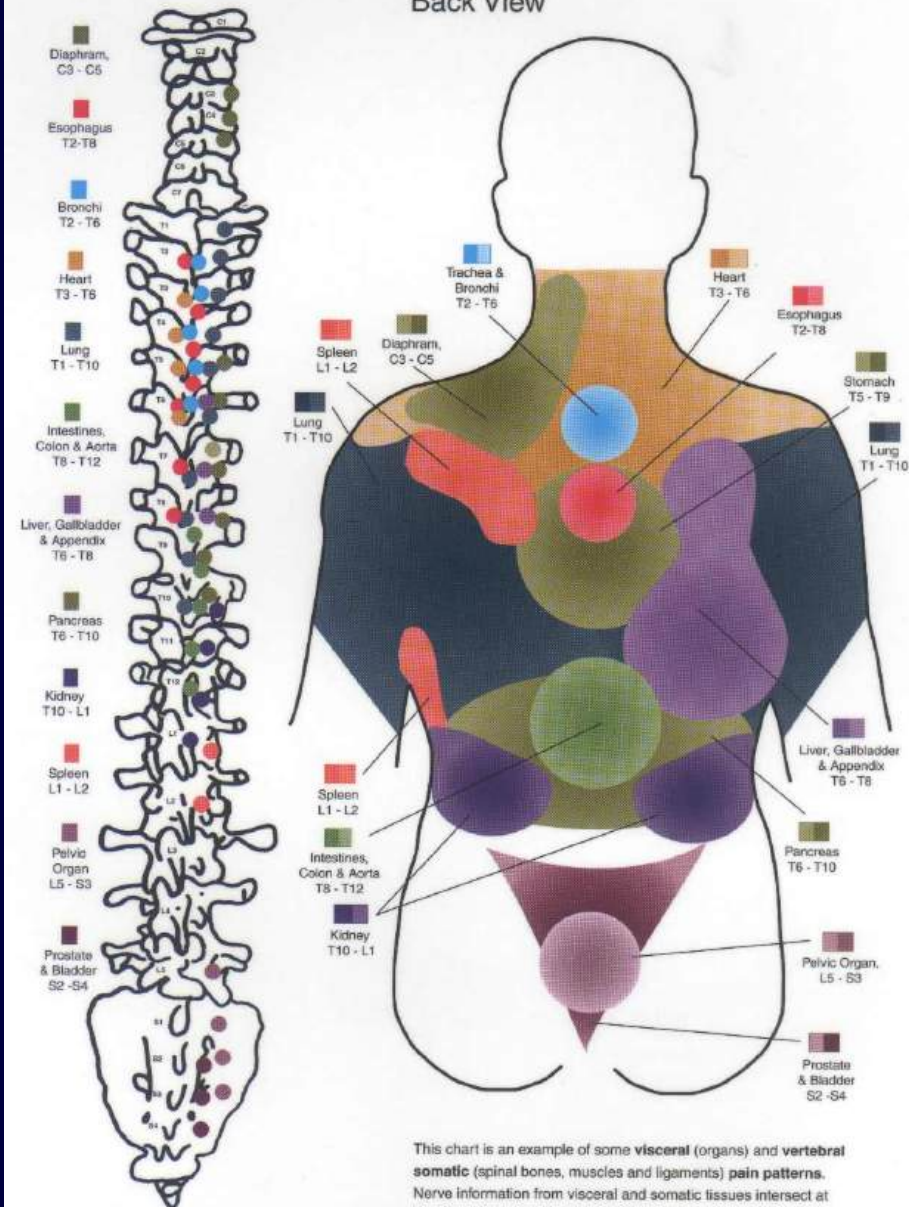
Front View



This chart is an example of some **visceral** (organs) and **vertebral somatic** (spinal bones, muscles and ligaments) **pain patterns**. Nerve information from visceral and somatic tissues intersect at the same locations. If an organ is diseased or a spinal structure dysfunctions, both can produce similar symptoms (colored areas) in the body, i.e. muscle spasm, pain, nausea, and sweating. An accurate diagnosis will differentiate between the two.

# Visceral-Somatic Pain

Back View

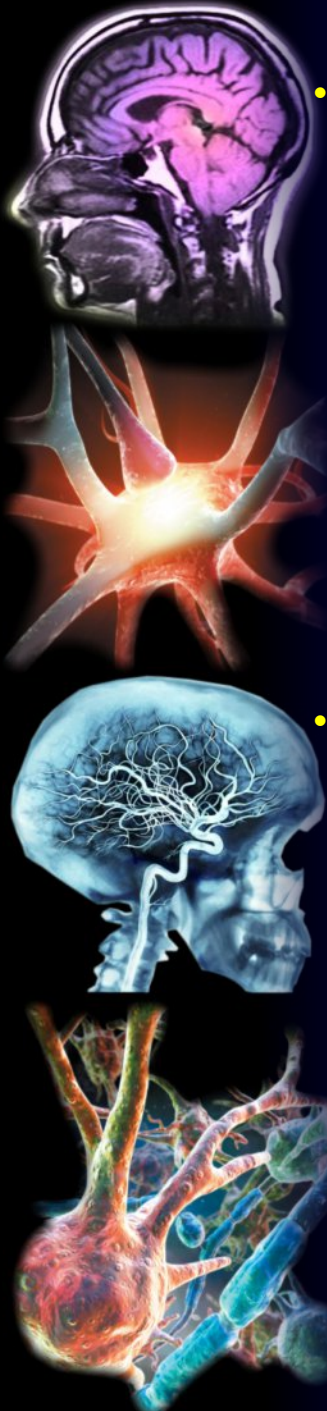

The colored dots on the spine indicate the vertebral segmental and neurological relationship of each organ. The vertebrae may be tender to the touch when irritated by organ disease, or spinal dysfunction.

This chart is an example of some **visceral** (organs) and **vertebral somatic** (spinal bones, muscles and ligaments) **pain patterns**. Nerve information from visceral and somatic tissues intersect at the same locations. If an organ is diseased or a spinal structure dysfunctions, both can produce similar symptoms (colored areas) in the body, i.e. muscle spasm, pain, nausea, and sweating. An accurate diagnosis will differentiate between the two.

- **Sclerotome** = topographic region of tissue (mostly) or organs ( mostly mesenchymal) innervated by afferents from 1 segment of spinal cord

- **Myotome** = virtual tomomorphic area of muscles supplying afferents into 1 segment of spinal cord



## Sclerotome Pain Referral Patterns

Sclerotogenous pain is reported by patients as deep, ill defined, dull aching, and diffuse. Sclerotogenous pain does not follow dermatome but does follow a sclerotome pain pattern. The tissues that are included in sclerotogenous pain include: Ligaments, Tendons, Discs, Facet Joints and Apophyseal Joints.

A sclerotome is a deep somatic tract that is innervated by the same spinal nerve and when the tissue of a sclerotome is irritated by mechanical or chemical stimuli pain is "experienced" as originating from all of the tissues that are innervated by the same nerve, or along the sclerotome.

Sclerotomal patterns are bilateral. Dark areas represent deep pain. Light areas are diffuse pain.

### Facet Joint (Zygapophysial) Pain Referral Patterns

Labels: C2, C3, C4, C5, C6, C7, T1, T2, T3, T4, T5, T6, T7, T8, T9, T10, T11, T12, L1, L2, L3, L4, L5, S1, S2.

The lumbar facet and sacrum can refer to lateral & posterior thigh and to groin.

### Vertebral Ligaments

Copyright 2010 www.AcupunctureProducts.com