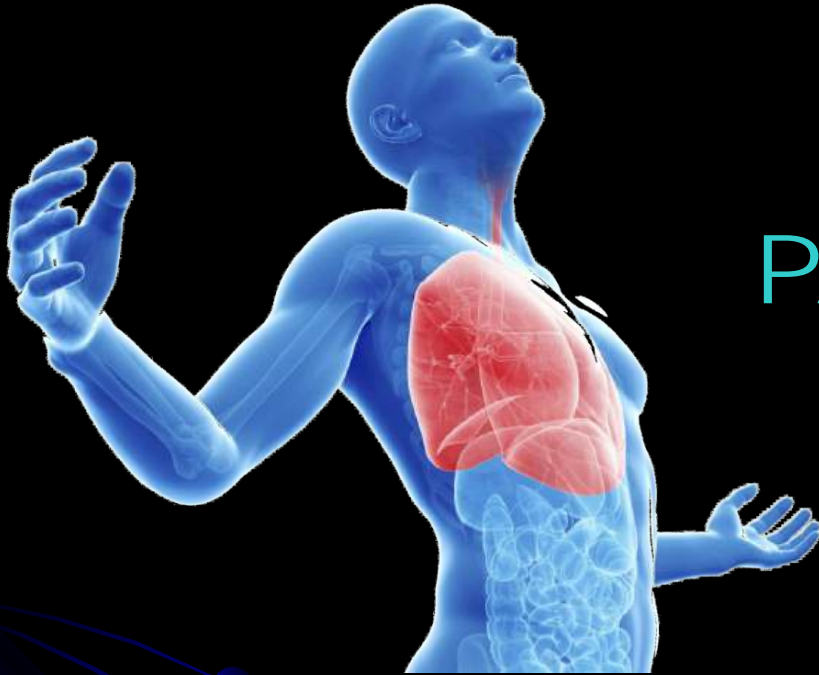

Lectures from Pathophysiology
General medicine
Dentistry
1996-2000, 2001-2023



PATHOPHYSIOLOGY OF RESPIRATION

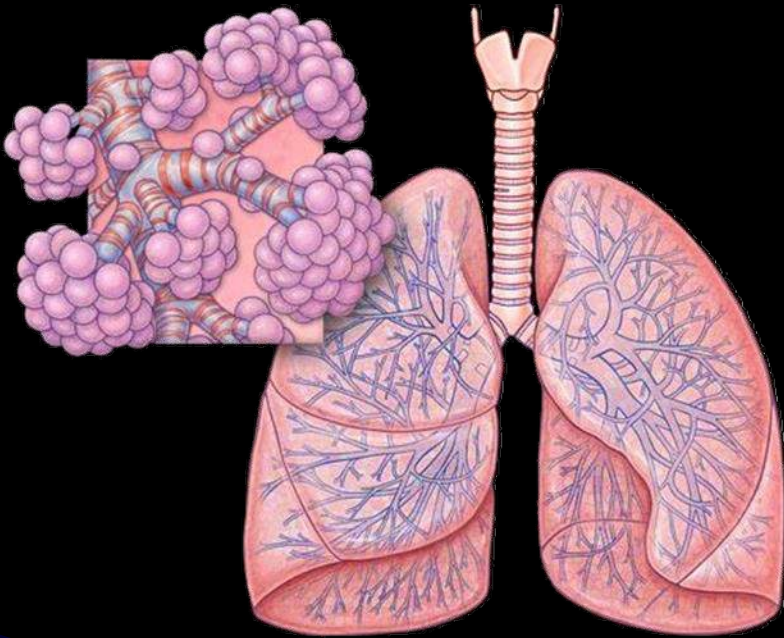
2

Respiratory Disorders

R.Benacka, MD, PhD

Department of Pathophysiology,
Medical faculty, P.J. Safarik University
Košice

1



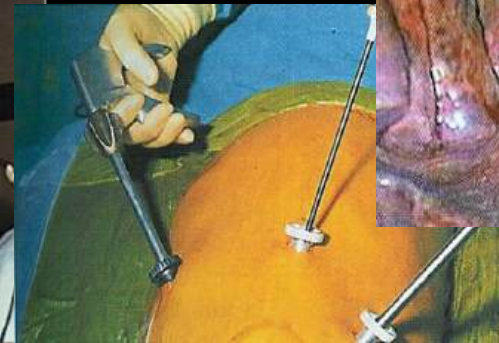
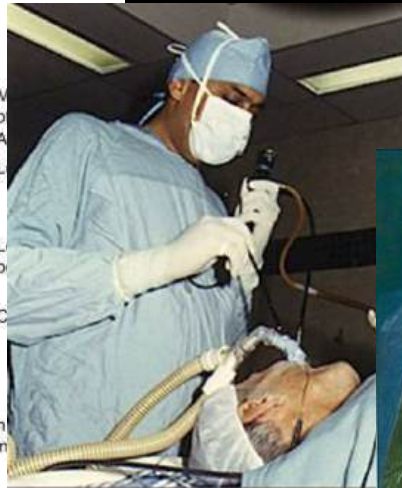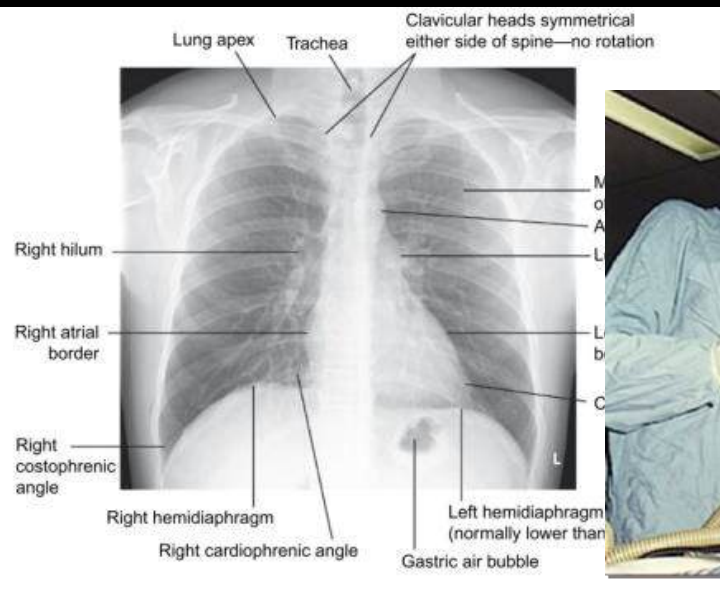
Pre-clinical overview

Diagnostic methods

- **Functional lung evaluation** - static (basic lung volumes), dynamic (lung volumes, flows, forced expiration curve, flow-volume curve, maximal voluntary ventilation)
- **Radiodiagnostics** – gas diffusion, lung circulation
- **RTG** – emphysema (overdistention, flattened diaphragm), bronchitis, pneumonia, lung edema, tumours (solid masses) etc.

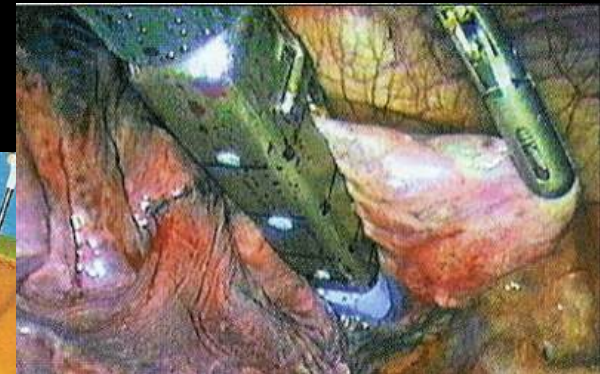
- **Acid-base ballance** – in arterial blood
- **Sputum** – neutrophiles, macrophages, T-lymphocytes, epithelial cells
- **Blood** – secondary polycytemia in progressive COPD, leukocytosis etc.
- **ECG** – right heart failure, ventricular hypertrophy, Cor pulmonare etc.

X ray scans



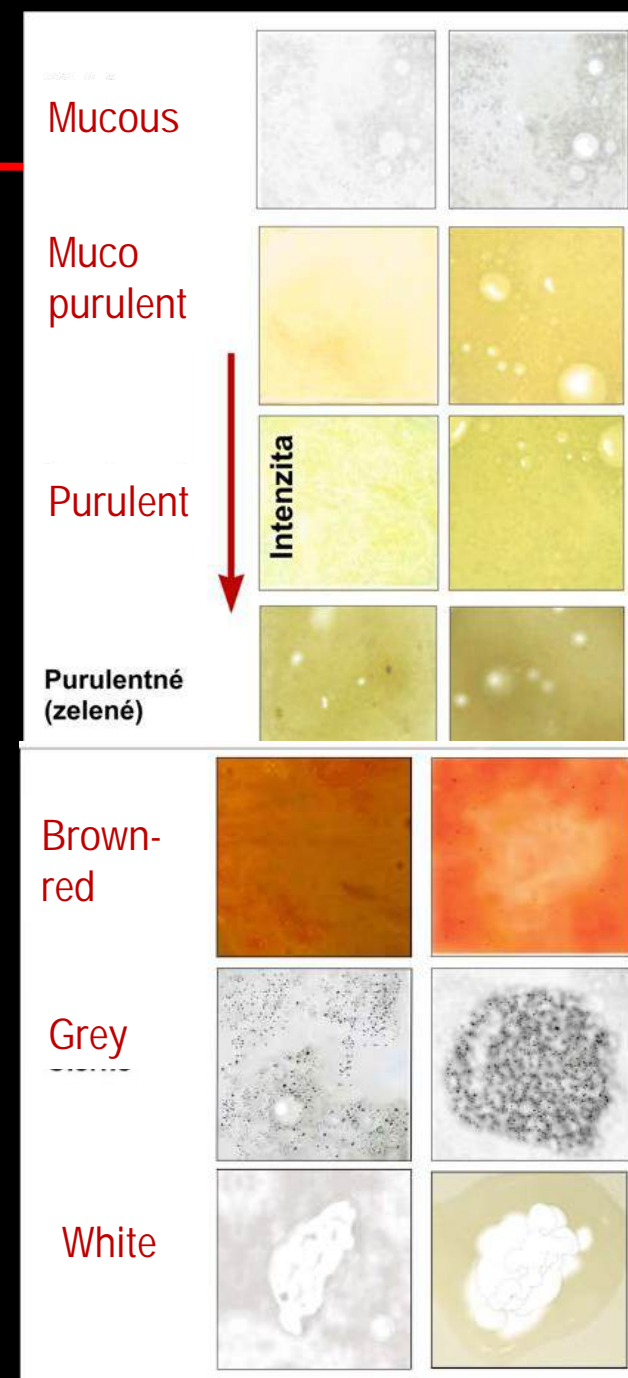
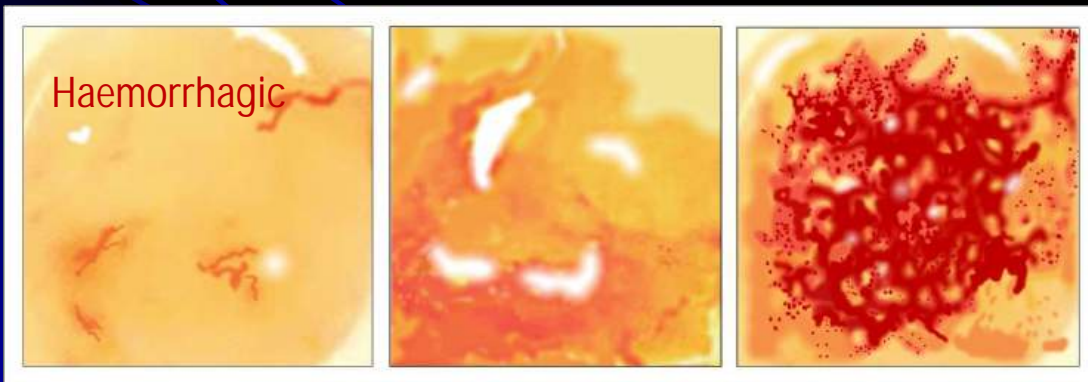
Mediastinoscopy

Thoracoscopic methods



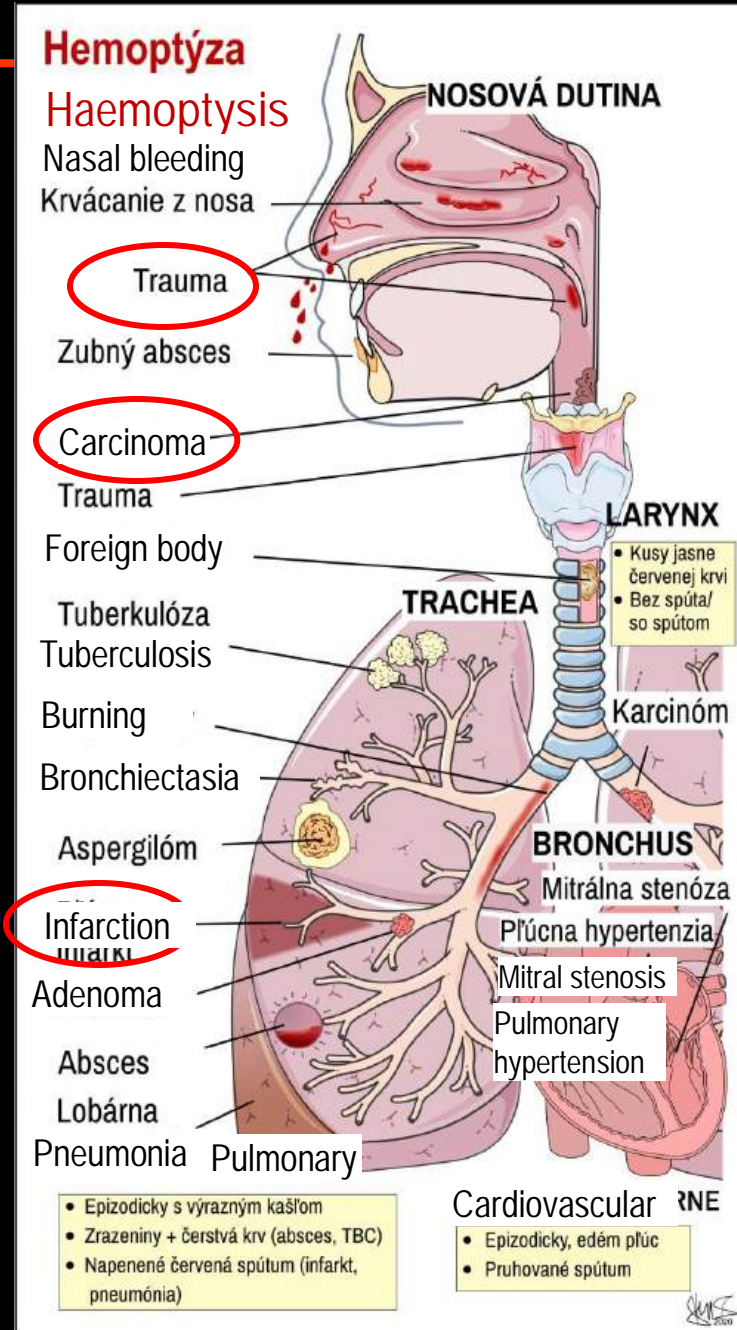
Diagnostic methods

- **Sputum analysis:** Gram's staining, especially the CB type. Macrophages, neutrophils, T lymphocytes, and epithelial cells are seen in greater numbers in patients experiencing an exacerbation of the disease than they are in patients whose condition remains stable.
- **CBC - eosinophilia** → asthmatic bronchitis; advanced CB or emphysema → **secondary polycythemia**. COPD exacerbations → **leukocytosis` left shift** → superimposed acute bronchitis or pneumonia.



Expectoration of blood

1. **Bronchogenic Carcinoma (Lung Cancer):** in older patients or those with a significant smoking history.
2. **Infectious Causes** the most frequent triggers globally.
 - **Acute/Chronic Bronchitis:** The #1 cause of mild hemoptysis; small superficial vessel rupture
 - **Tuberculosis (TB):** Historically the leading cause; it often causes "cavitary" lesions in the upper lobes that erode into blood vessels.
 - **Pneumonia:** Bacterial pneumonia can cause "rusty" or blood-streaked sputum.
 - **Lung Abscess:** A localized collection of pus that can erode into a nearby vessel.
 - **Aspergilloma (Fungus Ball):** A clump of fungus that grows in a pre-existing lung cavity (like one left by TB). It is notorious for causing massive hemoptysis.
2. **Cardiovascular Causes**
 - **Pulmonary Embolism (PE):** "pulmonary infarction"
 - **Mitral Stenosis:** back-pressure into the pulmonary veins, Left Heart Failure: pink, frothy sputum



Expectoration of blood

3. Autoimmune & Inflammatory (Diffuse Alveolar Hemorrhage)

- Goodpasture Syndrome: an attack on both the lungs and kidneys.
- Granulomatosis with Polyangiitis (GPA): formerly Wegener's) small blood vessels.
- Systemic Lupus Erythematosus (SLE)

4. Miscellaneous Causes

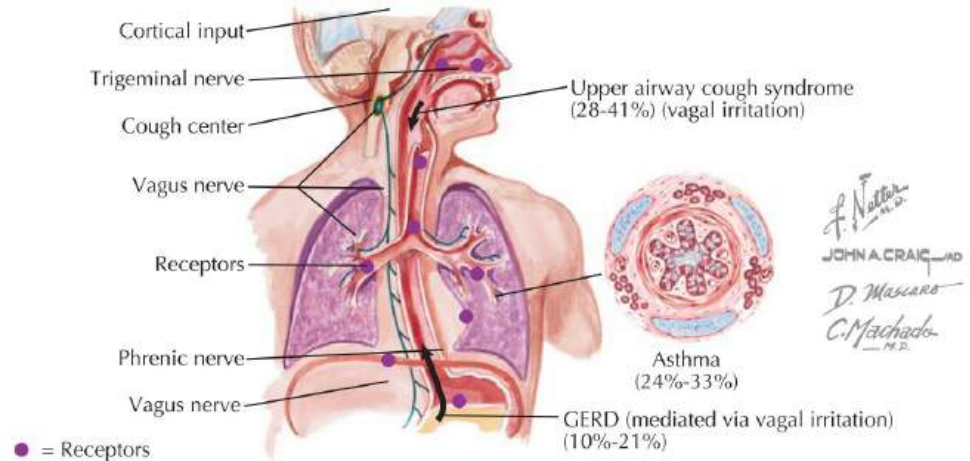
- Trauma: Rib fractures, gunshot wounds, aggressive medical procedures (like a lung biopsy)
- Foreign Body: Inhaling an object (common in children) can traumatize the airway.
- Cocaine Use: Specifically "crack" lung, which causes direct alveolar damage.
- Anticoagulation: Being on blood thinners (like Warfarin or Apixaban) doesn't cause the bleed, but it makes any minor irritation bleed much more profusely.

Feature	Hemoptysis (Lungs)	Hematemesis (Stomach)
Color	Bright red	Dark red / "Coffee grounds"
Consistency	Frothy (contains air bubbles)	Not frothy; may contain food
pH	Alkaline	Acidic
Associated Symptoms	Cough, dyspnea	Nausea, vomiting, melena (black stool)

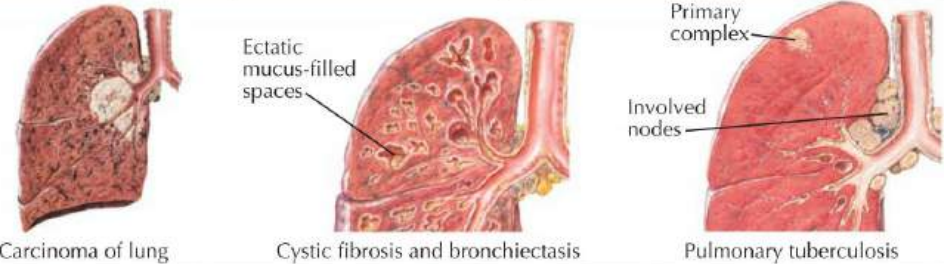
Cough

- **Protective reflex:** various types; (spectral analysis of cough sound; laryngeal tracheal;
- Vagal. aff., NLR, NLS; RARs (larynx, trachea)
- **Forms:** produktive (COPD); dry, irritative, (asthma, bronchitis); Cough hypersensitive syndrome
- **Causes:**
 - Upper airway syndromes (28-41%) e.g. rhinitis, sinusitis, nasal dipping, laryngitis
 - Non-pulmonary, e.g. fracture of ribcage, GERD (10-21%)
 - Lower airway syndromes (24-33%) e.g. acute chronic bronchitis, carcinoma, cystic fibrosis, tuberculosis, lung edema, bronchiectasia
- **Complications:**
 - urinary incontinence, syncopal states, intracranial haemorrhage,
 - ribcage fracture

Neuroanatomy of the cough reflex and common causes of chronic cough



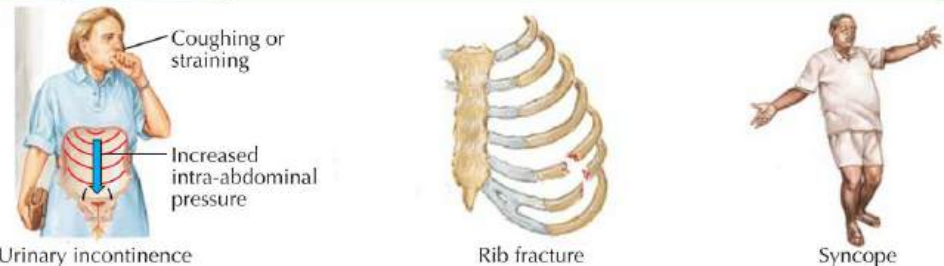
Causes of chronic cough with abnormal chest radiograph



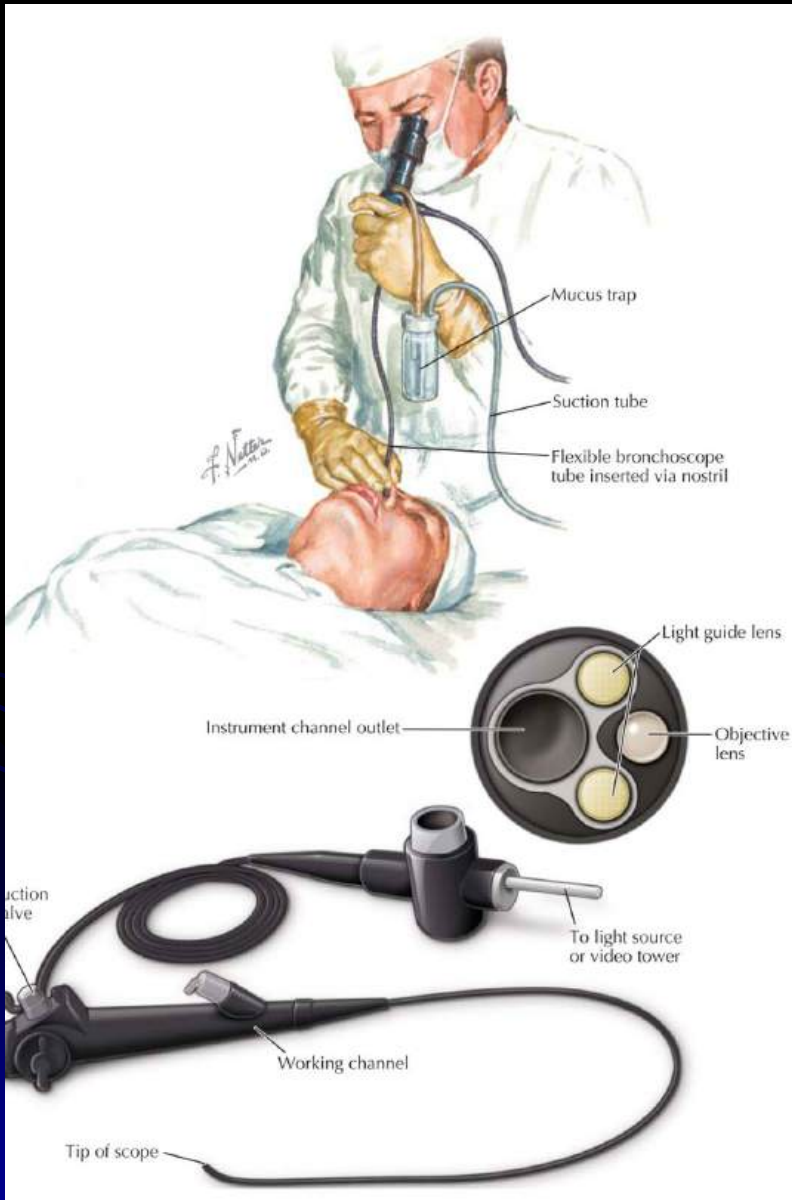Causes of acute, subacute, and chronic cough with normal chest radiograph

- | | | |
|---|--|--|
| <p>Acute</p> <ul style="list-style-type: none"> ▶ Upper respiratory tract infections URIs (e.g., the common cold) ▶ Bacterial sinusitis ▶ <i>Bordetella pertussis</i> infection ▶ Exacerbations of asthma and bronchitis ▶ Allergic rhinitis ▶ Environmental irritant rhinitis | <p>Subacute</p> <ul style="list-style-type: none"> ▶ Postinfectious cough (e.g., <i>Bordetella pertussis</i> infection) ▶ Bacterial sinusitis ▶ Exacerbation of asthma, chronic bronchitis; bronchiectasis (x-ray may be abnormal) | <p>Chronic</p> <ul style="list-style-type: none"> ▶ Upper airway cough syndrome caused by a variety of rhinosinus conditions ▶ Asthma ▶ Nonasthmatic eosinophilic bronchitis ▶ GERD ▶ Chronic bronchitis ▶ Bronchiectasis (x-ray may be abnormal) |
|---|--|--|

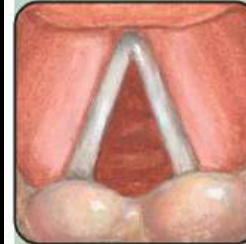Complications of cough



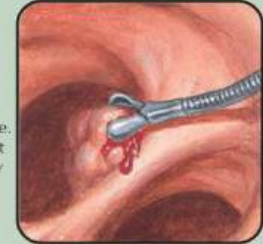
Bronchial endoscopy



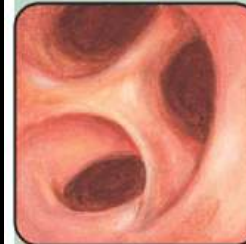Typical bronchoscopic views



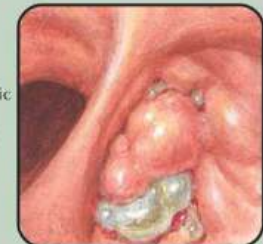Vocal cords visualized during passage of bronchoscope. Anesthetic injected at this point to facilitate passage through glottis



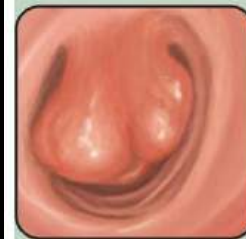Tumor of superior segment of left lower lobe. Forceps about to take biopsy



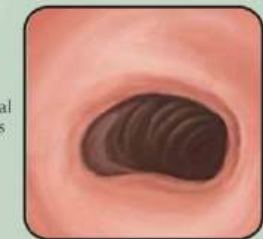Normal right upper lobe bronchus with openings of apical, posterior, and anterior segmental bronchi



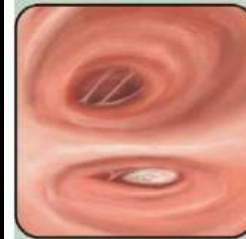
Bronchogenic carcinoma obstructing bronchus



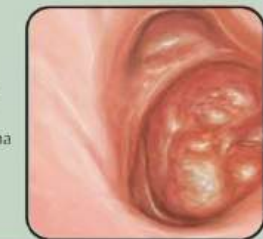Carcinoid tumor



Tracheal stenosis



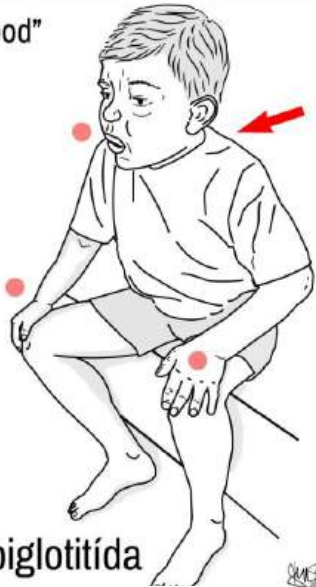Broncholith



Adenoid cystic carcinoma

Dyspnoea

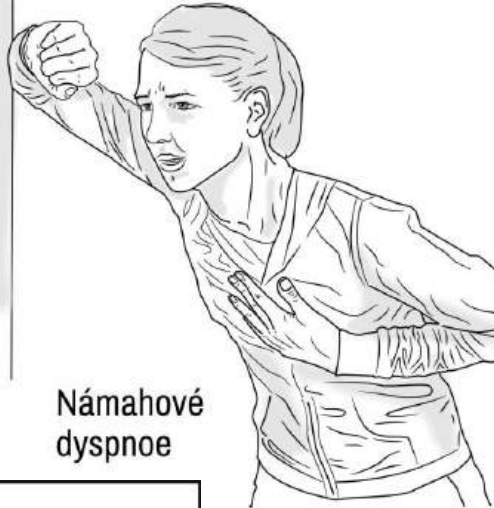
"Tripod"



Epiglottitída

Epiglossitis

Exertional
dyspnoea



Námahové
dyspnoe

Kašľové
dyspnoe



Cough
dyspnoea

Dyspnoe

Hypoxia, subj. pocit nedostatku vzduchu

Laryngospazmus -Laryngitis

Laryngotracheitída Laryngospasm

(Foreign body, food

Tuberculosis

Atelectasis

Emphysema

Cudzie teleso

Asthma
asthma

Pľúcny
Infarction

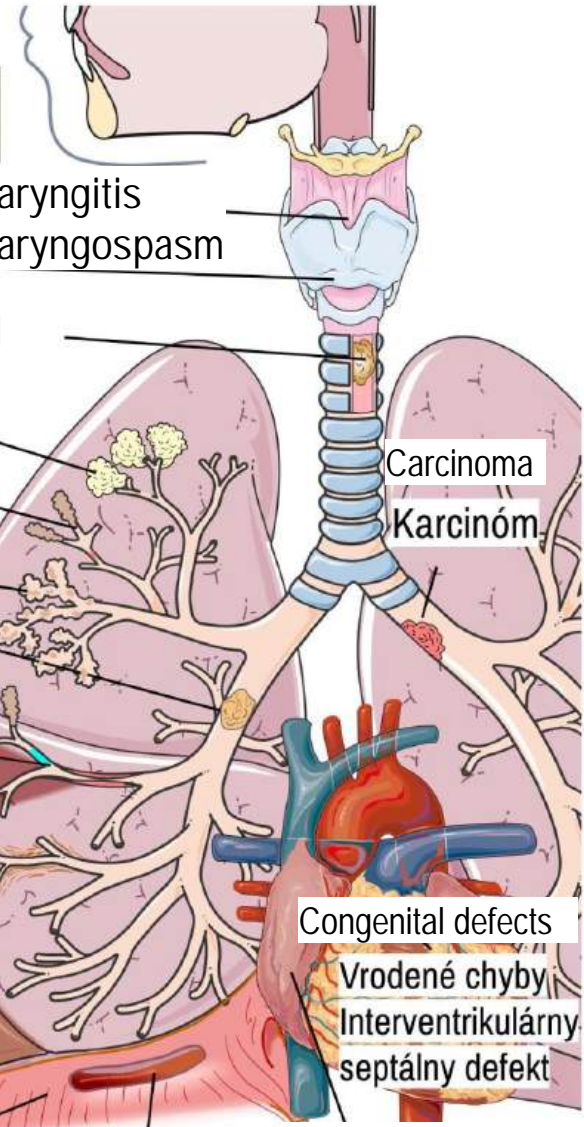
Pľúcna
Fibrosis

Pľúcna
Pneumonia

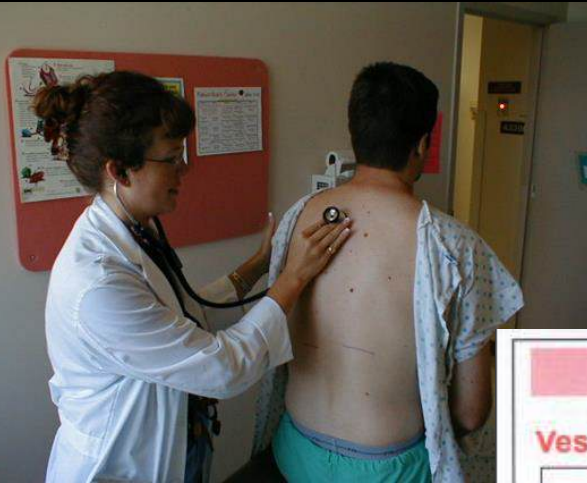Diaphragm
paralysis










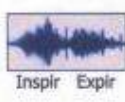


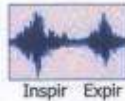

Abscess / absces

Congestive
heart failure



Respiratory sounds



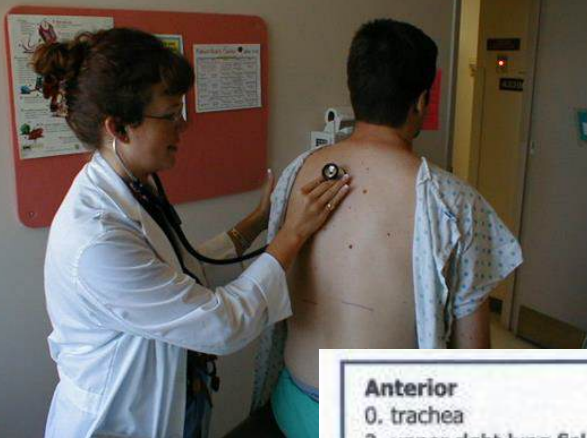Breath sounds					
	Duration	Expiration	Location		
Vesicular  	inspiratory > expiratory	soft low pitch	over the whole lungs		
Bronchovesicular  	inspiratory = expiratory	medium loud medium pitch	peristernal interscapular		
Bronchial  	expiratory > inspiratory	loud, strong high pitched	above clavicle manubrium sterni		
Tracheal  	expiratory = inspiratory	very loud high pitched	very loud high pitched		

Sound records from: Bohadana, A. et al.: Fundamentals of lung auscultation. N Engl J Med. 2014 Feb 20;370(8):744-751.

Basic breathing patterns

- Vesicular
- Bronchial
- Bronchovesicular
- Tracheal

Basic breathing sounds and modifications

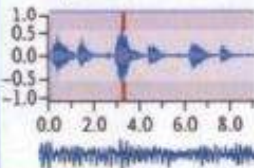


Anterior

0. trachea
2. upper right lung field
3. upper left lung field

Stridor

Frequencies: > 500 Hz
Sound: high pitch, distant
Site: larynx, trachea, bronchi
Phase: inspiratory or expir.
Cause: laryngeal edema, epiglottitis, croup, tumors, aspiration, abscess



Rhonchi

Frequency: > 150 Hz
Series of > 80 ms bursts
Continuous
Site: trachea, bronchi
Cause: Fluid, mucus in larger bronchi, turbulent
Sound: coarse rattling, low pitch, cleared by cough, "blowing air through fluid"
Phase: mostly expiration



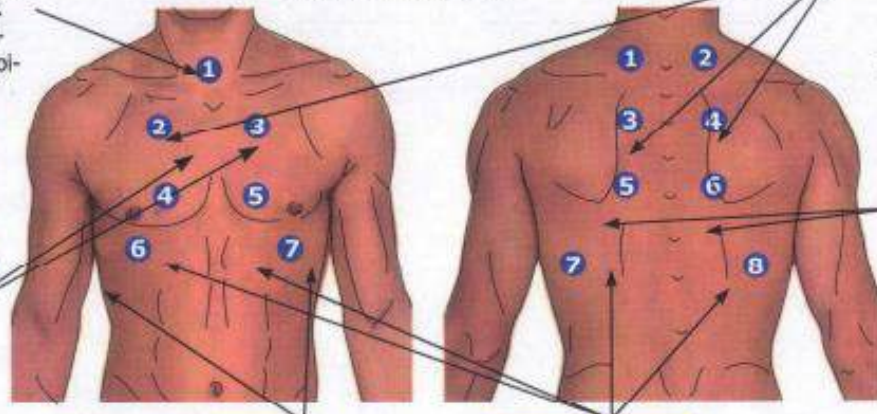
Abnormal breathing sounds

Sound records from: Bohadana, A. et al.: Fundamentals of lung auscultation, N. Engl. J. Med. 20;370(8):744-751, 2014

4. middle right lung field
5. middle left lung field
6. lower right lung field
7. lower left lung field

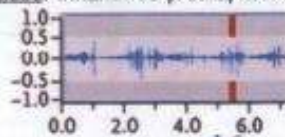
Posterior

1. upper left lung field
2. upper right lung field
3. middle left lung field
4. middle right lung field
5. lower left lung field
6. lower right lung field
7. left costphrenic angle
8. right costphrenic angle



Pleural friction rub

Frequency: < 350 Hz
Series of irregular > 15 ms bursts
Sound: grating, does not clear with cough
Phase: best in inspiration
Site: anterior lateral lung field in sitting
Cause: inflamed pleura, tumors

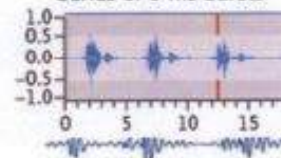


Crackles (rales)

Sound: Rapidly dampened waves
Site: lung bases
Phase: inspiration, expiration

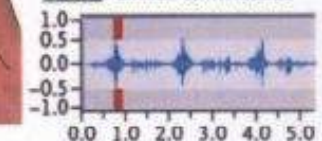Fine crackles

Frequencies: > 650 Hz
Series of 5 ms bursts



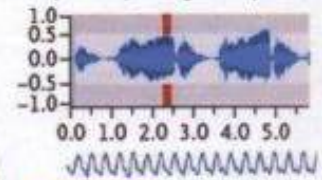
Squawk

Frequency: > 500 Hz
About 200 ms sound bursts
Cause: similar to wheezes



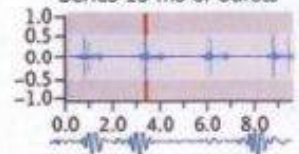
Wheezes

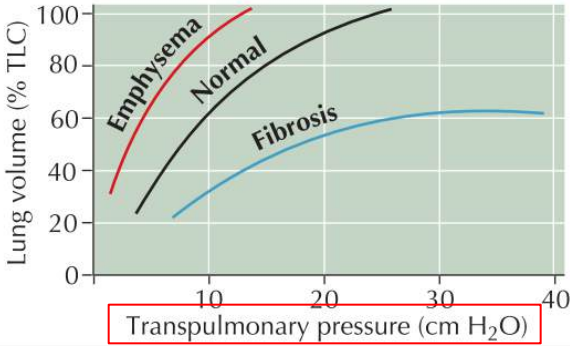
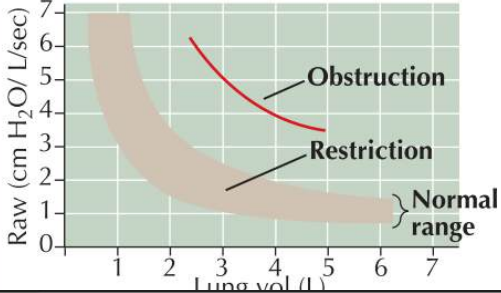
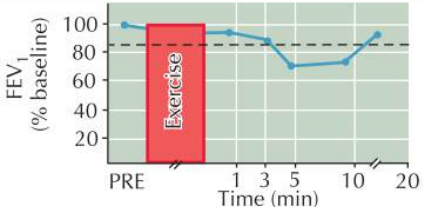
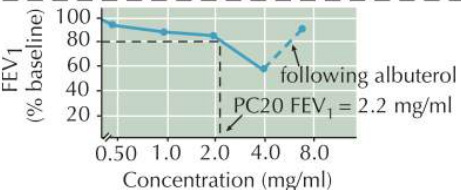
Frequencies: > 100-5000Hz (400)Hz
Series of > 80 ms bursts; Continuous
Sound: high pitch; musical sound
During: inspiration or expiration
Site: all lung fields
Cause: severely narrowed bronchus, asthma, COPD, foreign body



Coarse crackles

Frequencies: > 350 Hz
Series 15 ms of bursts



Test	Symbol	Method	Interpretation
Lung elasticity Static recoil pressure Static compliance Elasticity	P_{stat} C_{stat}	Pleural pressure (Ppl) is estimated as esophageal pressure measured with an esophageal balloon catheter, and alveolar pressure (Palv) is estimated as mouth pressure under conditions of no flow. Transpulmonary pressure (Ptp) is the difference of Palv - Ppl. Ptp is recorded at different lung volumes during expiration from TLC.	 <p>Static elastic recoil of lung is increased and static compliance reduced in diseases such as pulmonary fibrosis. Conversely, static lung compliance is increased and elastic recoil is reduced in emphysema</p>
Resistance Airway resistance	Raw	Celotelová pletyzmografia Body plethysmograph to determine alveolar pressure and pneumotachograph to measure airflow	 <p>In obstructive lung disease airway resistance is increased. If obstruction involves only small airways (<2 mm diameter), only minimal changes in overall resistance may result. In restrictive disorders, resistance is often reduced because of increased traction on intrathoracic airway walls</p>
Muscle pressures Maximal inspiratory pressure Maximal expiratory pressure	MIP MEP	MIP measured as maximal pressure during inspiration from near RV. MEP measured as maximal pressure during expiration from near TLC.	MIP > -50 (F), -75 (M) cm H ₂ O MEP > 80 (F), 100 (M) cm H ₂ O Reduced muscle pressures indicate neuromuscular weakness or suboptimal effort.
Bronchial challenge Exercise	ΔFEV_1	Spirometry before and after 6-10 min of exercise to increase heart rate to >85% of predicted maximum, or to increase ventilation to 40-60% of predicted MVV.	 <p>Positive response is decreased in FEV₁ from baseline by >15%</p>
Methacholine	PC20	Spirometry before and after serially increasing doses of inhaled nebulized methacholine. PC20 = provocative concentration causing a fall in FEV ₁ by 20%.	 <p>Positive response is decreased in FEV₁ by 20% at a dose of less than 8 mg/ml (PC20 < 8 mg/ml)</p>

Blood gas analysis

Test	Symbol	Method	Normal values
Gas exchange			
Partial pressure of O ₂ in arterial blood	P_{aO_2}	Arterial blood is collected anaerobically in heparinized syringe	80 to 100 mm Hg breathing room air at sea level. Falls slightly with age.
Partial pressure of CO ₂ in arterial blood	P_{aCO_2}		36 to 44 mm Hg
Arterial blood pH	pH		7.35 to 7.45 pH
Alveolar-arterial O ₂ difference, or A-a gradient	$\left\{ \begin{array}{l} A-aP_{O_2} \\ A-a\Delta \end{array} \right.$		< 10 mm Hg breathing room air. Upper limit of normal approximated by $(age/4) + 4$
Dead space-tidal volume ratio	V_d/V_T	Determined from arterial and mixed expired P_{CO_2}	< 0.3- 0.4
Shunt fraction	\dot{Q}_s/\dot{Q}_T	Determined from P_{aO_2} after a period of breathing 100% O ₂	< 5%

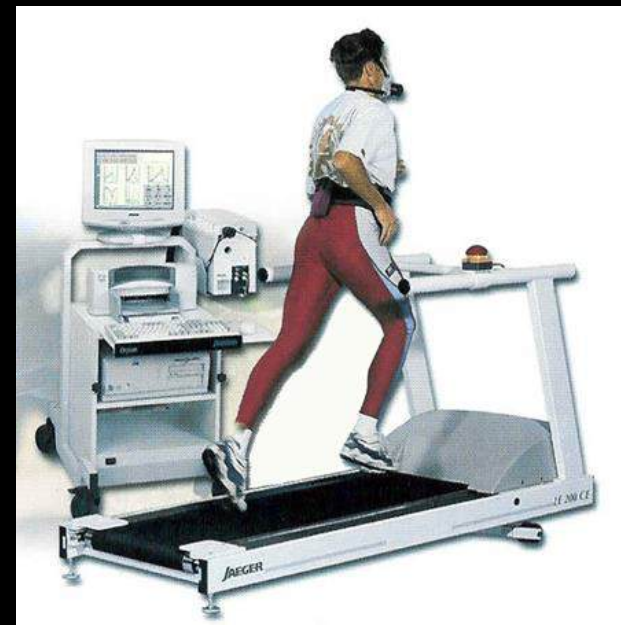
$P_{ATM} \sim 158$ mmHg
 $P_{H_2O} \sim 48$ mmHg
 $P_{A}O_2 \sim 110$ mmHg
 $P_{a}O_2 \sim 90-100$ mmHg


A-a gradient

Elevation indicates i systemic circulation either because of sh or perfusion of regio

Ergospirometry

- Treadmill exercise, bicycle ergometry et different levels (Watts)
- Cardiopulmonary exercise stress test (CPET) - treadmill, bicycle Wasserman charts (gas exchange, FS, ventilation) VO_2 oxygen consumption; VO_2 Max/Peak; drop \rightarrow heart failure, lung disease; VCO_2 (CO_2 production): increases with VE (minute ventilation); VE/VCO_2 slope: marker of ventilatory efficiency. high \rightarrow pulmonary hypertension; heart failure.
- Aerobic threshold (AT/VT1) when lactate begins to accumulate in the blood. Anaerobic threshold (RCP/VT2) O_2 pulse" (VO_2/HR) decrease \rightarrow ischemia, valvular problems. Respiratory exchange ratio (RER)



Cardiopulmonary exercise test		 <p>Increasing work to exhaustion measured using a bicycle ergometer or treadmill, with breath-by-breath analysis and monitoring of RR, TV, HR, BP, ECG, pulse oximetry.</p>
Maximal O_2 consumption	VO_2 max	
CO_2 production	VCO_2	
Maximal predicted heart rate	HRmax	
Heart rate reserve	HRR	
Oxygen pulse (VO_2 /heart rate)	VO_2/HR	
Breathing reserve (BR)	MVV-Ve, or Ve/MVV	
Ventilatory equivalent for O_2 (minute ventilation/ VO_2)	Ve/VO_2	
Ventilatory equivalent for CO_2 (minute ventilation/ VCO_2)	Ve/VCO_2	
Dead space	Vd/VT	
Arterial blood gases	pH, p CO_2 , PO_2 , A-a gradient (A-a Δ)	
Anaerobic threshold	AT	

At maximal exercise:

VO_2 max > 85% predicted (top left)

HRmax > 90% predicted (top right)

HRR < 15 beats per minute

O_2 pulse > 80% predicted (middle, left)

BR > 11 L, or Ve/MVV < 85% (middle, middle)

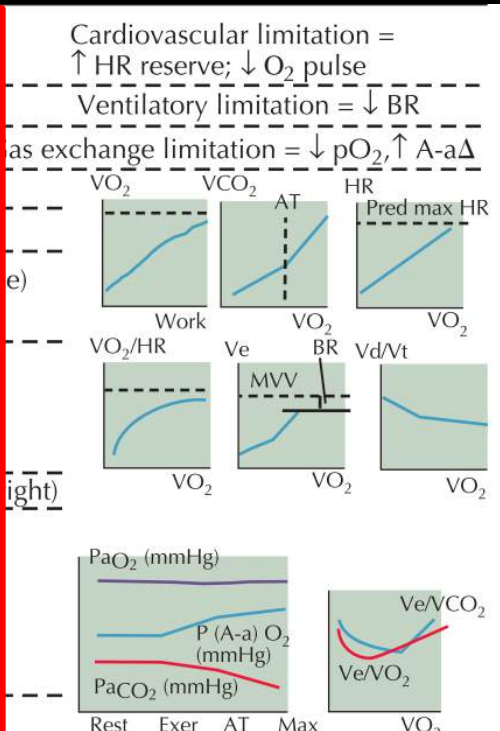
Ve/VCO_2 at AT < 34 (bottom right)

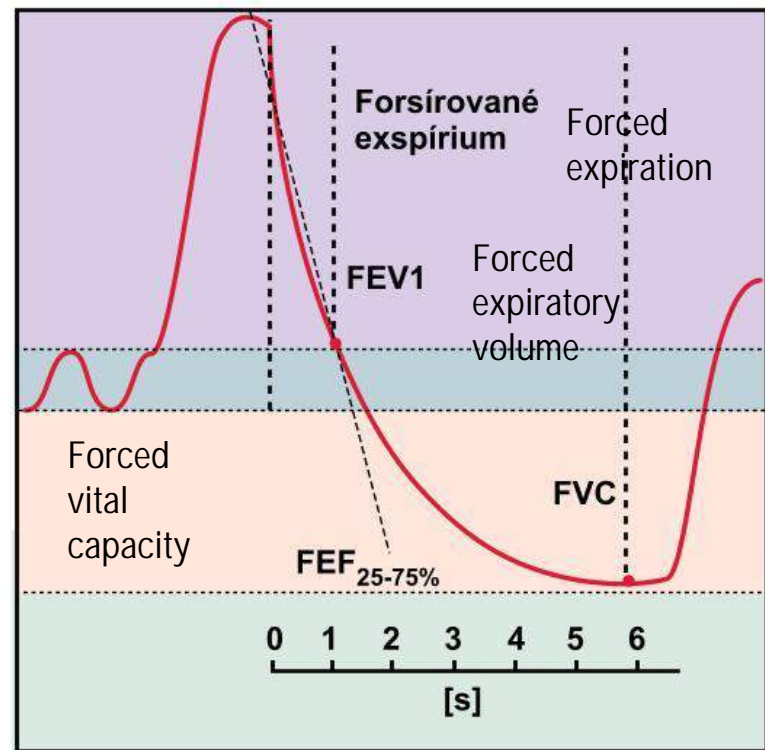
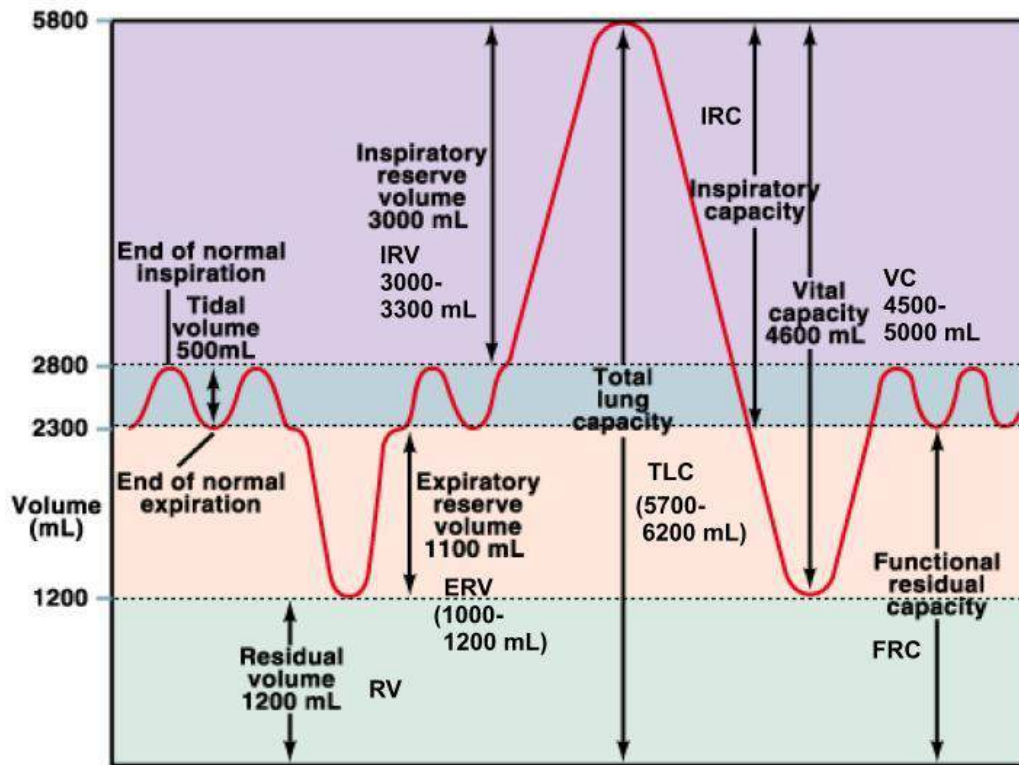
Vd/VT < 0.3–0.4, fall with exercise (middle, right)

PaO_2 > 80 mmHg

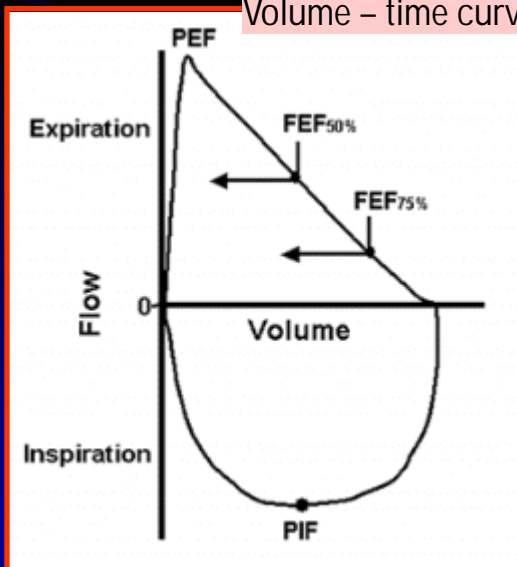
A-a Δ < 35 mmHg (bottom, left)

AT > 40% max predicted VO_2 (top, middle)

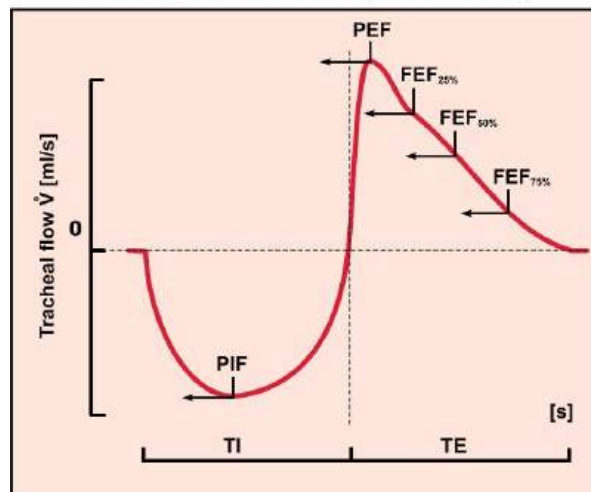




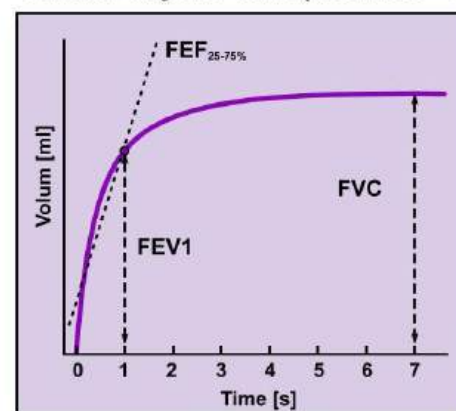
Volume - time curve



Krivka prietok - čas (flow - time)

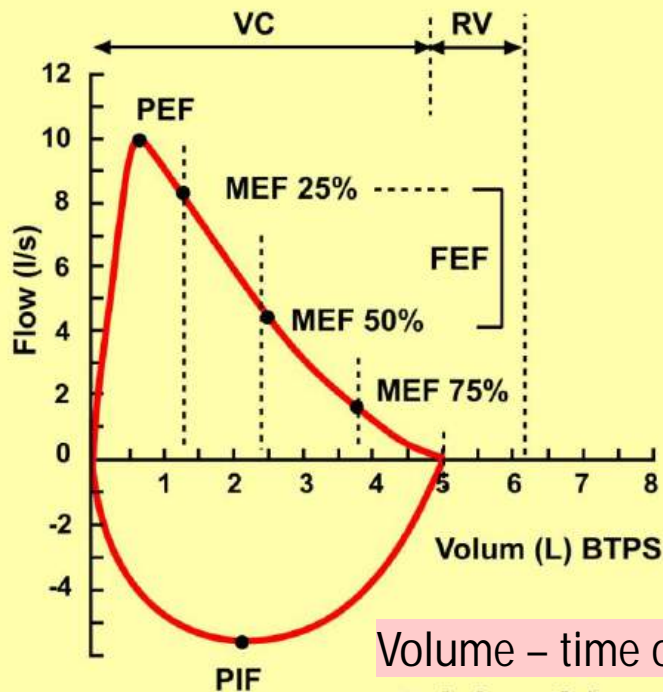


Krivka objem - čas (volume - time)

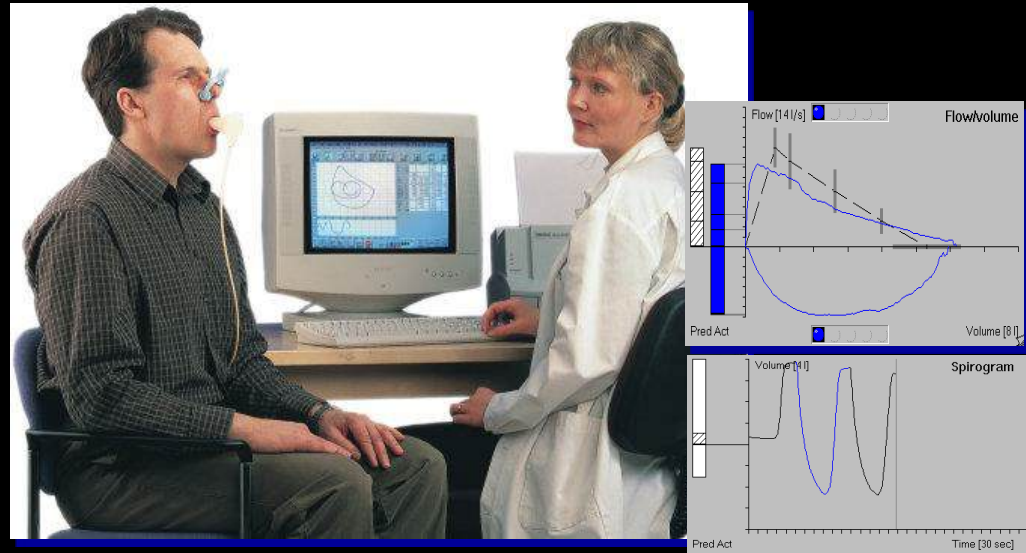
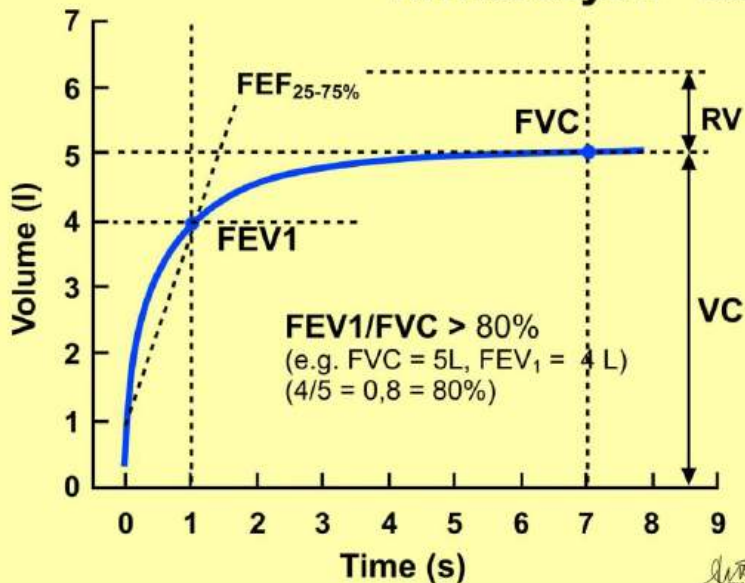


Spirometry

Flow – volume curve **Krivka prietok - objem**



Volume – time curve **Krivka objem - čas**



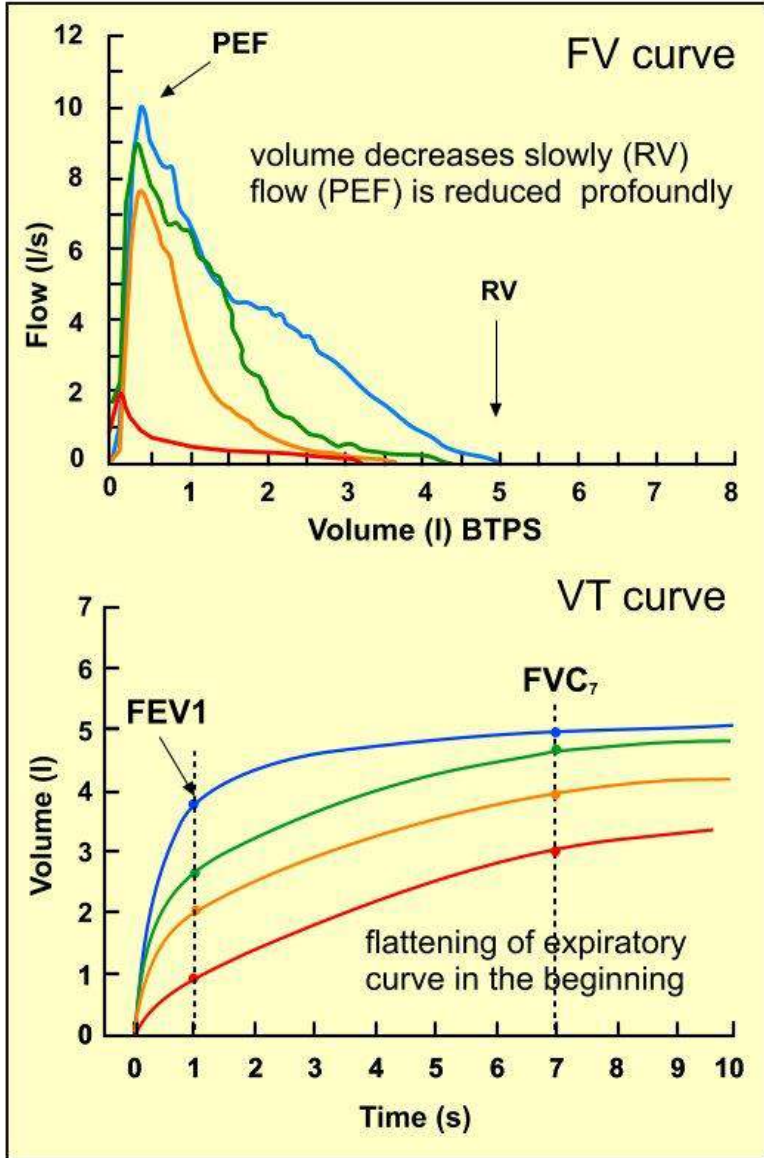
1. Static Lung Volumes

- VC (Vital Capacity)
- RV (Residual Volume)
- FRC (Functional Residual Capacity)
- TLC (Total Lung Capacity)

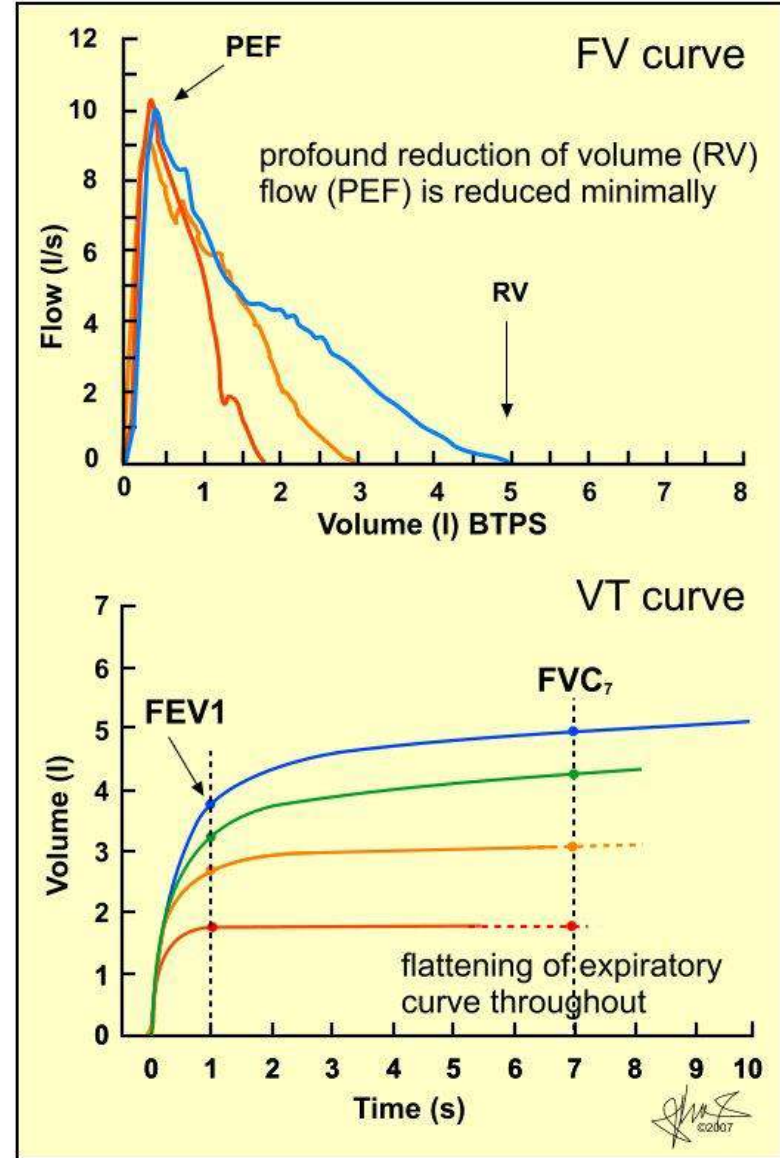
2. Dynamic Spirometry (Flow Rates)

- FEV1 (Forced Expiratory Volume in 1s)
- FEV1/VC (or FEV1/FVC) Ratio
- PEF (Peak Expiratory Flow)
- MEF (Mid-Expiratory Flows 25-75 % of expiration)

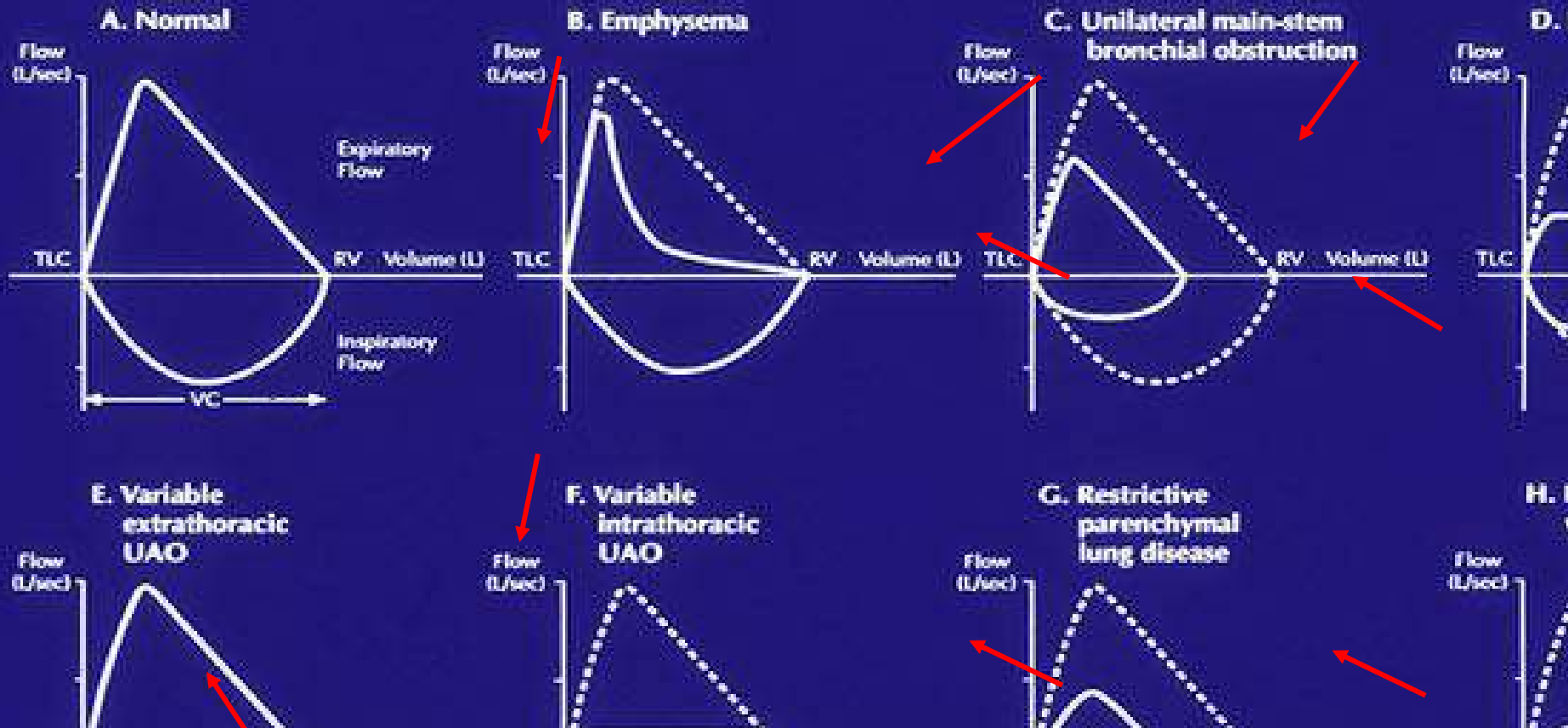
OBSTRUCTIVE DISORDERS



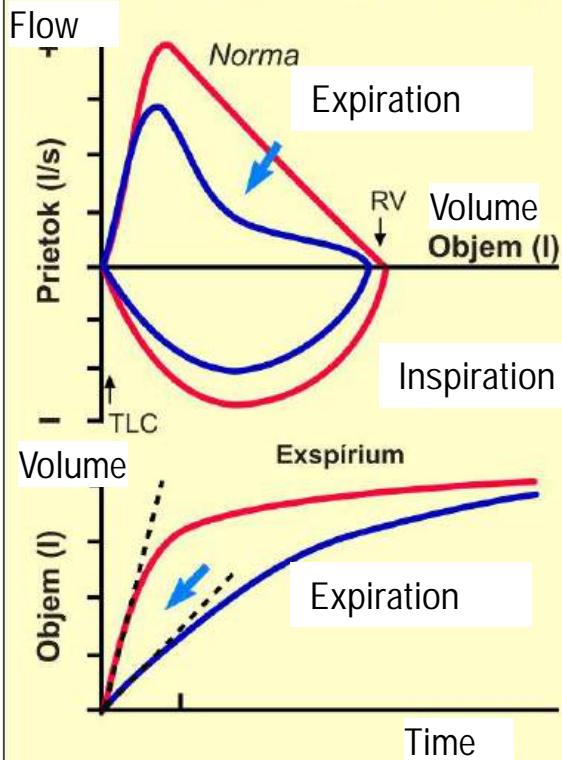
RESTRICTIVE DISORDERS



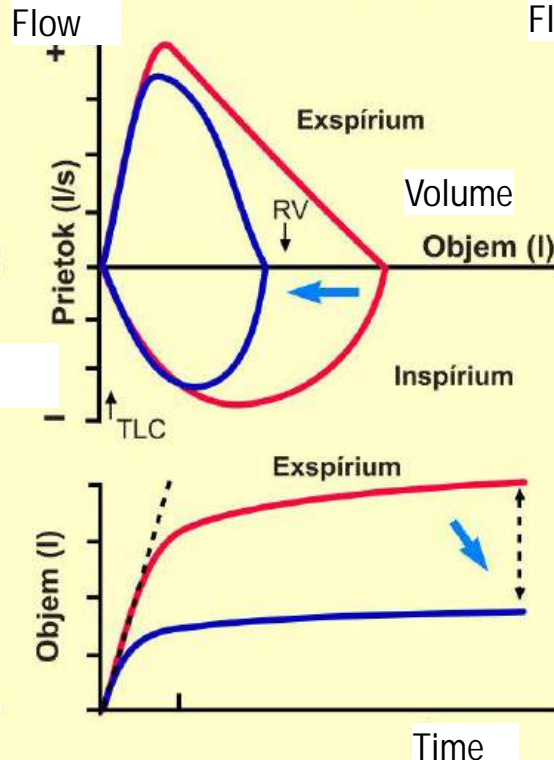
Volume- flow curves in various disorders



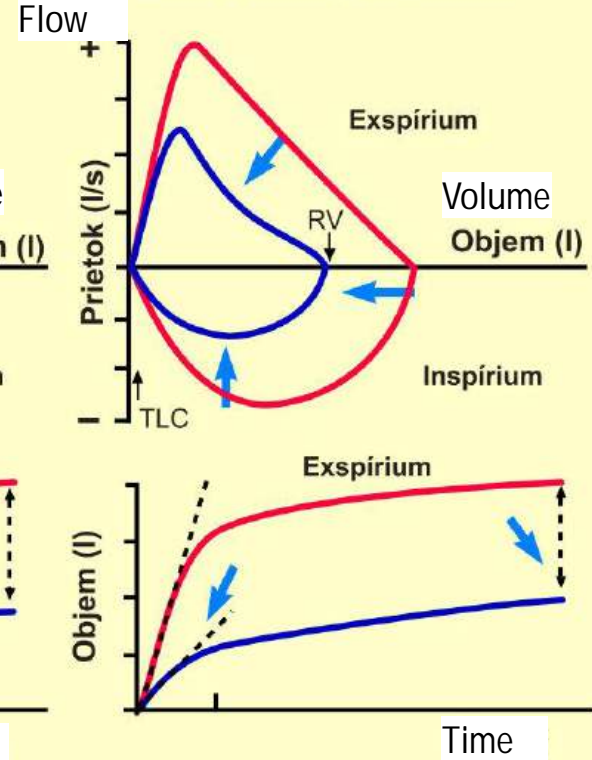
Obstructive disease



Restrictive disease



Mixed disease



FEV1	↓↓ (<80%)
FVC	Norma / ↓ (> 80%)
FEV1/FVC	↓↓ (<70%)
PEFR	↓
MVV	↓
TLC	Norma / ↑
RV	Norma / ↑
DLCO	Norma

Variabilne (N / ↓ / ↑)	↓ (< 80%)
	↓ (< 80%)
	Norma / ↓ (> 70%)
	Norma / ↑
	Norma / ↓
	↓ (< 80%)
	↓
	Norma

	↓ (< 80%)
	↓ (< 80%)
	↓ (< 70-80%)
	↓
	↓
	Variabilne (N / ↓ / ↑)
	Variabilne (N / ↓ / ↑)
	Norma

Respiratory diseases



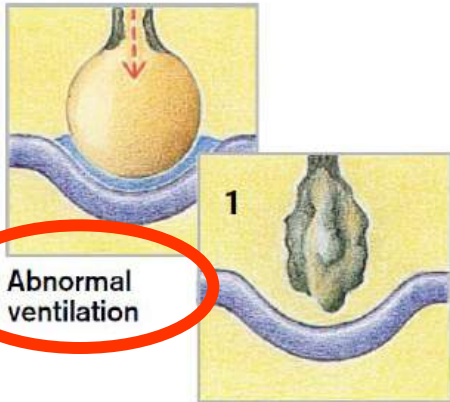
Obstructive diseases (OPD)

- restricted expiration
- ↓ FEV₁
- ↑ compliance, elasticity
 - Chronic bronchitis
 - Emphysema
 - COPD (chronic obstructive pulmonary disease)
 - Asthma
 - Bronchiectasia
 - Cystic fibrosis
 - Atelectasis (not pure OPD)

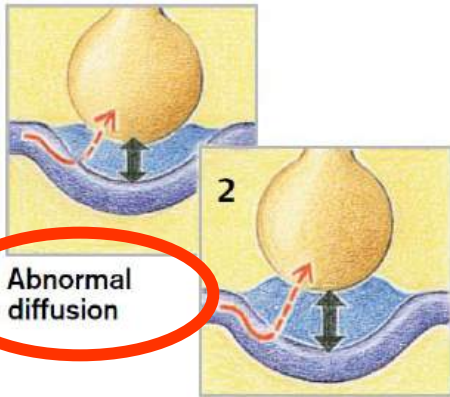


Restrictive diseases (RPD)

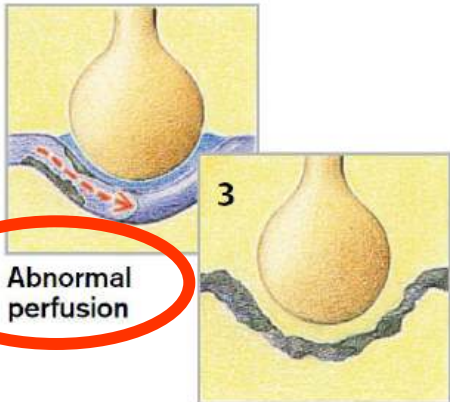
- restricted inspiration + expiration
- ↓ VC
- ↓ compliance, elasticity
 - Interstitial diseases: pneumonia
 - Fibrosis of lungs –pneumoconiosis, asbestosis, silicosis, berylliosis, farmers lungs
 - Restriction to breathing: pneumothorax, ribcage malformities, fracture, obesity



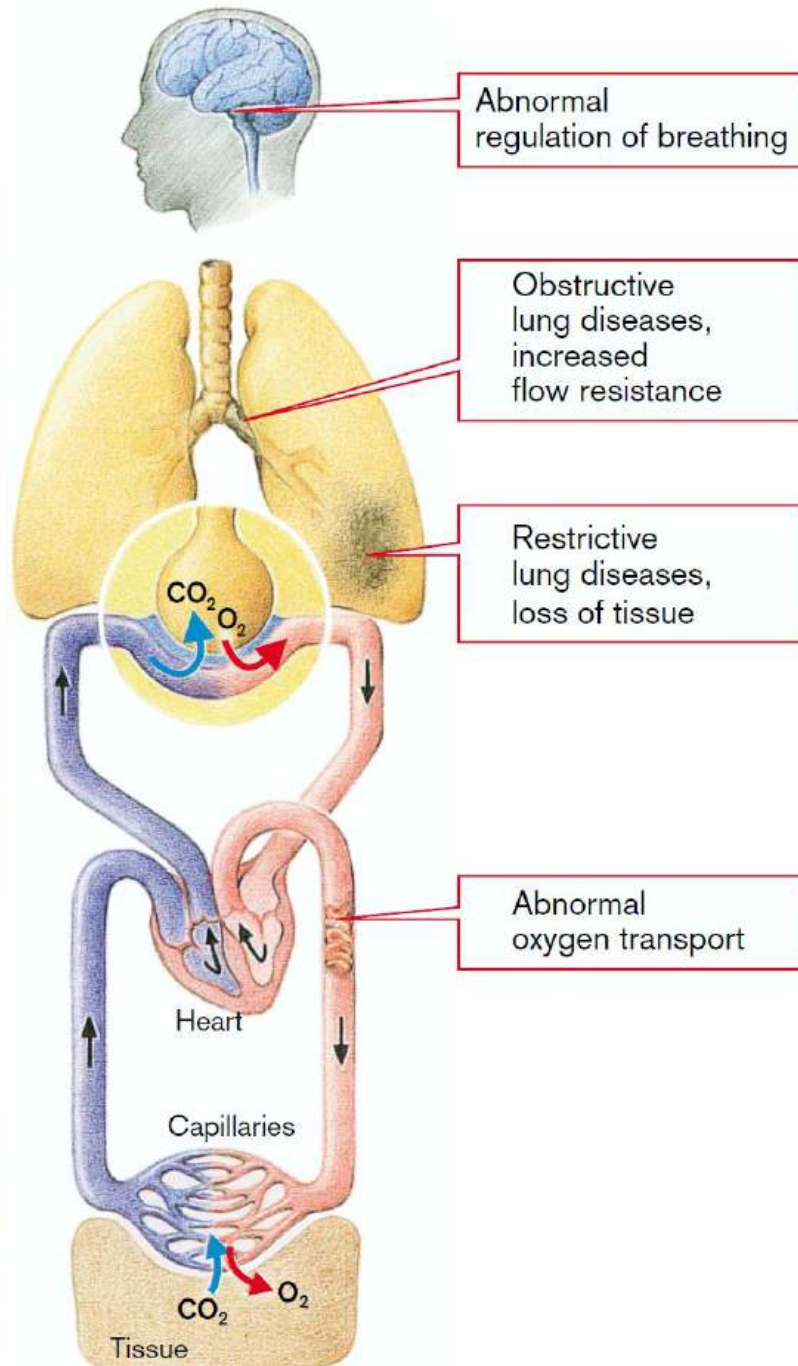
Abnormal ventilation



Abnormal diffusion



Abnormal perfusion



Diseases affecting respiration

Disorders of breathing pathways

- Asthma, acute bronchitis, chronic bronchitis,
- Bronchiolitis, COPD
- Obstructive sleep apnoea

Chest deformation

- Kyphoskoliosis, Pectus excavatum
- Spondylartróza ankylopoetica
- (M. Bechterev), Chondrodystrofia

Disorders of the diaphragm

- Hernia, malformations, high diaphragm

Disorders of pleura

- Pleuritis sicca, pleural effusion, pleural thickening, pneumothorax

Diseases of the lung tissue

- Pneumonia, pulmonary fibrosis, pneumoconiosis (asbestosis, silicosis, berylliosis, farmer's lung, etc.)

Muscular disorders

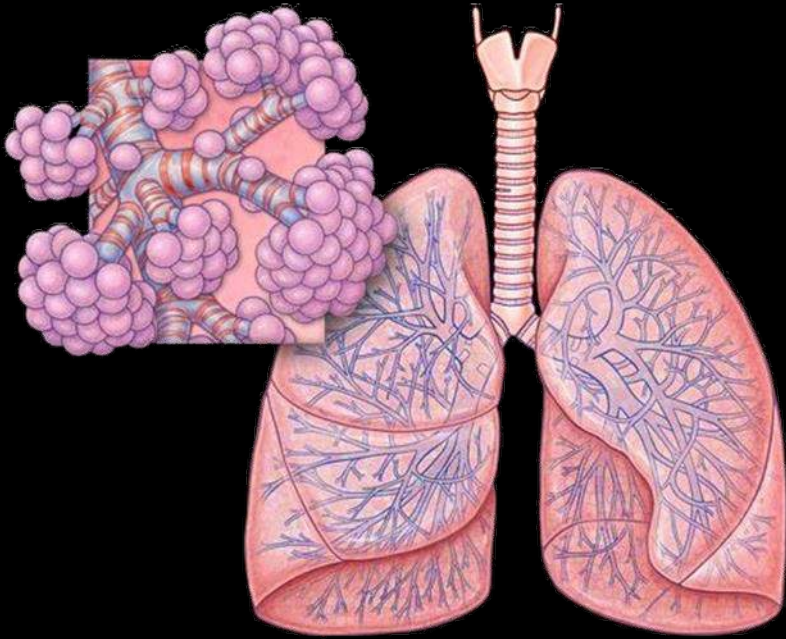
- Inflammatory - dermatomyositis/polymyositis, viral infections, trichinosis
- Rhabdomyolysis, metabolic disorders (hypothyroidism, thyrotoxicosis, metabolic acidosis, etc.), drugs (corticosteroids, etc.), muscular dystrophies

Neuromuscular diseases

- Botulism, myasthenia gravis, myasthenic-myotonic sy. (Eaton-Lambert)
- Intoxications (ACHE inhibitors), tetanus, poisons (curare), drugs: myorelaxants,

Nervous disorders

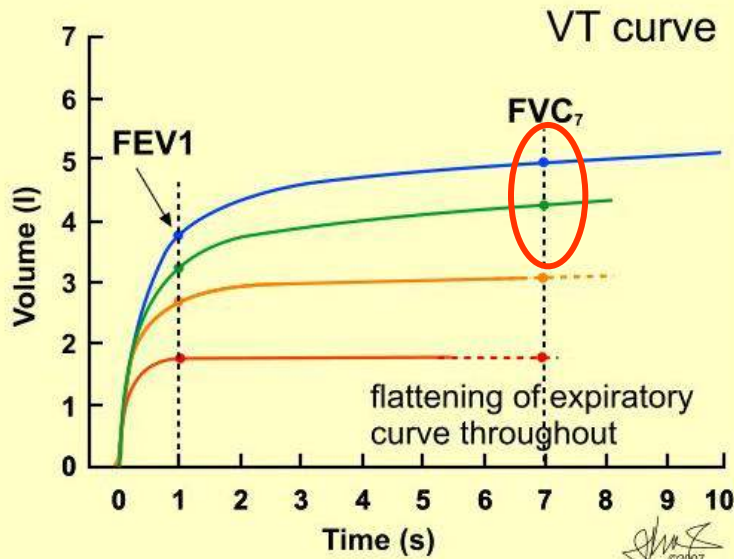
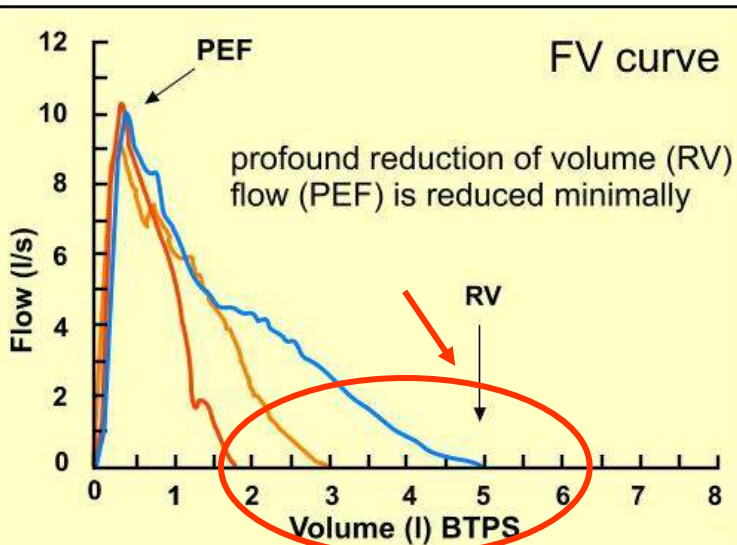
- Trunk apoplexy, cerebellar atrophy, trauma & atraumatic lesions of the cervical spinal cord (C3-6),
- Poliomyelitis (polio), ALS, sclerosis multiplex (SM), sy. Guillan-Barré
- Central respiratory depression: morphine, heroin, anesthetics, barbiturates,
- Lyme disease, tumors, M. Parkinson
- Sy. central sleep apnoea



Restrictive disorders

Examples

Findings in restrictive diseases



1. Static lung parameter (plethysmography)

↓ VC, ↓ RV (in fibrosis), ↓ FRC
 ↓ TLC < 80% predicted or Z-score < -1.645).
 This is the definitive marker for restriction.

2. Dynamic lung parameters (spirometry)

↓ FEV1 (Forced Expiratory Volume in 1s):
 N or ↑ FEV1/VC (or FEV1/FVC) hallmark
 N or ↓ PEF (Peak Expiratory Flow)
 N or ↑ MEF (Mid-Expiratory Flows):

3. Mechanics and Resistance

↓↓ Compliance (C): lungs are "stiff."
 N or ↓ Raw (Airway Resistance)

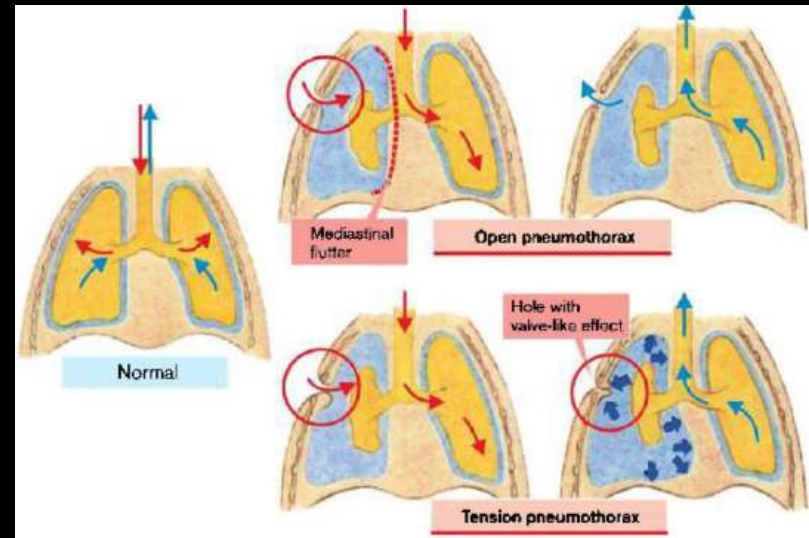

$$C = \frac{\Delta V}{\Delta P}$$

4. Other

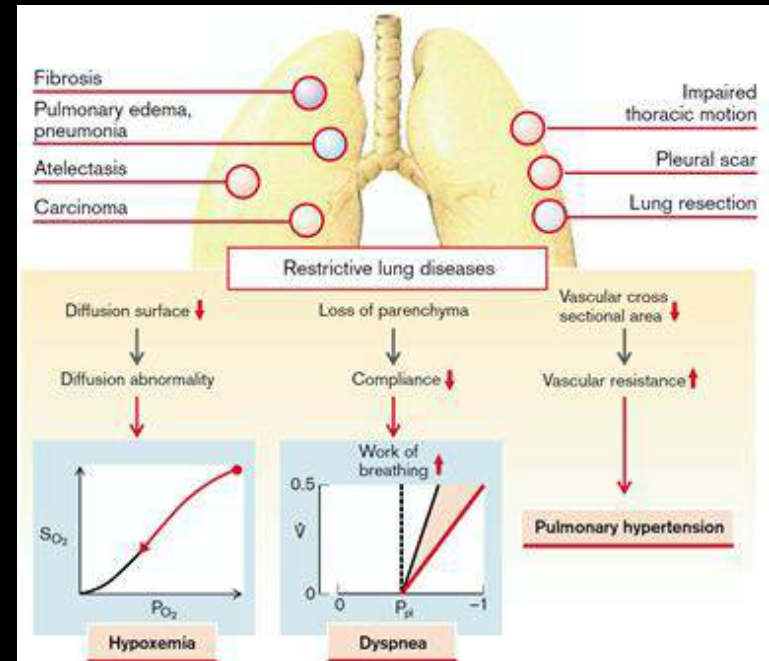

↓ DLCO (Diffusing Capacity): Intrinsic dis. (fibrosis etc)..
 ↑ A-a Gradient: (Intrinsic disease – fibrosis)

Restrictive disorders - Mechanisms

- Oppression and decreased mobility of lung tissue (restriction)
 - Pleural effusion (pleuritis, hemothorax, chylothorax)
 - Pneumothorax (air in the pleural cavity)
 - Lung & pleural tumours, metastases;
 - Deformities: kyphosis of the spine, pectus excavatum, carinatum, M. Bechterev,
 - Neuro-muscular dis.: poliomyelitis, myasthenia gravis, diaphragmatic paresis etc.



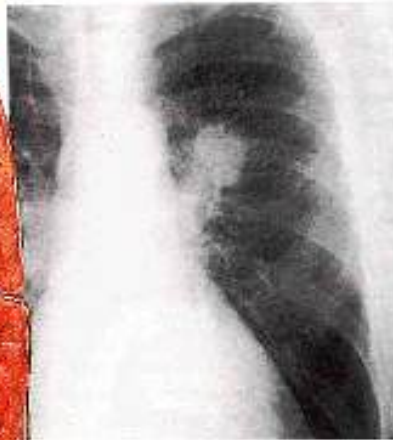
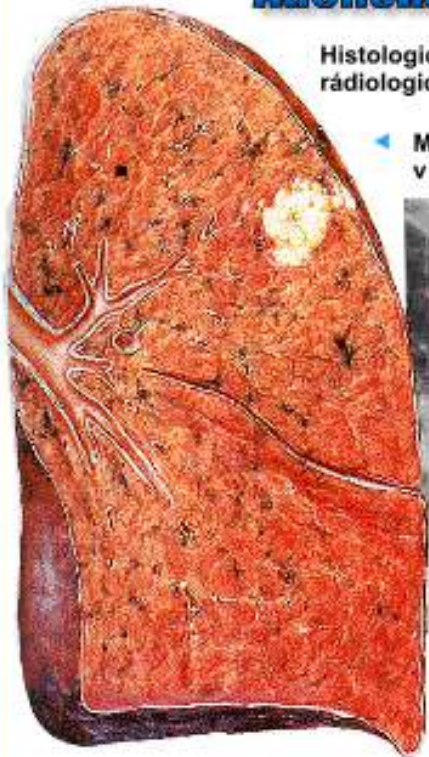
- Loss of lung tissue, decreased lung elasticity, impaired gas exchange
 - Fibrosis of the lungs due to various etiologies
 - Pneumoconiosis
 - Pneumonia – lobar; atelectasis,
 - Malignancy, oedema of lungs, etc.



Adenokarcinóm

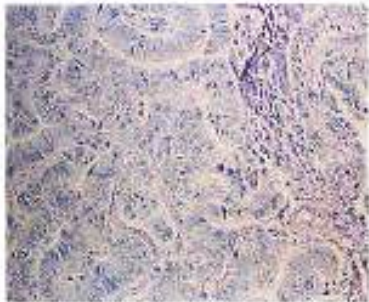
Histologická diagnóza sa zakladá na rádiologických a makroskopických nálezoch.

▶ Malý periférny nádor v ľavom laloku ▼

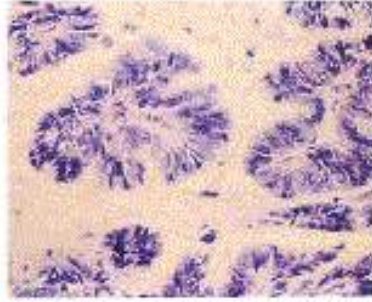


Adenocarcinoma

Rôzny histolický obraz nádoru



▶ Nádorové bunky vytvárajú žľazovité útvary tvoriace mucín

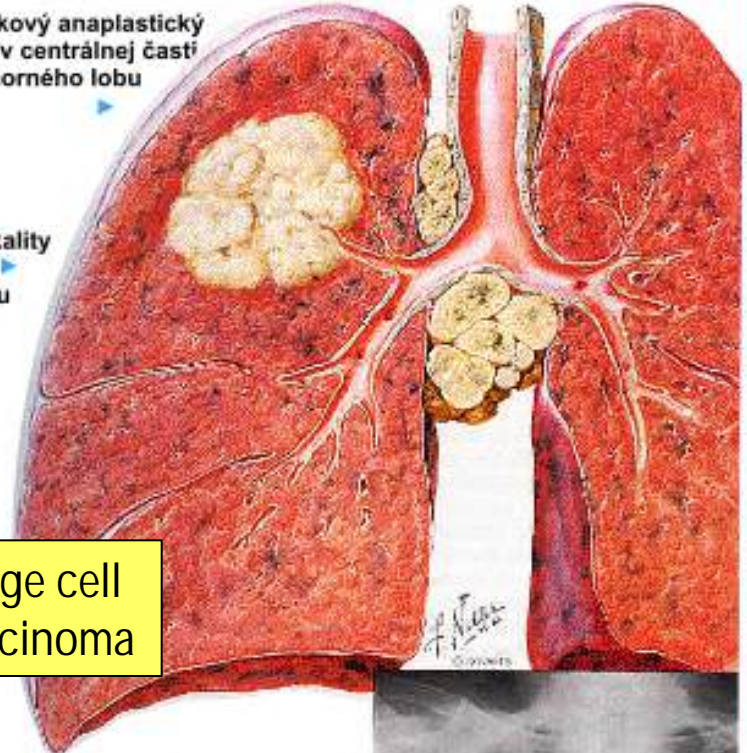


▶ Nádorové bunky môžu tvoriť papilárne útvary

Veľkobunkový karcinóm

Veľkobunkový anaplastický karcinóm v centrálnej časti praveho horného laloku

Rôzne lokality výskytu karcinómu ▶

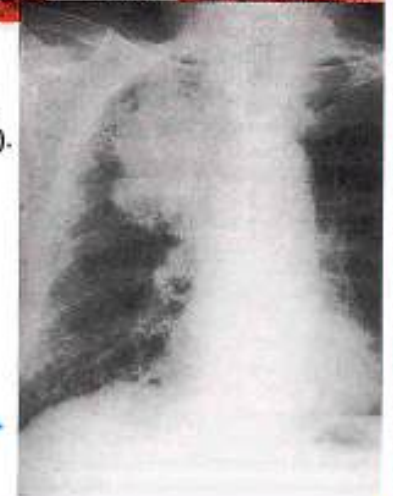


Large cell carcinoma

▶ Tumor tvoriaci veľké mnohoadrové bunky produkujúce mucín (červeno).



▶ Atektáza v pravom hornom laloku spôsobená upchaním hlavného bronchu karcinómom



Pneumonia

■ Def.: acute inflammatory changes of the lung parenchyma of infectious origin causing oedematous overlap of tissue, gas diffusion disorders

■ Forms: = according to lung distribution:

■ bronchopneumonia - distal pathways and alveoli;

■ lobular pneumonia, part of the lobule; lobar pneumonia, whole lobe

= according to the infective agents:

■ bacterial Gram (-) or Gram (+), viral (influenza), unspecified - pneumococcal, yeast, nonspecific, nosocomial – resistant species hospitalization for other causes

■ Signs/ Symptoms:

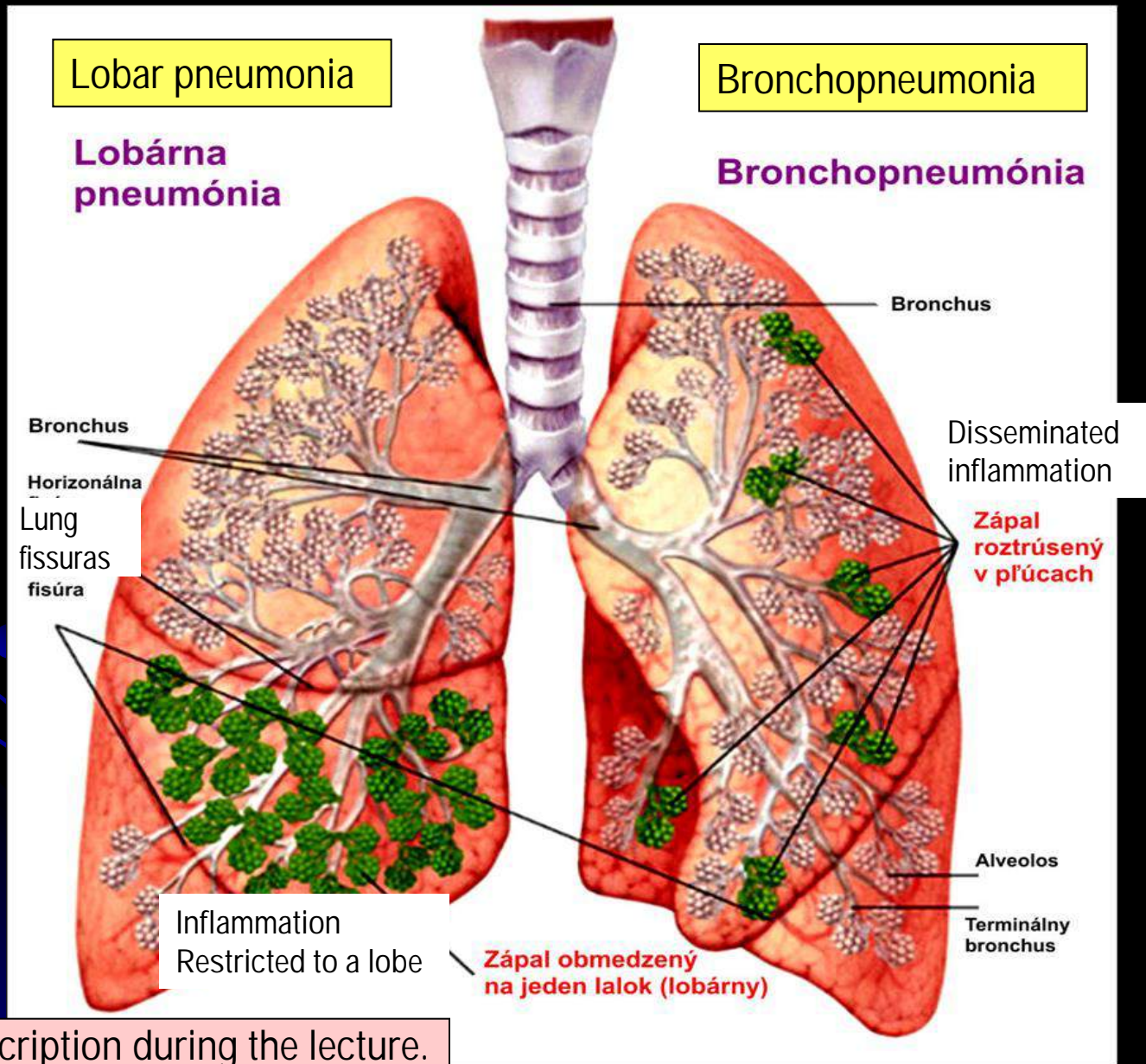
■ Fatigue, malaise, fever - high continuous or intermittent, muscle tremors

■ Exertional breathing (dyspnea), productive cough - sputum white or green

■ Fine crackles localized or more diffuse

■ Pleural effusion, pain on breathing

Pneumonia



Verbal description during the lecture.

Pleural cavity

Def: Pneumotorax (PNO) – nahromadenie vzduchu v pleurálnej dutine s kolpsom pľúc (čiastočný/ úplný) zrýchlenie srdcovej frekvencie s poklesom krvného tlaku.

Epi: spontaneous - 7-18 m and 1.2 to 6 / 100,000 inhabitants; Typically: Long, thin men+ smokers

Types: a) a simple PNO - one side, without overpressure, without endangering life;

b) tension PNO - dangerous, valve moss. → increasing lung oppression → pressing and the other side; vascular oppression → drop in blood pressure → acceleration of heart rate

Traumatic PNO - perforation of the chest wall from the outside, in fractures of the ribs, injuries of the lip, bronchi, or fracture of the ribs.

Spontaneous PNO - atraumatic (bronchiectasis, tumor, etc.)

- primary idiopathic - otherwise healthy, tall young men; secondary - bronchiectasia, cystic fibrosis, COPD, etc.)

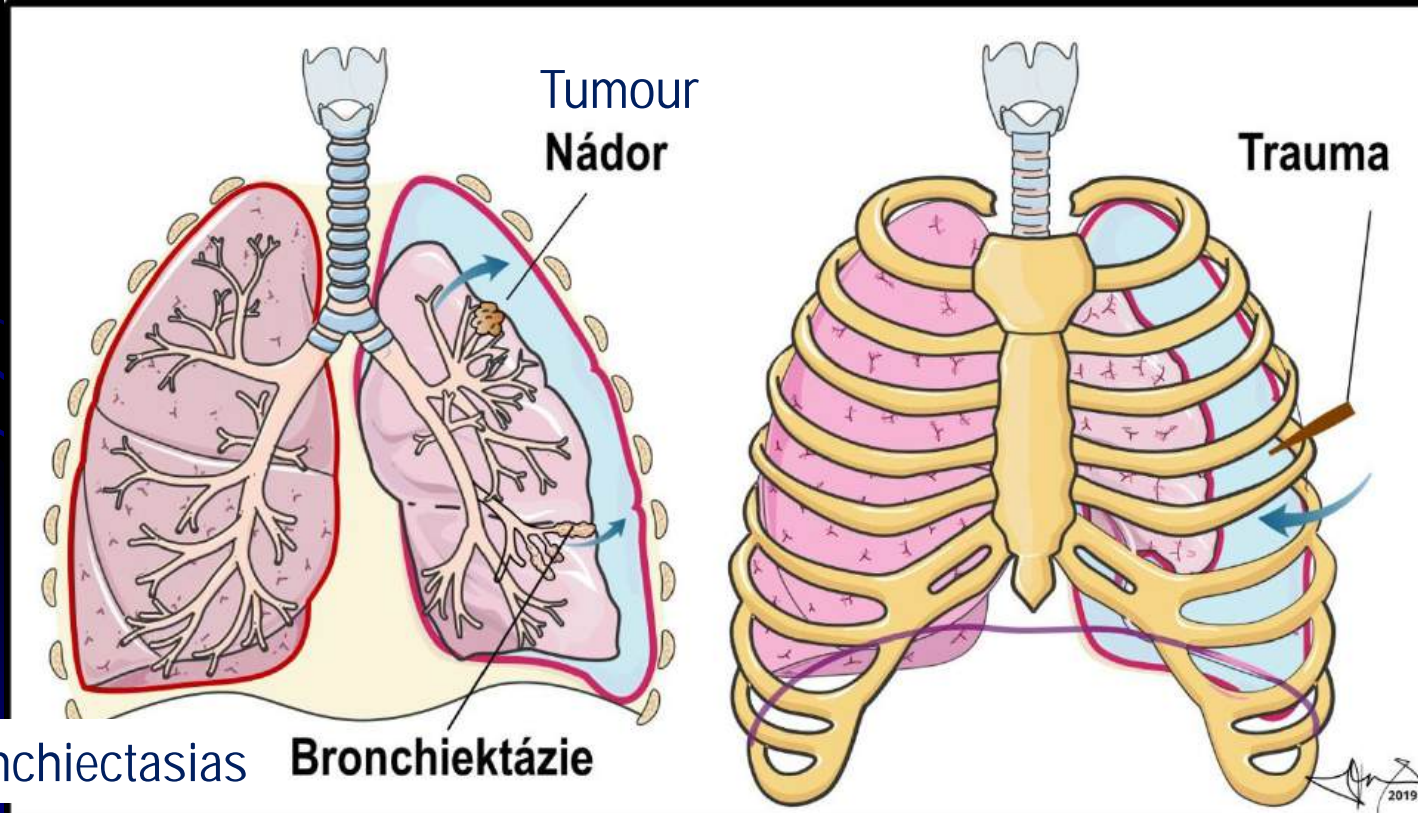
Iatrogenic PNO - in invasive procedures (central veins cannulation (subklavia); transbronchial lung biopsy, transparetal aspiration biopsy (between the ribs); injections, acupuncture, spine, thoracic puncture, pressurized ventilation.

Other diseases: Chylothorax - lymphatic fluid in the pleural space; Hemothorax - disruption of intrapleural blood vessels.

Pneumothorax

Ptg.: 1) an increase in transpulmonary pressure → alveolar distension → rupture; 2) rupture of surface alveoli, 3) respiratory infection → necrosis, inflammation; 3) rupture of central alveoli → perivascular around bronchi towards visceral pleura → pneumomediastinum, subcutaneous emphysema event, pneumoperitoneum.

Manif.: Small PNO <25% of hemithorax volume; in adults <2 cm the distance → normal physical finding. Large PNO > 25% of the volume of hemithorax; coughing, dyspnoea, pleural pain, pricking.



Atelectasis – lung collapse

Def: airlessness of the lung tissue (both lungs, one wing, small, large part due to collapse of the alveoli)

Forms: a) Congenital (atelectasis) - (in a narrower sense) underdevelopment of the lungs in newborns; b) Acquired, secondary (collapse) - in children, adults, etc. - the lungs were already developed, but became airless secondarily)

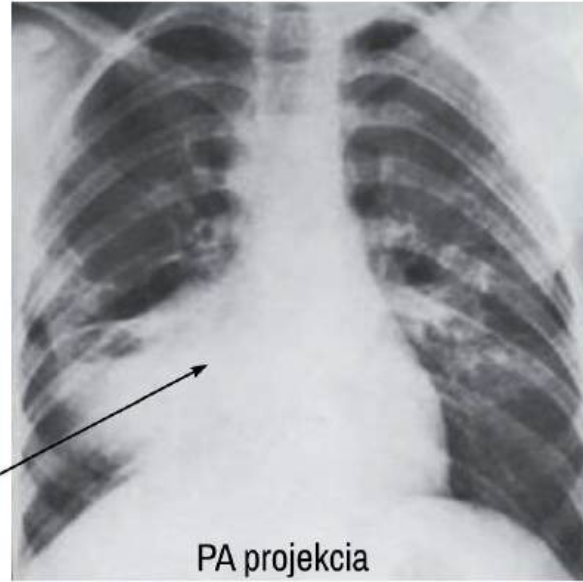
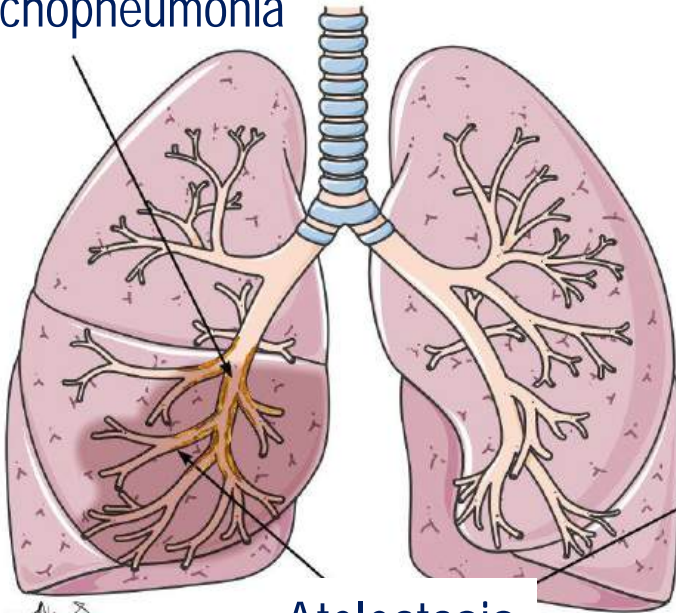
Etio: 1) **Immature newborns** (insufficient surfactant formation); aspiration of amniotic fluid
2) **Pulmonary ventilation disorders** - central (central hypoventilation) in CNS damage; peripheral - chest deformities, etc.;

Forms: 1) **Obstructive collapse** - bronchial stenosis / obstruction → air resorption behind obstruction (inhalation of body, asthma - secretion, tumor, lymph. nodules, aortic aneurysm). 2) **Compressive collapse** - displacement of air from the lungs (pneumothorax) lung-based pressure.

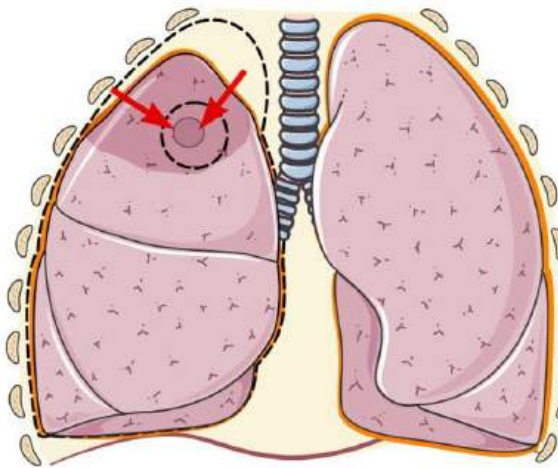
Pathol: splenisation (irreversible st. - the lungs are reddish-purple with a consistency similar to spleen)

Manif.: onset often asymptomatic; increased susceptibility to infections; infections-dysectic pneumonia; secondary bronchiectasis.

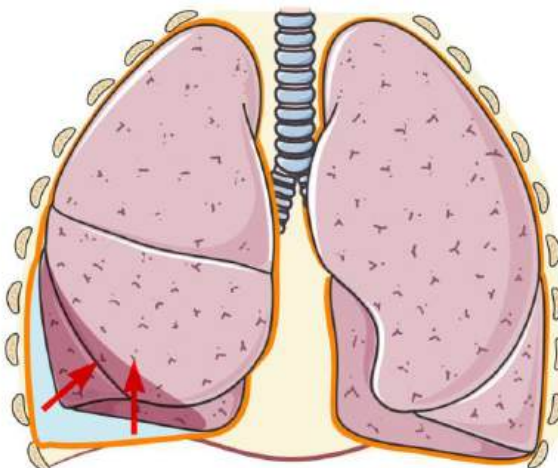
Bronchopneumonia



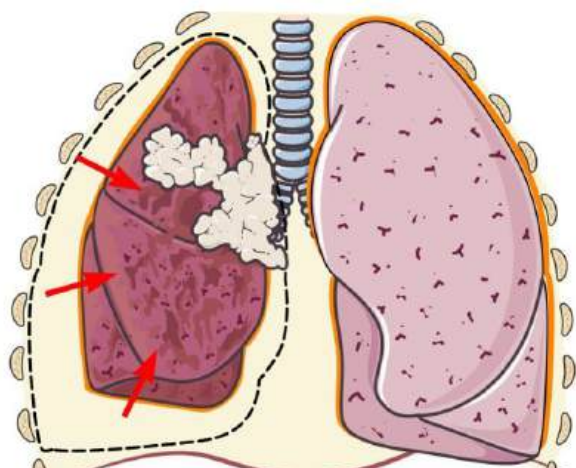
Atelectasis



Resorption



Compression



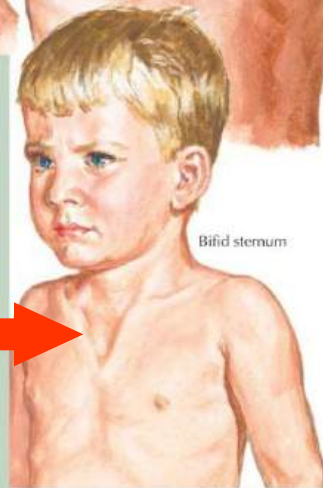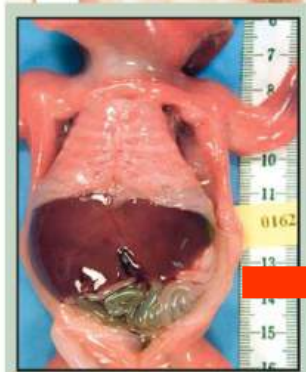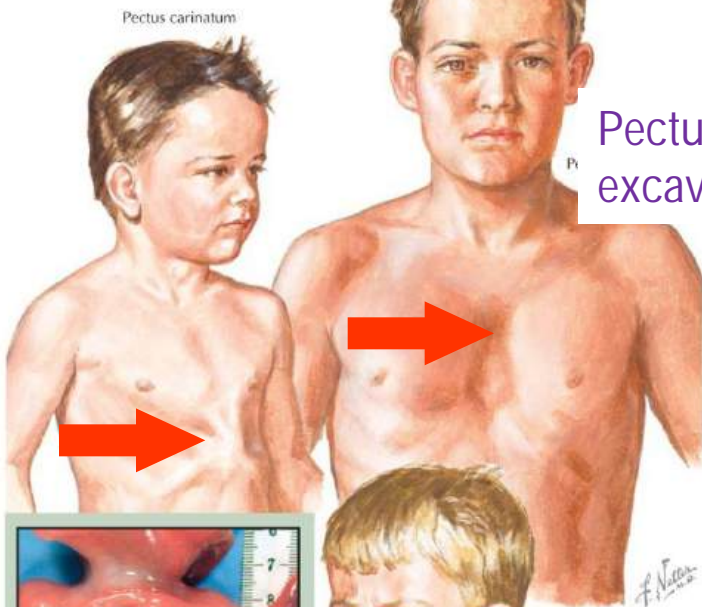
Contraction



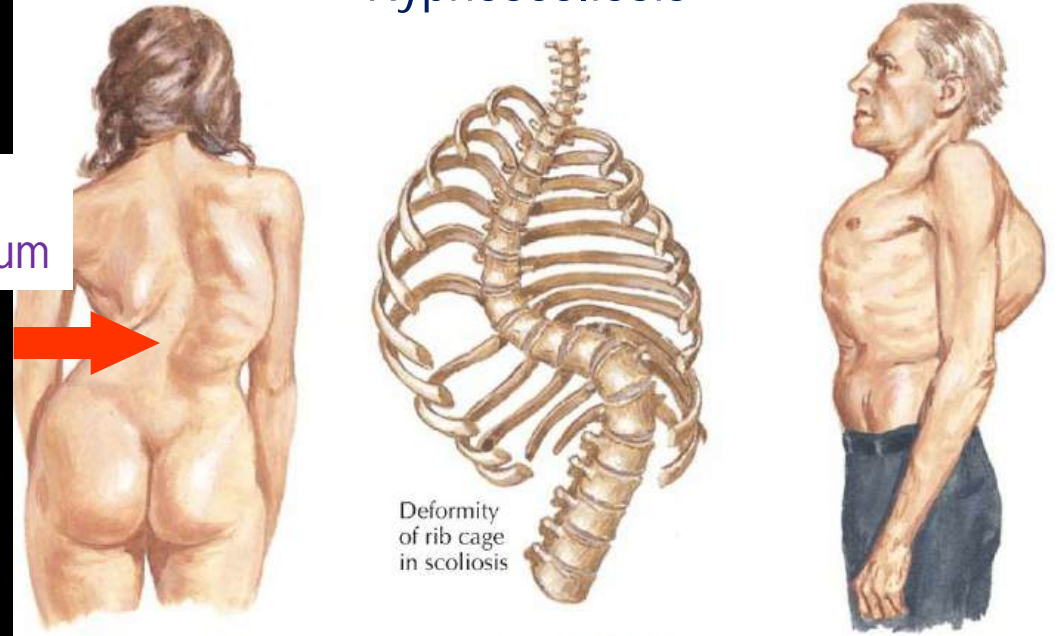
Restrictive disorders

Chest anomaly

Pectus carinatum

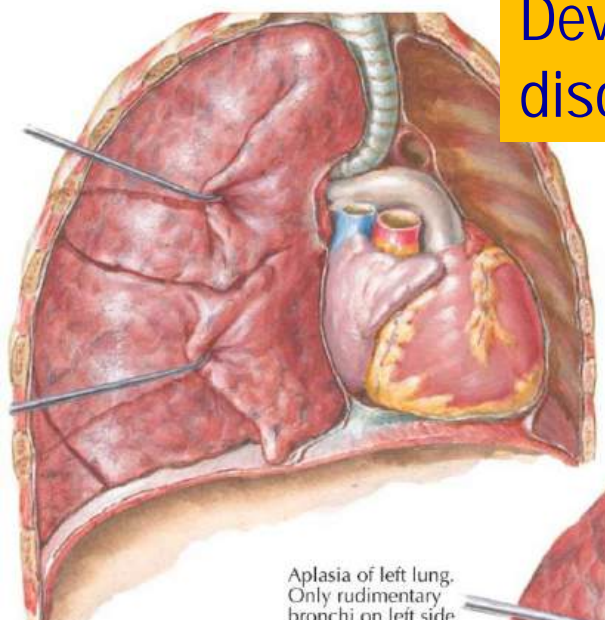


Kyphoscoliosis



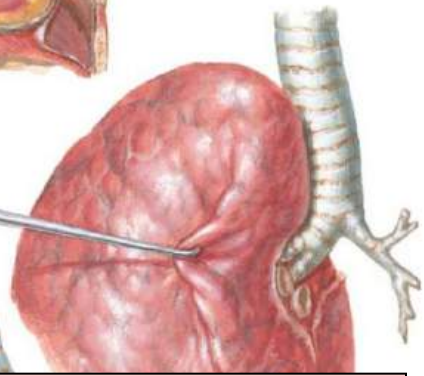
Verbal description during the lecture.

Developmental disorders



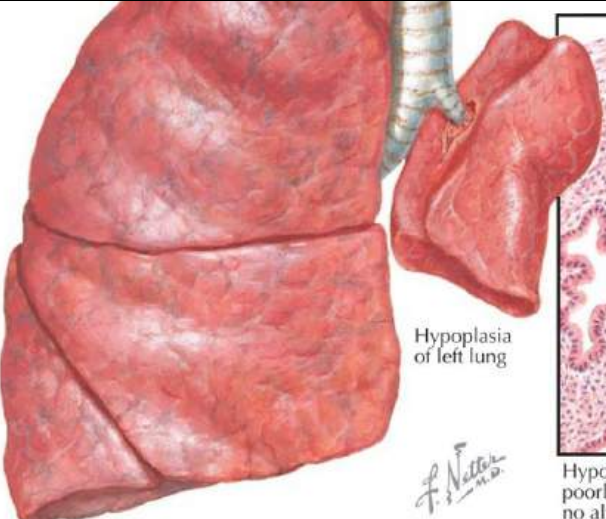
bronchial tree are absent. Right lung is greatly enlarged with resultant shift of mediastinum to left, elevation of left diaphragm, and approximation of ribs on that side

Aplasia of left lung. Only rudimentary bronchi on left side, which end blindly

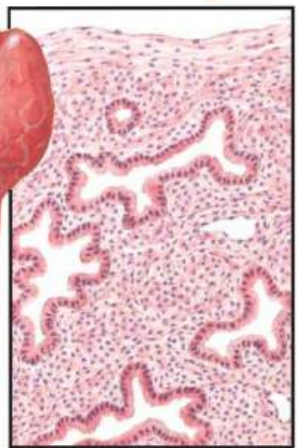

Pulmonary agenesis

Verbal description during the lecture.

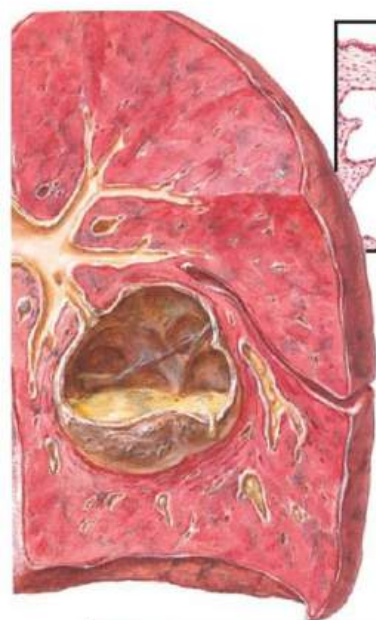

Hypoplasia of left lung

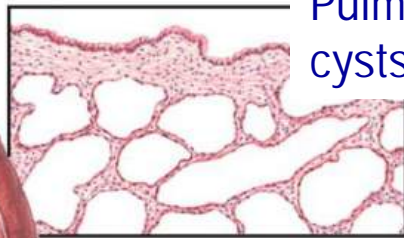


Hypoplastic lung contains some poorly developed bronchi but no alveolar tissue

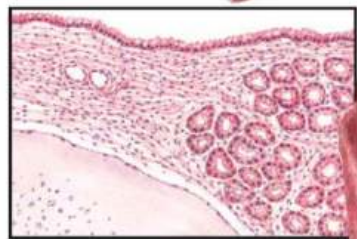F. Netter M.D.



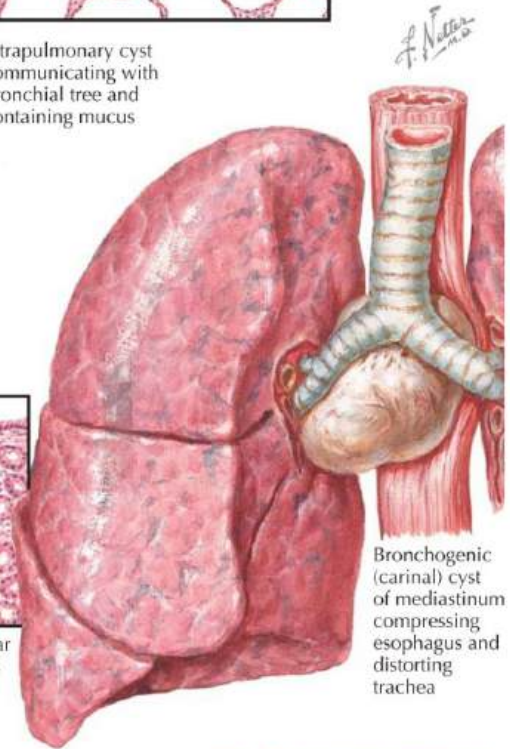
Intrapulmonary cyst communicating with bronchial tree and containing mucus



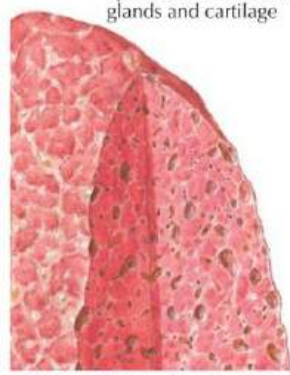cuboidal epithelium of bronchial type



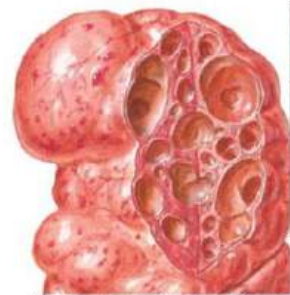Cyst wall lined by ciliated columnar epithelium and containing mucous glands and cartilage



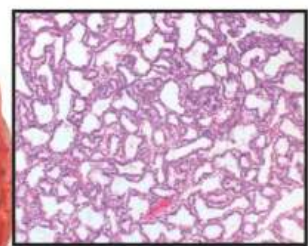
Bronchogenic (carinal) cyst of mediastinum compressing esophagus and distorting trachea



Congenital lymphangiectasis



Cystic adenomatous malformation of upper lobe of a lung



Congenital cystic adenomatous malformation of the lung, type 3. Irregular, small airspaces lined by cuboidal epithelium.

F. Netter M.D.

Pulmonary fibrosis

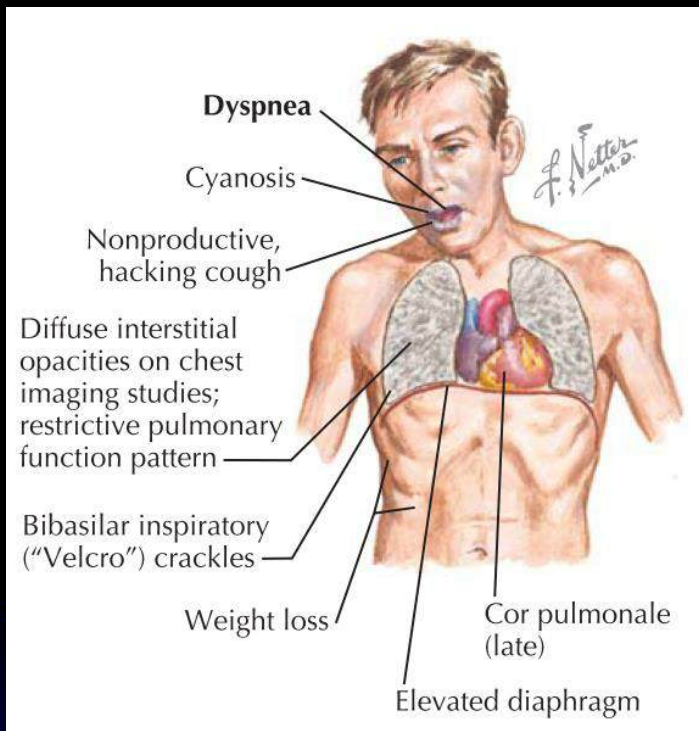
- **Definition:** Pulmonary Fibrosis is a form of interstitial lung disease (ILD) characterized by **chronic, progressive scarring of the lung parenchyma** = "stiff" tissue. As the scar thickens, it becomes increasingly difficult for oxygen to pass through the alveolar walls into the bloodstream. Balloon-like air sacs (alveoli) are replaced by thick, tough scar tissue, making the lungs lose their elasticity.
- **Epidemiology** Idiopathic Pulmonary Fibrosis (IPF): The most common form; 50 - 70 years old. men, Incidence: It is relatively rare but has a high mortality rate; the median survival for IPF (without treatment) is often cited as 3–5 years post-diagnosis.
- **Etiology:** According to the insult:
 - **Environmental/Occupational:** Long-term exposure to silica dust (silicosis), asbestos (asbestosis), coal dust, or bird droppings (hypersensitivity pneumonitis).
 - **Medical Treatments:** Certain medications (e.g., Amiodarone, Methotrexate, Bleomycin) or radiation therapy to the chest.
 - **Autoimmune Diseases:** Rheumatoid arthritis, Scleroderma, or Systemic Lupus Erythematosus (SLE).
 - **Idiopathic:** In many cases, the cause is completely unknown (IPF).

Pulmonary fibrosis

- **Pathogenesis:** from "pure inflammation" to a wound-healing gone wrong model:
 - Repeated Micro-injury: Tiny injuries occur to the alveolar epithelial cells (due to smoking, pollutants, or unknown triggers).
 - Abnormal Repair: Instead of healing cleanly, the body over-activates fibroblasts (cells that make connective tissue).
 - Extracellular Matrix Deposition: Excessive collagen is dumped into the alveolar walls.
 - Remodeling: The lung architecture is destroyed, leading to "honeycombing"—clusters of cystic spaces that don't participate in gas exchange.
- **Manifestations:** The symptoms are often subtle at first, leading to delayed diagnosis.
 - Progressive Dyspnea: Shortness of breath that starts with exertion but eventually occurs at rest.
 - Dry, Non-productive Cough: A persistent "hacking" cough that doesn't bring up mucus.
 - Physical Exam Signs:
 - "Velcro" Crackles: Fine, dry inspiratory crackles heard at the lung bases (sounds like pulling apart Velcro).
 - Digital Clubbing: Bulbous enlargement of the fingertips (seen in 25–50% of IPF patients).
 - Cyanosis: A bluish tint to the skin/lips in advanced stages due to low oxygen (SpO_2).

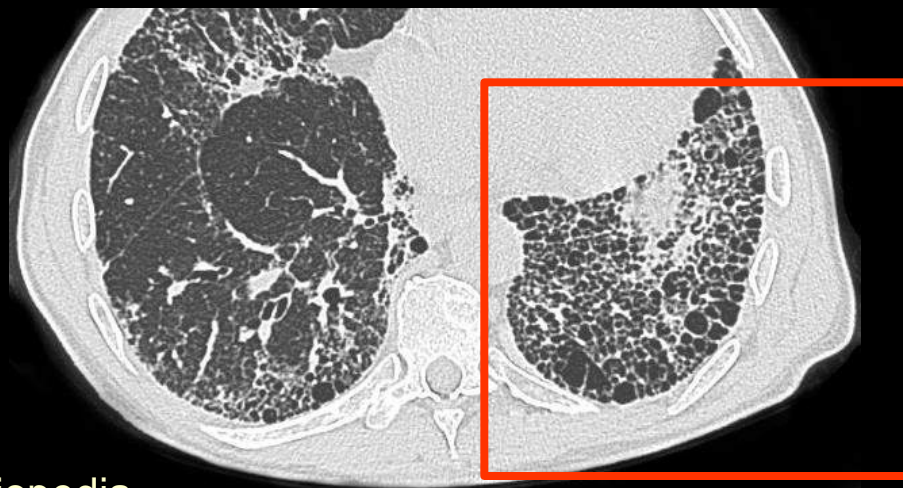
Idiopathic pulmonary fibrosis

Manifestation of ILF



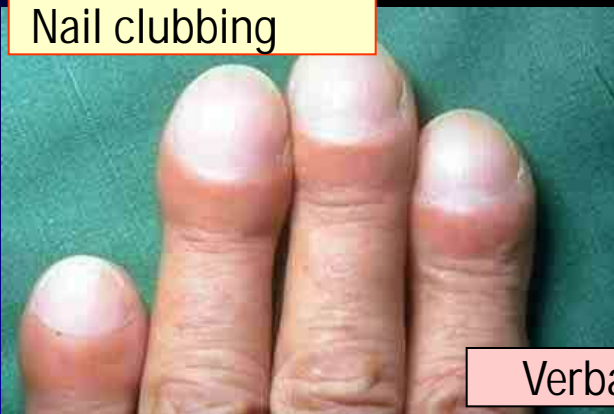Honeycombing in ILF

small adjacent subpleural cystic structures (destruction of lung parenchyma and loss of architecture)



Radiopedia

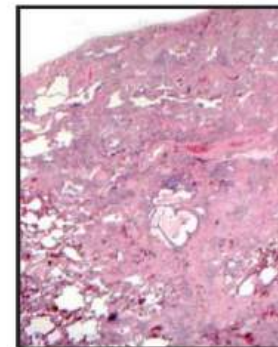
Nail clubbing



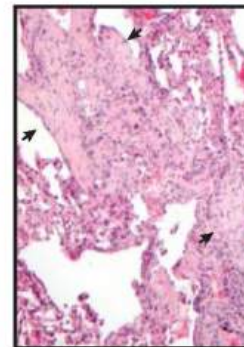
Verbal description during the lecture.



A low-power microscopic view that shows patchy fibrosis with remodeling of the lung architecture and a predominantly subpleural distribution



Patchy, subpleural fibrosis consists of dense collagenous scarring with remodeling of the lung architecture and small cystic changes



The dense collagenous fibrosis is juxtaposed with multiple fibroblast foci (arrows) of loose organizing connective tissue

Pulmonary fibrosis

Laboratory Data & Diagnostics

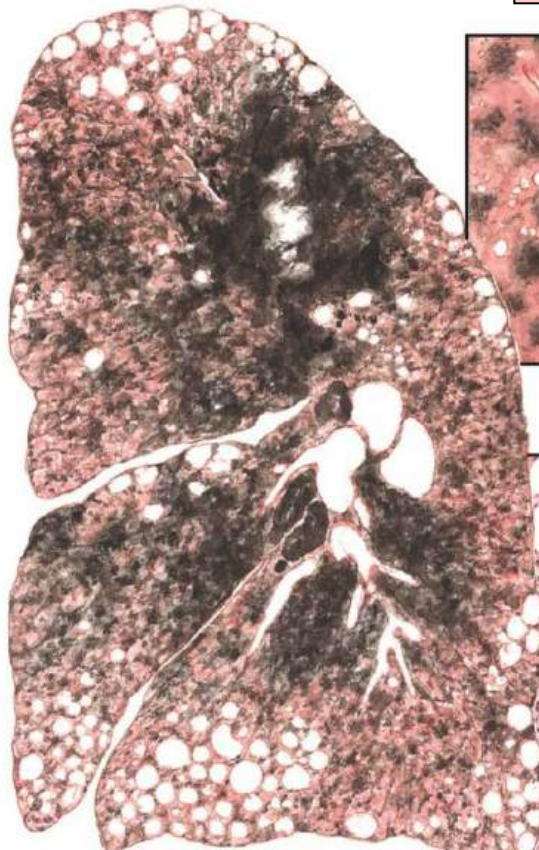
Test	Role	Common Findings
High-Resolution CT (HRCT)	Primary Diagnostic Tool	Honeycombing, "ground-glass" opacities, and reticular (net-like) shadowing.
Spirometry (PFTs)	Assess lung function.	Restrictive Pattern: Low Total Lung Capacity (TLC) and low Forced Vital Capacity (FVC).
DLCO Test	Measure gas exchange.	Decreased Diffusion Capacity (the lung's ability to move oxygen into the blood is impaired).
Pulse Oximetry	Monitor oxygen levels.	Significant desaturation during a 6-minute walk test.
Lung Biopsy	If CT is inconclusive.	Histological pattern of UIP (Usual Interstitial Pneumonia).

Pneumoconiosis

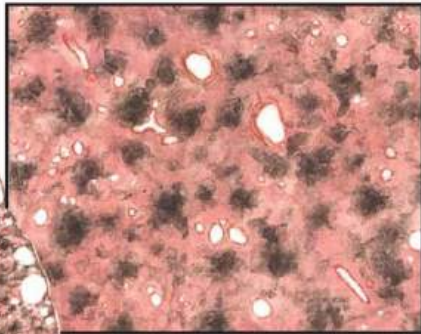
- **Definition:** Pneumoconiosis = general term for a group of interstitial lung diseases caused by the inhalation of mineral (inorganic) or organic dust particles, which are then deposited in the lungs, leading to a tissue reaction (usually inflammation and fibrosis).
- **Epidemiology:** (1) Occupational: workers exposed to specific dusts (miners, sandblasters, construction workers, shipbuilders). public health problem in developing regions; long latency : often 10 – 30 y after the initial exposure.
- **Etiology** Silica: Sandblasting, quarrying, mining, ceramics, and glass making. Asbestos: Shipbuilding, insulation, brake linings, and old building demolition. Coal Dust: Underground coal mining. Beryllium: Aerospace and electronics industries (leads to Berylliosis, which mimics Sarcoidosis).
- **Forms** based on how the lung reacts to the dust:
 - (A) **Fibrotic (The "Aggressive" Forms)** permanent scarring and architectural destruction:
 - Silicosis: Caused by crystalline silica (the most common form).
 - Asbestosis: Caused by asbestos fibers.
 - Coal Worker's Pneumoconiosis (CWP): Also known as "Black Lung."
 - (B) **Non-Fibrotic (The "Benign" Forms)** These cause "dusty" lungs but typically minimal scarring:
 - Siderosis: Iron oxide inhalation (welders).
 - Stannosis: Tin oxide. Baritosis: Barium sulfate.

Coal worker lungs

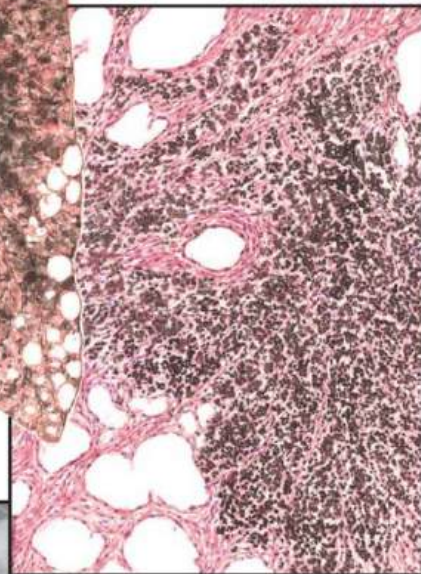
Verbal description during the lecture



Whole-lung thin section shows central "progressive massive fibrosis" with black carbon deposits, numerous smaller nodules, and emphysematous changes

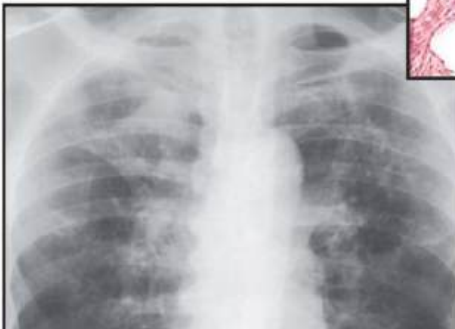

Magnified detail of lung section shows coal dust macules or nodules



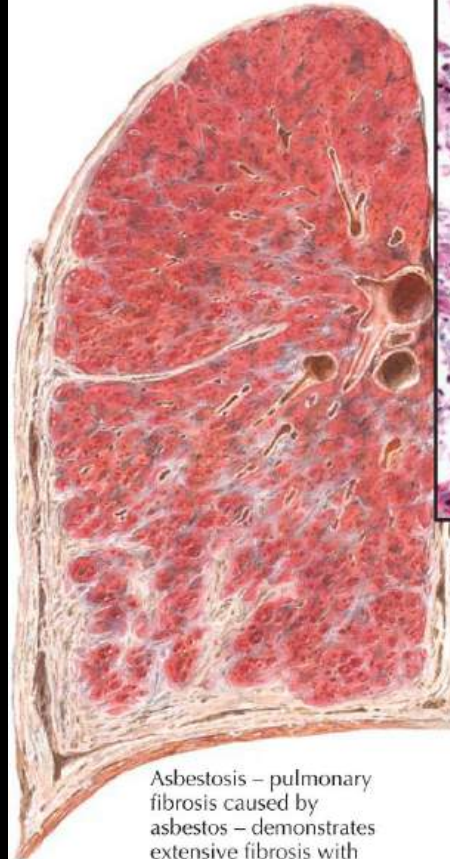
A microscopic section through a coal nodule shows large amounts of black coal dust with interspersed collagen and fibrosis. The nodule surrounds a pulmonary arteriole

F. Netter M.D.



Chest radiograph of a retired coal miner showing massive upper lobe lesions.

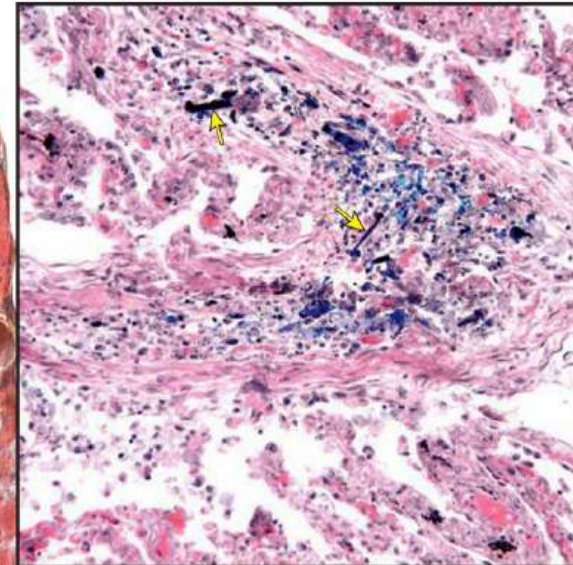
Asbestosis



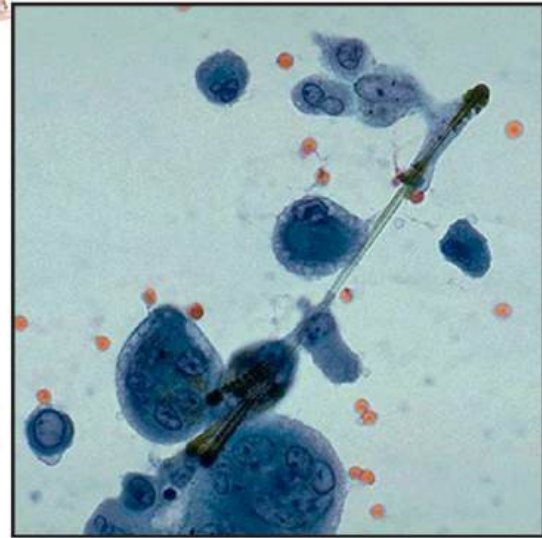
Asbestosis - pulmonary fibrosis caused by asbestos - demonstrates extensive fibrosis with a lower lung zone predominance and diffuse thickening of both the visceral and parietal pleurae

F. Netter M.D.

Sputum shows an "asbestos body" or "ferruginous body", a long thin, straight fiber of an amphibole asbestos decorated with clumps of iron-rich protein material

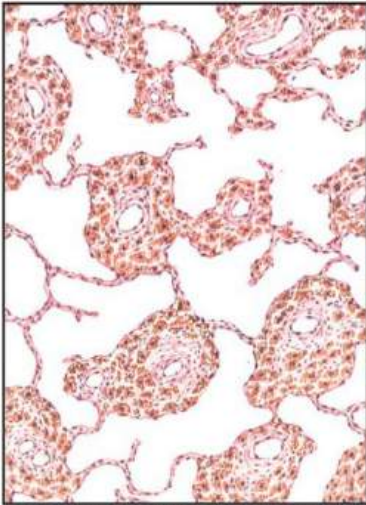


Lung tissue section shows asbestosis, with interstitial fibrosis and dust collections near small airways. Several asbestos fibers and "ferruginous bodies" can be seen (yellow arrows)

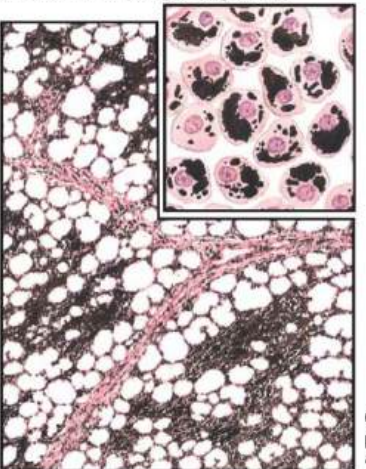


Pneumoconiosis

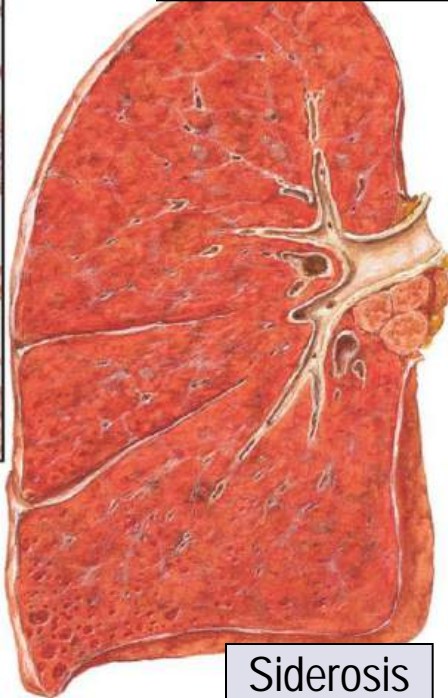
Verbal description during the lecture



Fuller earth pneumoconiosis. "Fuller earth" (montmorillonite, attapulgite, calcium bentonite) is a fine clay used to absorb grease and oils from wool, friction pads, and other materials. Intense exposure during the mining or milling of Fuller earth may cause lung disease, likely caused by quartz and other silicates that contaminate the magnesium. Perivascular accumulations of macrophages laden with dust particles are seen in microscopic lung sections

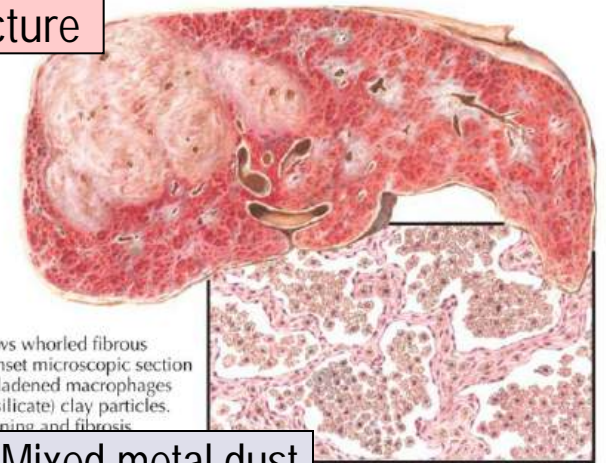


Graphite pneumoconiosis. Black mineral particles pack alveolar macrophages (*inset*) that fill alveoli and coalesce to form dust macules with fibrosis



Kaolinosis

Kaolin pneumoconiosis. Whole-lung cross-section shows whorled fibrous masses and smaller nodules. Inset microscopic section shows alveoli filled with dust-laden macrophages containing kaolin (aluminum silicate) clay particles. There is mild interstitial thickening and fibrosis

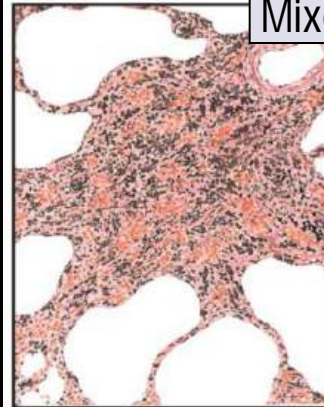


Siderosis

Pulmonary siderosis. Inhalation of iron oxide ore in mining, shipping, and smelting produces accumulation of the dust with brick-red pigmentation of the lung. Mild fibrosis with nodules and mild emphysema may result if the ore contains significant silica or silicates

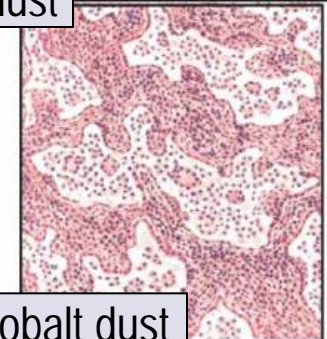
Mixed metal dust

Mixed dust pneumoconiosis. Microscopic section shows fibrosis surrounding deposits of carbon, iron oxide, and silica. These lesions may be found in welders, oxyacetylene torch cutters, sandblasters, and others

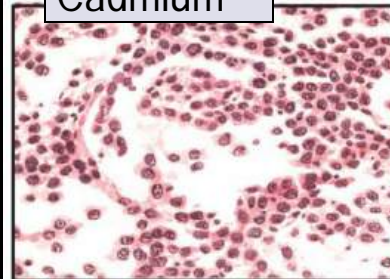

Cobalt dust

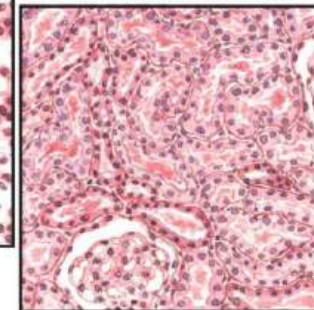
Hard metal disease (cobalt pneumoconiosis). Giant cell interstitial pneumonitis is caused by the immune inflammatory response to cobalt used as a sintering agent for fusing tungsten and carborundum (tungsten carbide) or diamond dust in abrasives



Cadmium



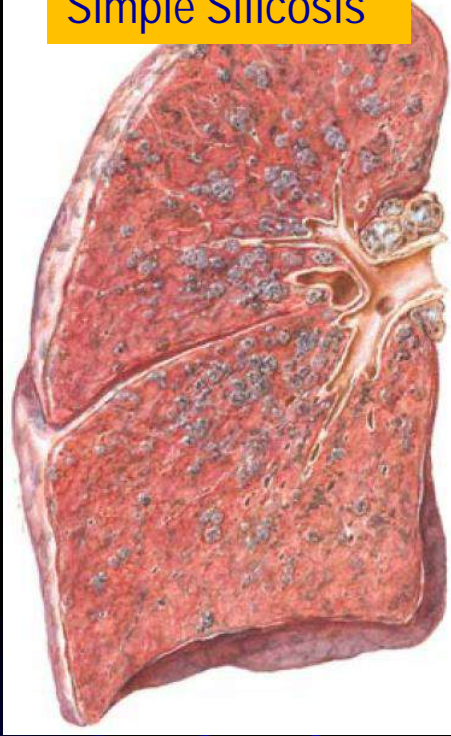
Cadmium injury: The acute effects of cadmium inhalation are seen as injury and metaplasia of the alveolar epithelium



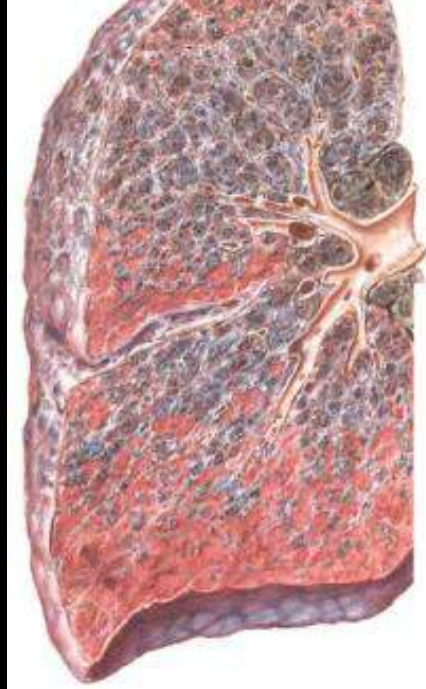
Cadmium injury. Renal effects of chronic cadmium poisoning appear as PAS-positive material clogging the tubules

Pneumoconiosis - Silicosis

Simple Silicosis



Complicated Silicosis



Def.: Silicosis = chronic diffuse fibro nodular interstitial lung disease caused by inhalation of crystalline silica (silicon dioxide; SiO_2) of size 0,2-10 μm).

• Etio: Crystalline silica in form of quartz (beach sand) or mixed in rock dust (granite 10 - 15%) Exposure must be substantial and prolonged !! Glass = (amorphous noncrystalline silica) is essentially nontoxic in crushed, powdered form.

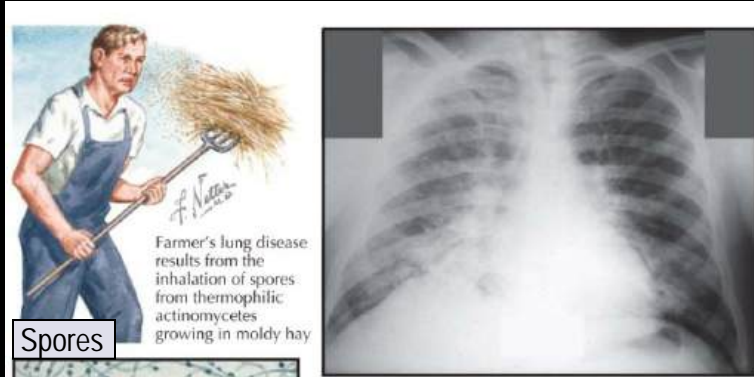
Pathology: Numerous small nodules in upper and mid-lungs

Silica is cytotoxic → damages lysosomes after phagocytosis by macrophages → NLRP3 inflammation → caspase-1 → pro-IL-1 β → IL-1 β , IL-18, TNF- α → central driver of fibrosis IL-1 β TGF- β → fibroblast activation PDGF → fibroblast proliferation Reactive oxygen species (ROS)

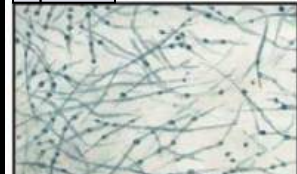


Pneumoconiosis

Farmers lungs

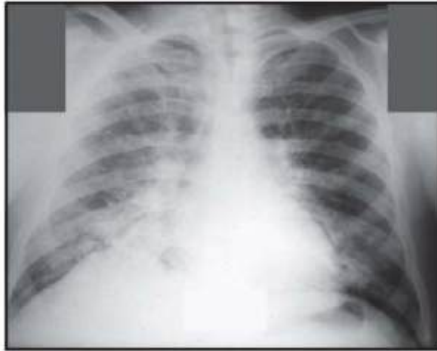


Spores

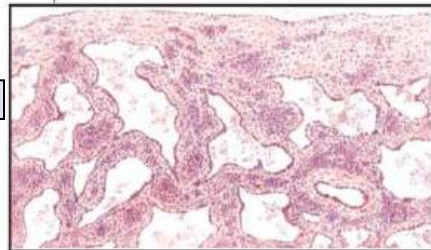


Saccharopolyspora rectivirgula

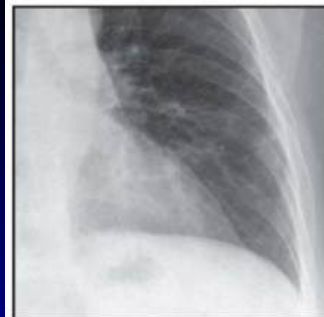Slide culture of *Saccharopolyspora rectivirgula* (formerly *Micropolyspora faenae*), a thermophilic actinomycete bacteria that grows in moldy or decomposing organic material and is the cause of farmer's lung, mushroom picker's lung, and other forms of hypersensitivity pneumonitis



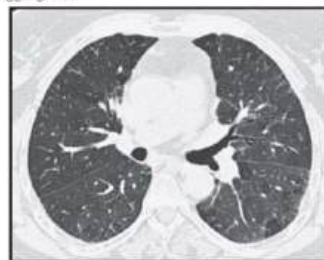Chest radiograph of a dairy farmer 6 hours after exposure to moldy hay shows bilateral patchy ground-glass opacities. Acute shortness of breath, cough, and fever accompanied the response



Chronic hypersensitivity pneumonitis shows extensive subpleural and interstitial fibrosis with inflammatory cell infiltrates and loosely formed granuloma-like cell aggregates



Chest radiograph of a woman with chronic hypersensitivity pneumonitis attributed to household basement mold exposure shows patchy left lower lobe opacities

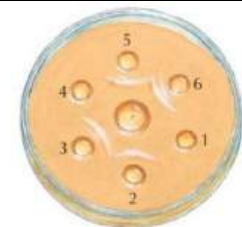


CT scan shows patchy ground-glass opacities, particularly in the left lower lobe, with a mosaic pattern and scattered subpleural linear opacities

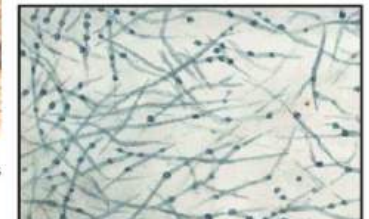Hypersensitive pneumonitis



Bagassosis is a form of hypersensitivity pneumonitis caused by inhaling spores from thermophilic organisms that grow in moldy bagasse, the dried leaves and chaff from sugar cane. Bagasse is used to make wall board, paper, and containers or is burned for fuel. It is not the fresh cane material that causes the disease, but the bacteria, such as *Thermoactinomyces sacchari*, growing in it

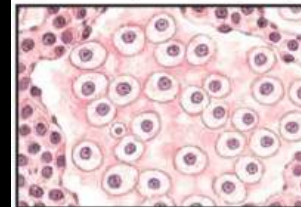


Precipitin reactions in bagassosis: The patient's serum is in the central well, and extracts of bagasse from various sources are in the peripheral wells. Samples 1 and 4 from fresh bagasse show no reactions, but other samples from moldy bagasse show lines of antigen-antibody precipitation

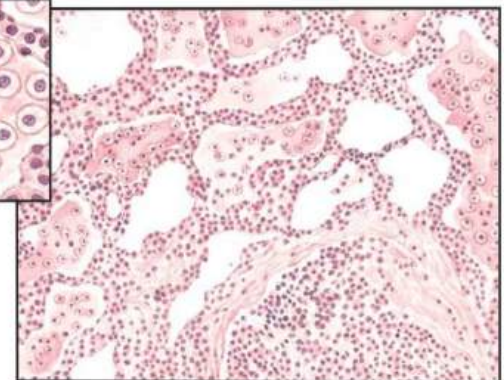


Thermoactinomyces

sacchari, the principal cause of bagassosis

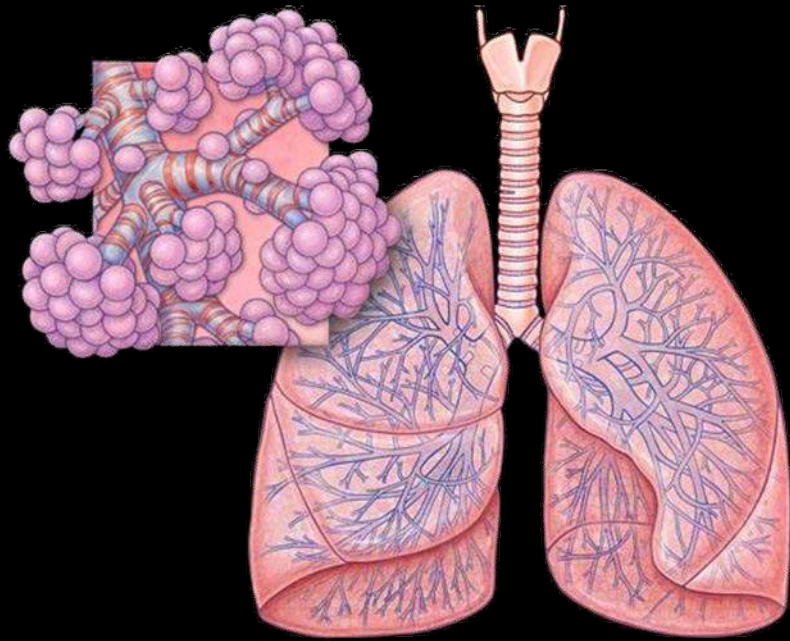


Higher power inset shows macrophages with vacuolated cytoplasm filling the alveolar spaces



In acute bagassosis, the alveolar walls are thickened with an infiltrate of plasma cells and lymphocytes; edema fluid and desquamated alveolar epithelial cells fill the airspaces

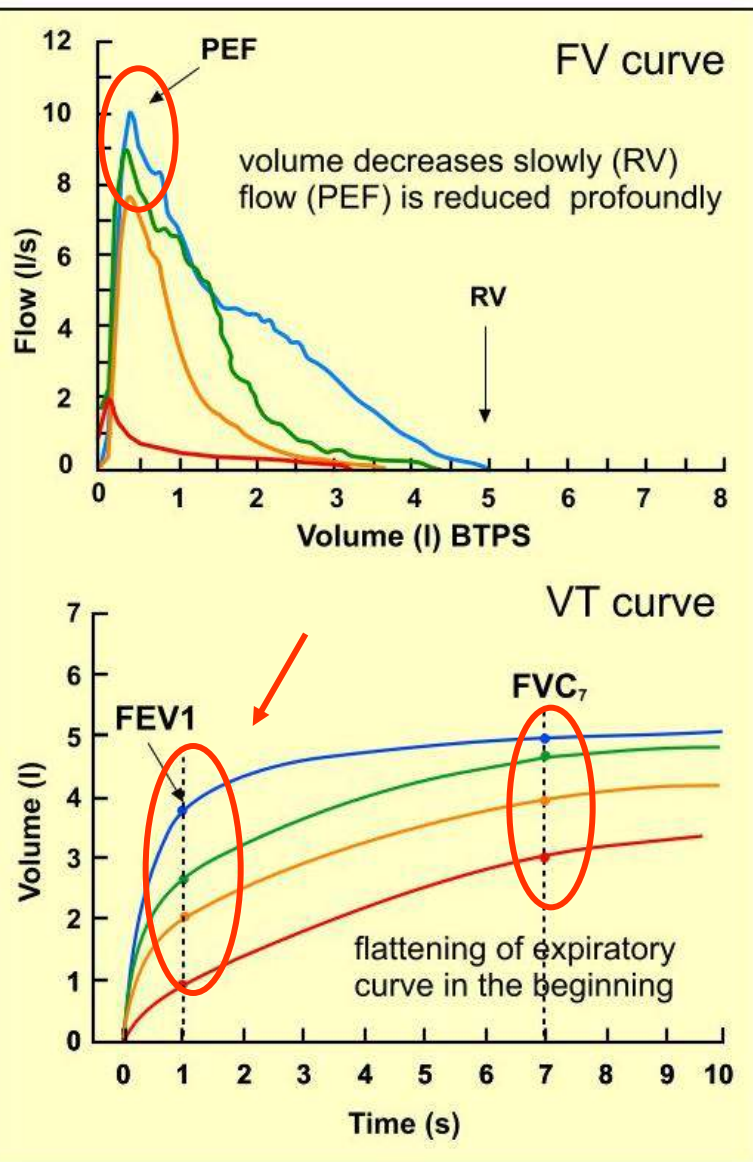
Verbal description during the lecture



Obstructive disorders

Examples

Findings in obstructive diseases



1. Dynamic Spirometry (Main findings)

- ↓ FEV1 (Forced Expiratory Volume in 1s): < 80% N or later ↓ VC (Vital Capacity)
- ↓ FEV1/VC (or FEV1/FVC) (< 0.70 or < LLN) hallmark
- ↓↓ MEF (FEF 25-75): „obstruction of small airways“

2. Static Lung Volumes ("Inflation" problem)

- ↑RV (Residual Volume): air remains "trapped" in the lungs
- ↑FRC (Functional Residual Capacity): "resting" volume
- N or ↑ TLC (Total Lung Capacity): > 120%, (emphysema).

3. Mechanics and Resistance

- ↑ Raw (Airway Resistance) plethysmography
- N or ↑ Compliance (C): "springiness" (elasticity) (N: Asthma/ Bronchitis; ↑ Emphysema)

4. Other

- ↓ / N DLCO (Diffusing Capacity) N/↑ in Asthma:
- ↓ Conductance (inverse of resistance = 1/Raw)

Patients with obstructive disorders

According to *American Thoracic Society; Am.J.Respir.Crit.Care Med.* 1995; 152: S77-121

Airflow obstruction

**Chronic bronchitis
(asymptomatic – early)**

COPD (most common)

**Asthmatic bronchitis
asthma + components of
Bronchitis, emphysema**

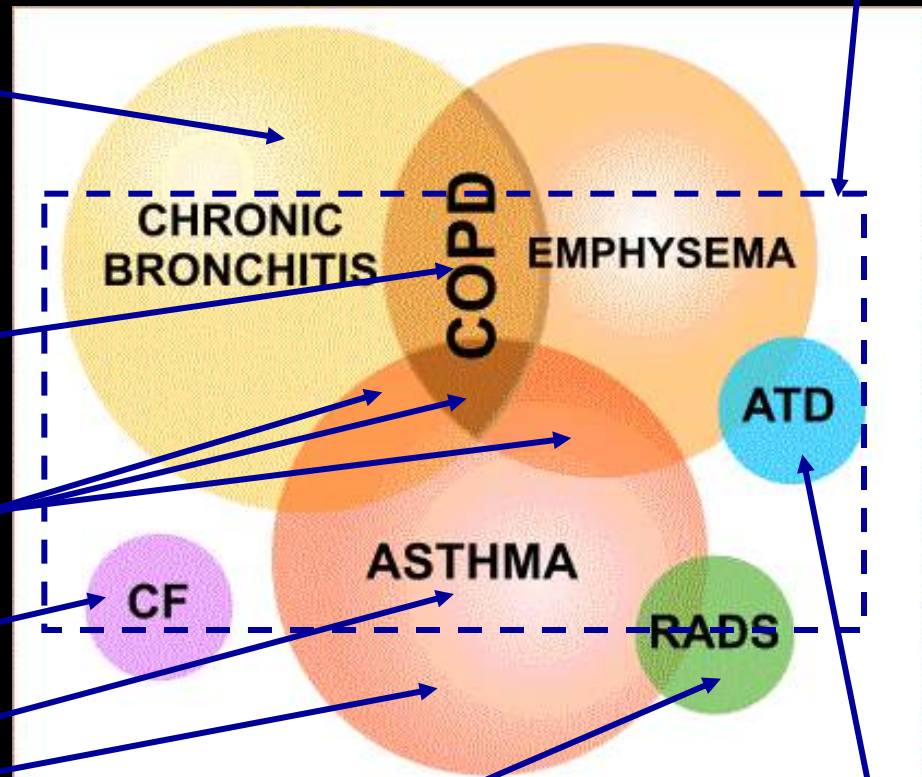
Cystic fibrosis

Reversible asthma

Spastic bronchitis

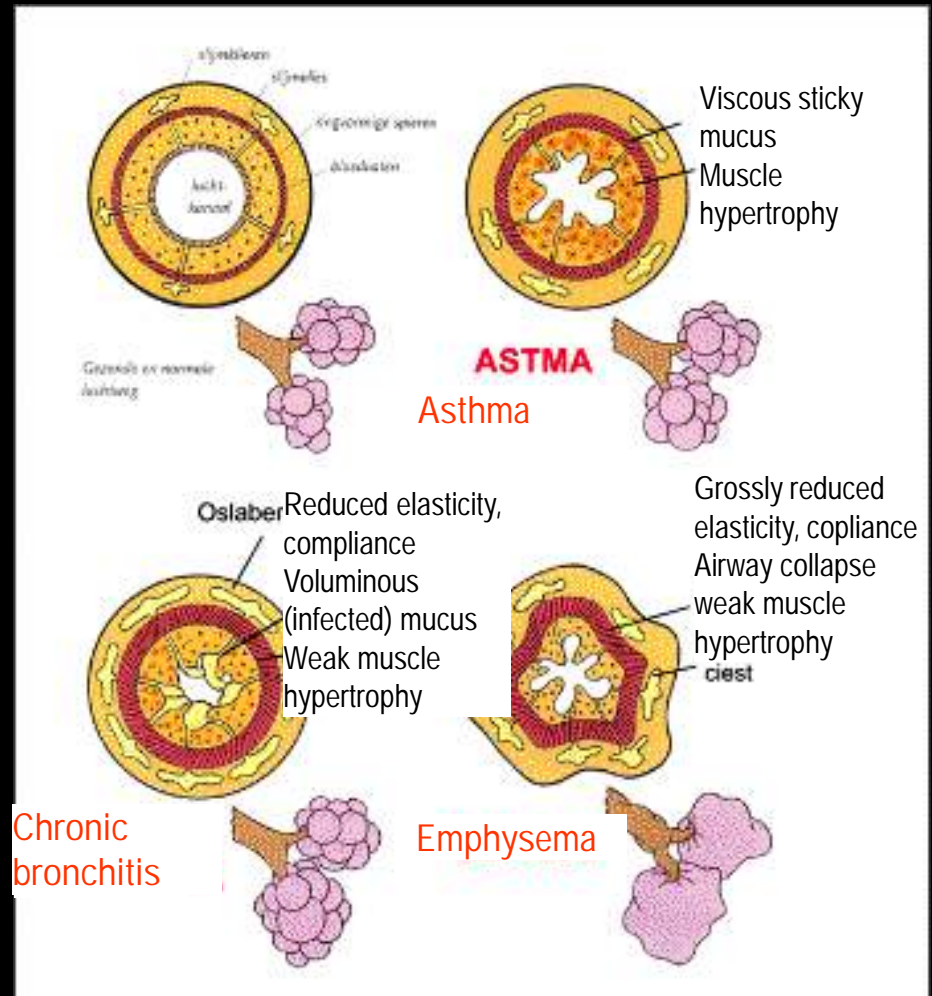
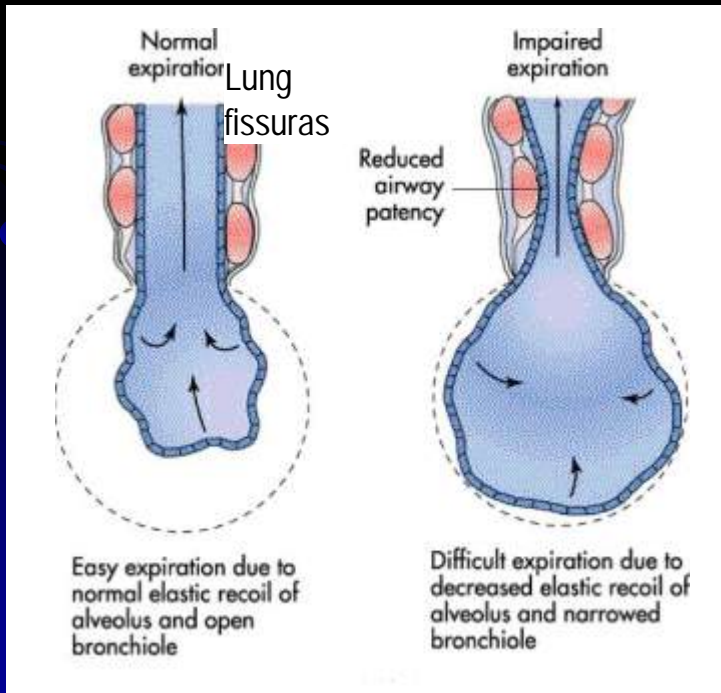
Reactive airways syndrome

**Alpha- antitrypsin deficiency
(familial emphysema)**




Pathogenesis of obstructive diseases

- Hyperplasia, metaplasia of mucous layer (chronic bronchitis; most disorders)
- Hyperproduction of mucus – voluminous (chronic bronchitis, bronchiectasia); viscous (asthma), etc.)
- Inflammatory exudate – Leu, Neu, Mo, Eo (asthma)
- Thickening of muscle layer – spasms (asthma)
- Airway collapsibility – **air-trapping**; expiratory limitation (various methods in all cases)



Verbal description during the lecture.

Air trapping



ASTHMA

Asthma

■ **Definition:** Chronic inflammatory disease of bronchi leading to spasmodic occlusion and hyperproduction of viscous mucus

■ **Causes:** a) **Allergic – type I, type III** (allergens, infections) most often affects children and young adults; allergic rhinitis, conjunctivitis, or eczema is common in response to environmental and occupational allergens elevated IgE levels. history of

b) **Non- allergic (neurogenic)** psychogenic, neurogenic reasons (ANS) or infection (respiratory tract i (Chlamydia pneumoniae; Mycoplasma spp.), comorbidities, chronic sinusitis, obesity, gastroesophageal reflux etc.

■ **Pathomechanism:**

■ Mucosal hypertrophy - hyperplasia of mucus producing cells ; Overproduction of very viscous mucus

■ Hypertrophy of smooth muscles – narrowing of the lumen

■ **Asthmatic crisis:**

■ **Dyspnoea** - difficulty of breathing, wheezing, catching for air

■ **Cough** - difficult expectoration, viscous mucus

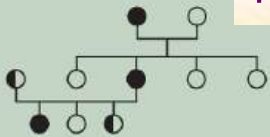
■ **Cyanosis** - blue – coloring of face

ALLERGIC ASTHMA: CLINICAL FEATURES

Young patient: child or teenager

Heredity

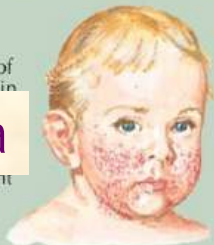Family history usually positive



History of eczema in

Eczema

may be present



Attacks related to specific antigens



Pollens



Foods



Allergens



IgE, Eo

Skin test results usually positive



Drugs




Dusts



Danders

Prick tests

Child Teenager



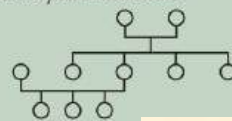
ALLERGIC ASTHMA

NONALLERGIC ASTHMA: CLINICAL FEATURES

Adult patient: age 35 years and older

No heredity

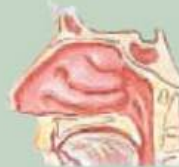Family history usually negative



History of eczema in childhood



Attacks related to infections, exercise, other stimuli



Chemicals

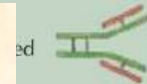

Infection

usually negative



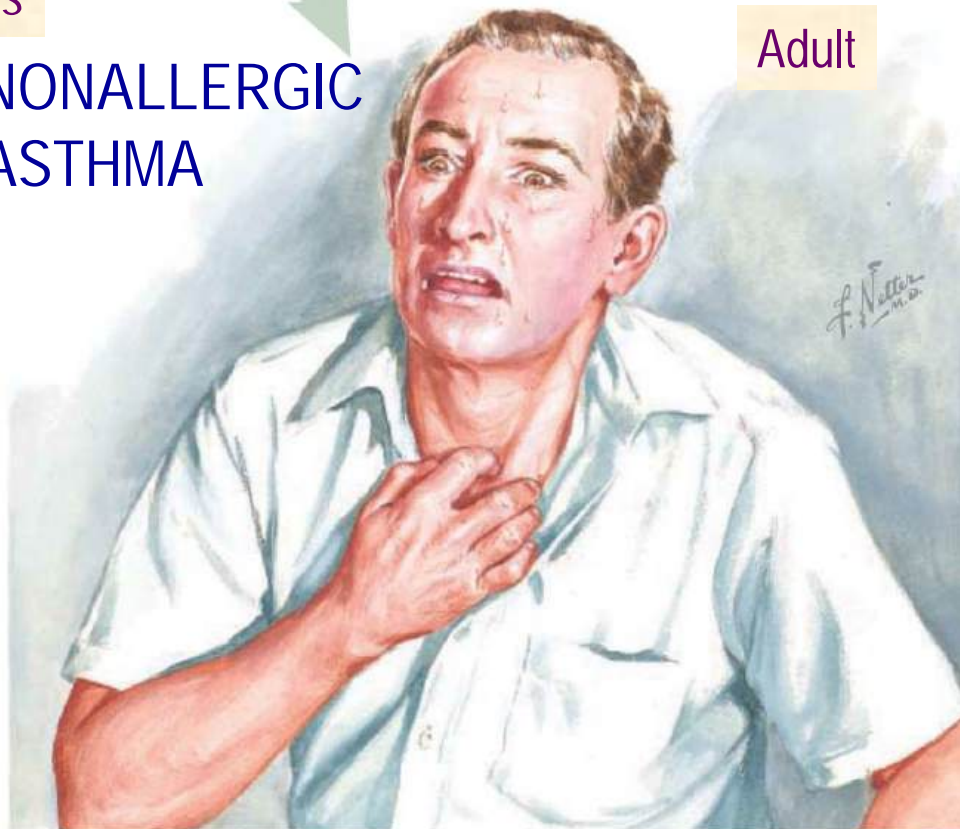No IgE



Consider occupational asthma as a cause

Adult

NONALLERGIC ASTHMA



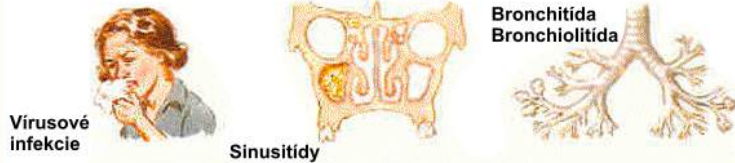
Asthma pathogenesis

Inducers - Triggers

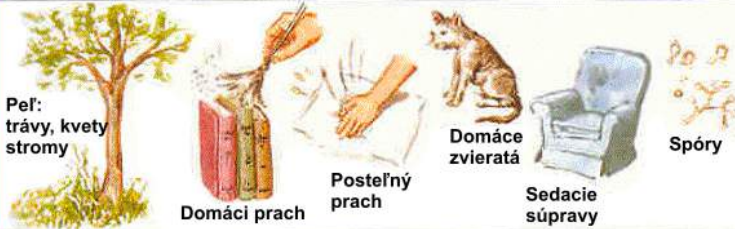
- **Aspirin Sensitivity** - triad of aspirin sensitivity, asthma, and nasal polyposis (Samter triad) in 5%; 20 min of ingestion of Asp (all cyclo-oxygenase (COX-1) inhibitors) ; very severe and occasionally life threatening. Acetaminophen and COX-2 inhibitors appear to be safe
- **Occupational asthma** - common; more than 200 agents in the workplaces (animal dander, wheat flour, psyllium, and enzymes, toluene diisocyanate), via IgE and non-IgE-mediated mechanisms.
- **Exercise** very common bronchoconstriction after exercise (10 - 20 min after the end of exertion; resolves within 1 h). by the cooling and drying of the airways. prevented by pretreatment with inhaled β_2 -agonists 5 - 10 min before exercise.
- **Atmospheric pollutants** - variety are asthma inciters; nitrogen dioxide (NO₂), sulfur dioxide;
- **Environmental allergens** - 10 to 15 min after allergen inhalation, which usually resolves with 2 hours ; bronchoconstriction can recur between 3 to 6 h later more slowly (late asthmatic response) and resolves within 24 h, but patients are left with increased airway responsiveness, which may persist for more than 1 week.
- **Viral infections** are important inducers of asthma in the first decade of life; exacerbations (particularly rhinovirus); and inducing changes in airway physiology, including increasing airway responsiveness.

Irritants

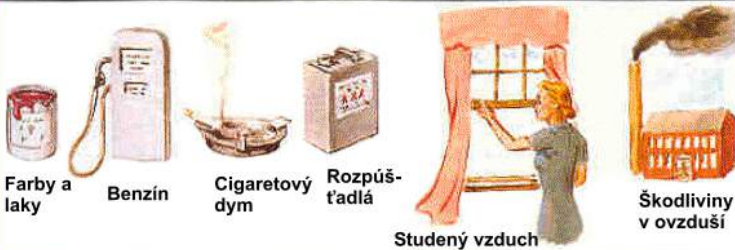
A. Infekcie



B. Inhalačné alergény




C. Irítanty



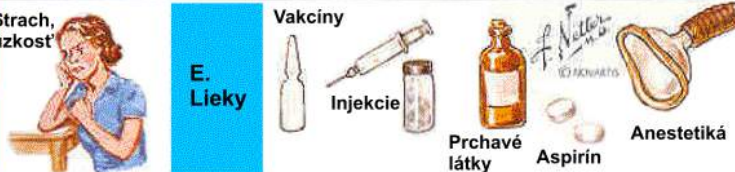
D. Alergény potravy



E. Sekundárne



F. Psychika



Allergens – organic origin, proteins 3–4 kDa (inhalant allergens – pollen, dust, spores, dander, food) Infections – viral, bacterial, fungal, actinomycetes (community-acquired pneumonia, rhinopharyngitis, acute bronchitis, recurrent chronic bronchitis, pneumonia);

Allergic diseases – seasonal rhinitis (hay fever), perennial rhinitis, allergic rhinosinusitis, nasal polyps + Type I allergies (eczema, urticaria)

Irritants – smoke, toluene, diisocyanates, textile dust, sawdust, fumes, gasoline, proteolytic enzymes (detergents), Bacillus subtilis, nickel salts, SO₂, flour, chromium, etc.; approximately 400 substances)

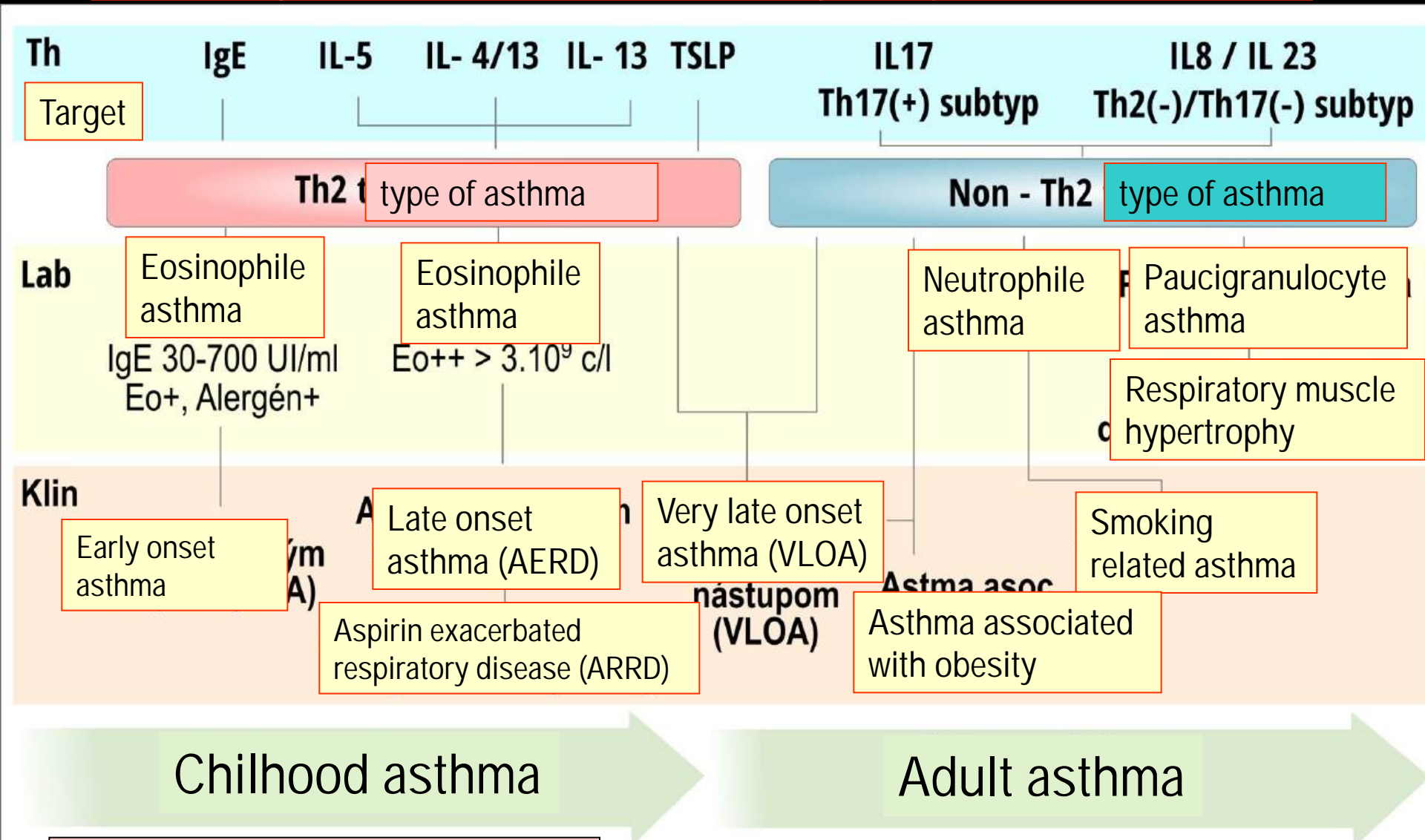
Medications – PNC, aspirin (2–20%), indomethacin, vasopressin, β-blockers, acetylcholine, non-narcotic analgesics, iodides

Physical – cold air, cold-heat, humidity, wind

Psychogenic factors – anxiety, stress, chronic fatigue syndrome, physical overwork

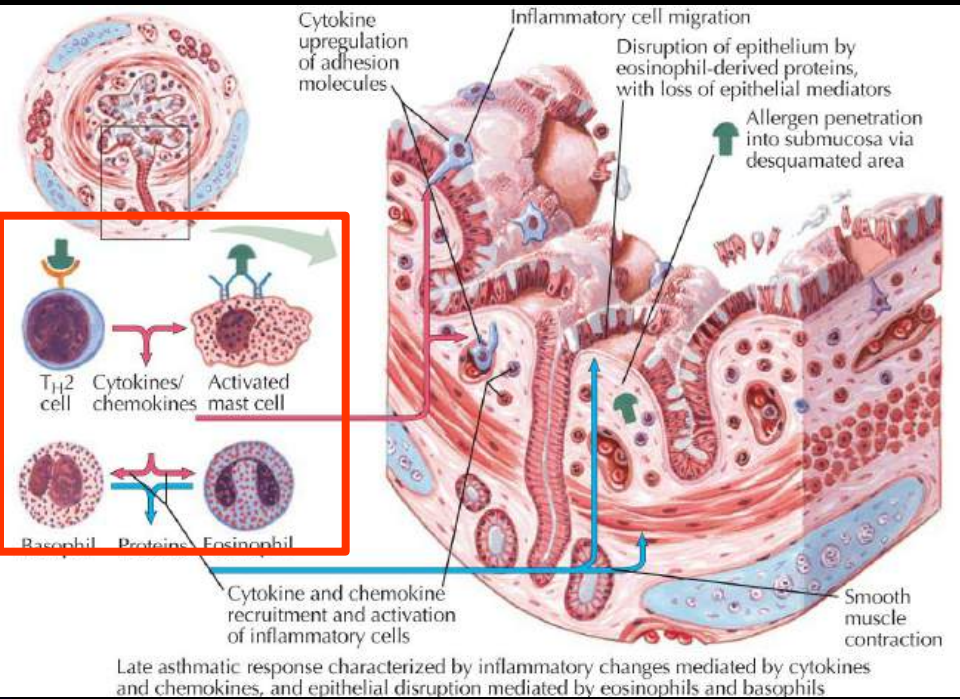
Phenotypes of asthma

Asthma as a group of disorders with different pathogenesis yet similar manifestations

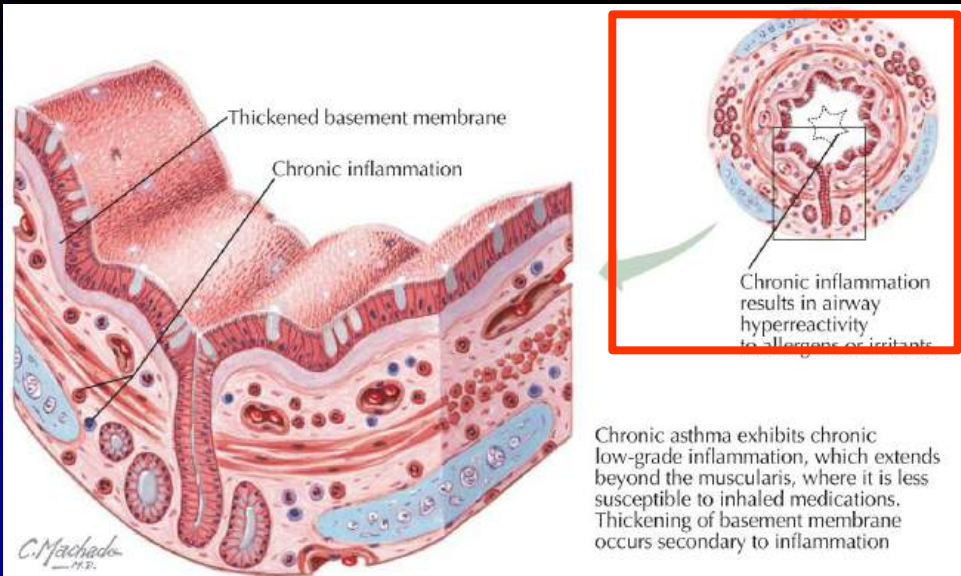
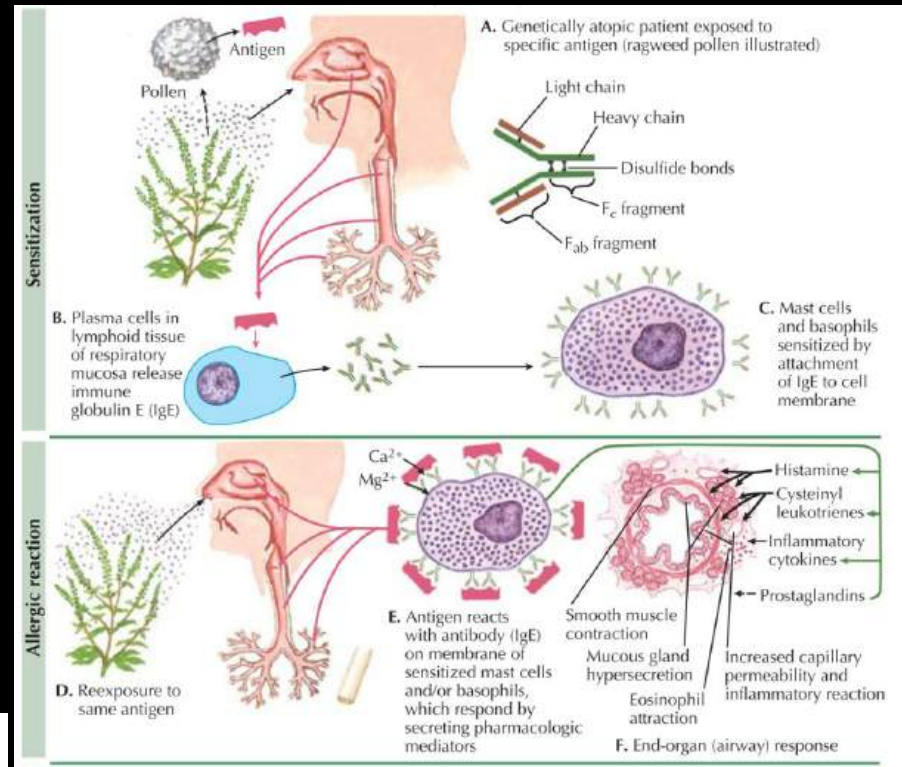


Verbal description during the lecture.

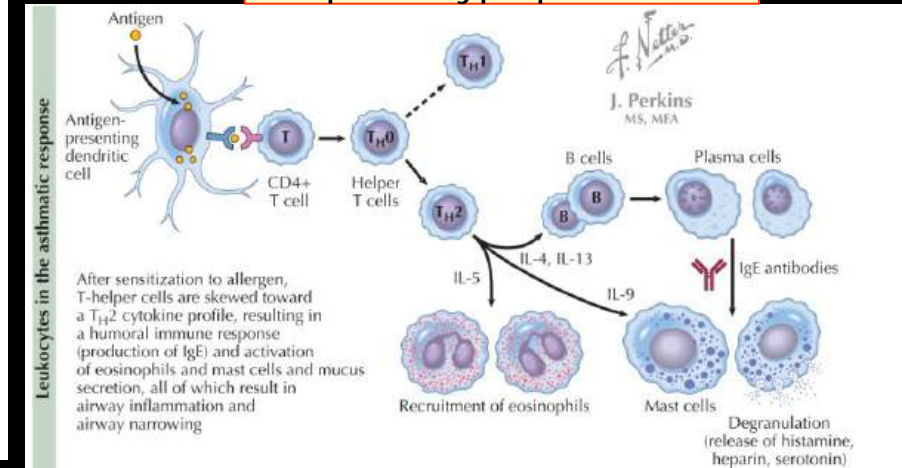
Th2 phenotype preference



Type I hypersensitivity

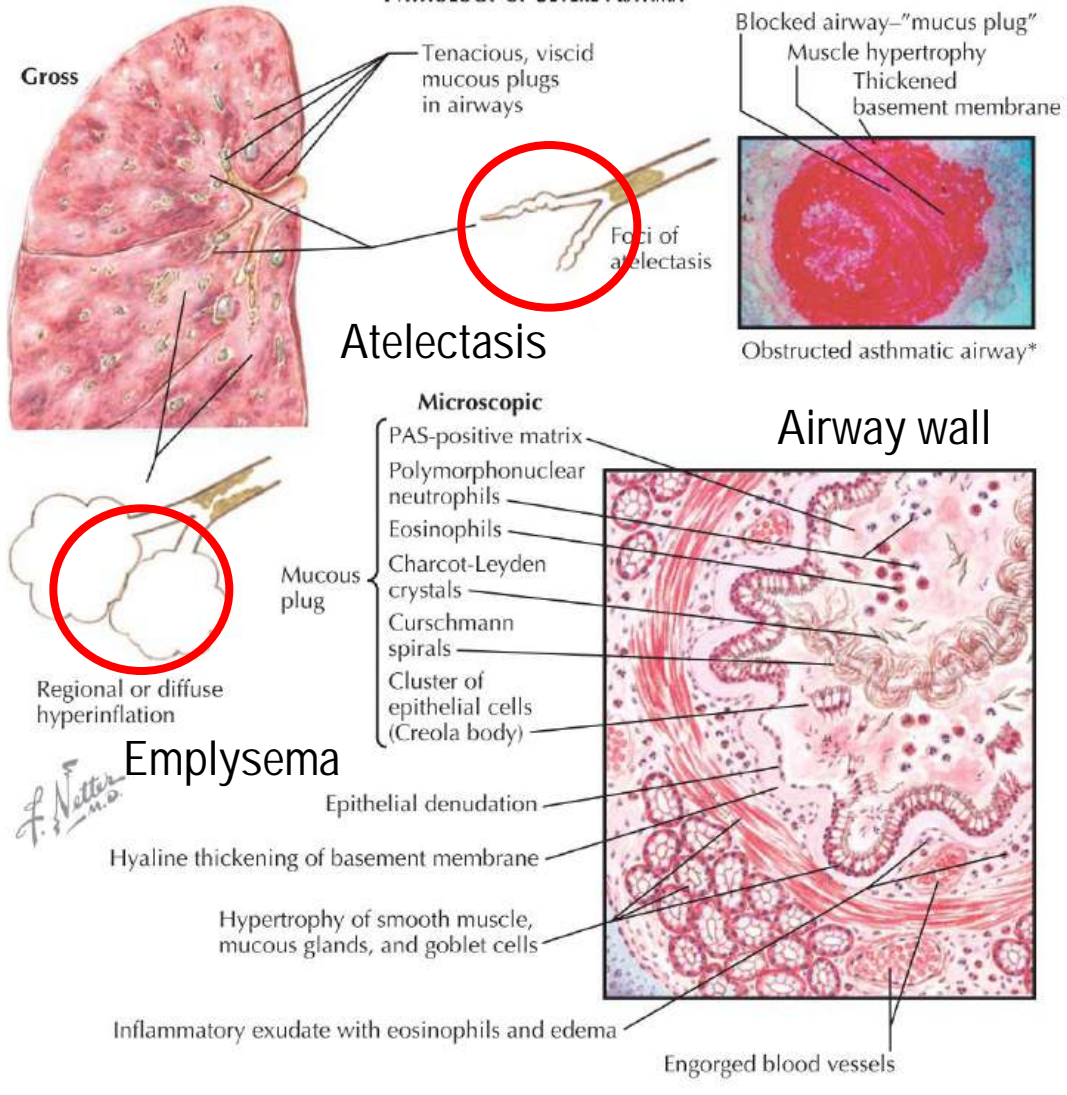


Th2 phenotype preference

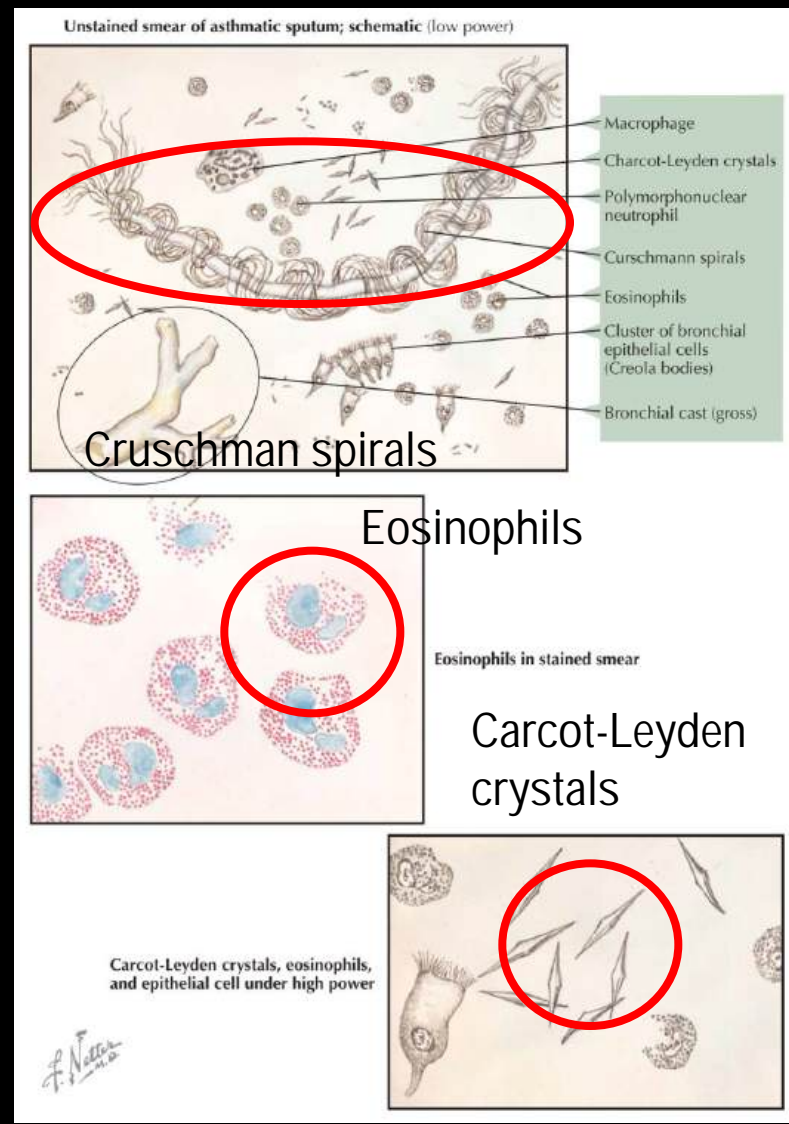


Long-duration asthma findings

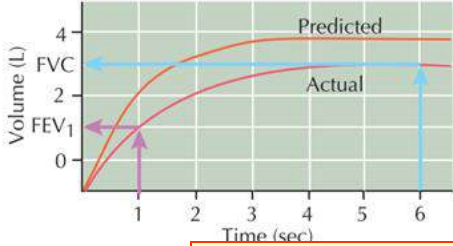
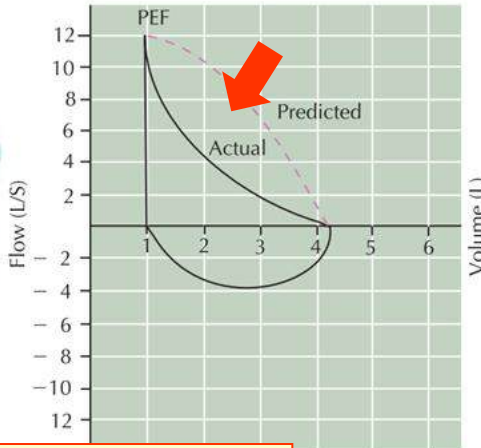
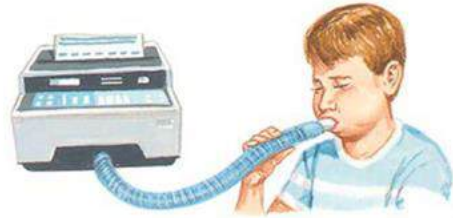Airway alterations



Specific sputum content



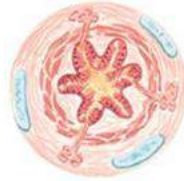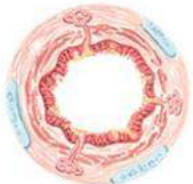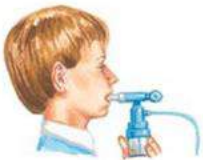Spirometry findings



Provocation metacholine test

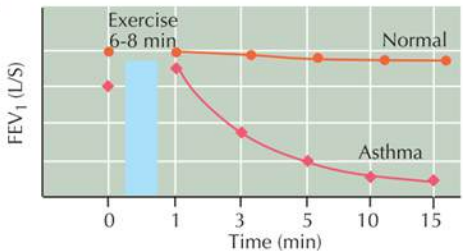
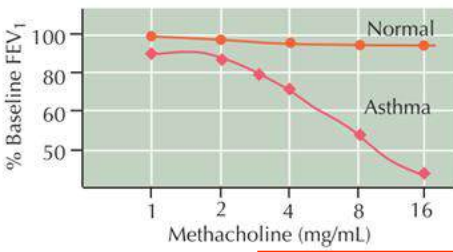
Baseline

Bronchoconstriction



Inhalation of nebulized methacholine at increasing doses. Each dose is followed by spirometry. Fall in FEV₁ by $\geq 20\%$ from baseline at a concentration of $\leq 8\text{mg/mL}$ is a positive response

Exercise at 85% of predicted maximal heart rate or 80% of MVV for 6-8 minutes. Spirometry measured at baseline and at 5-minute intervals after exercise. Positive challenge is a fall in FEV₁ by $\geq 15\%$ from baseline



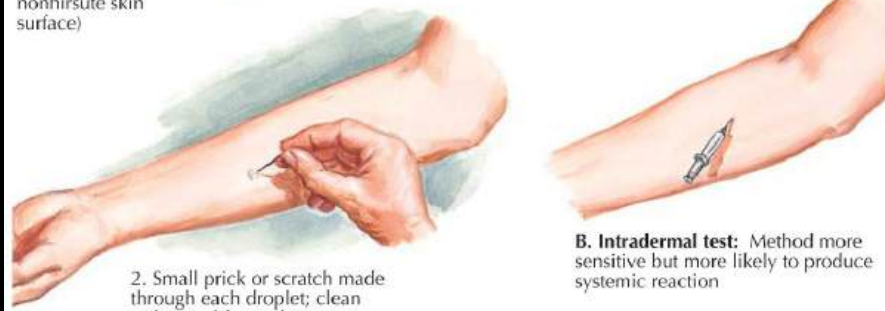
6-8 min submaximal exercise
 \downarrow FEV₁ > 15%

Skin testing for sensitizers

SKIN TESTING FOR ALLERGY



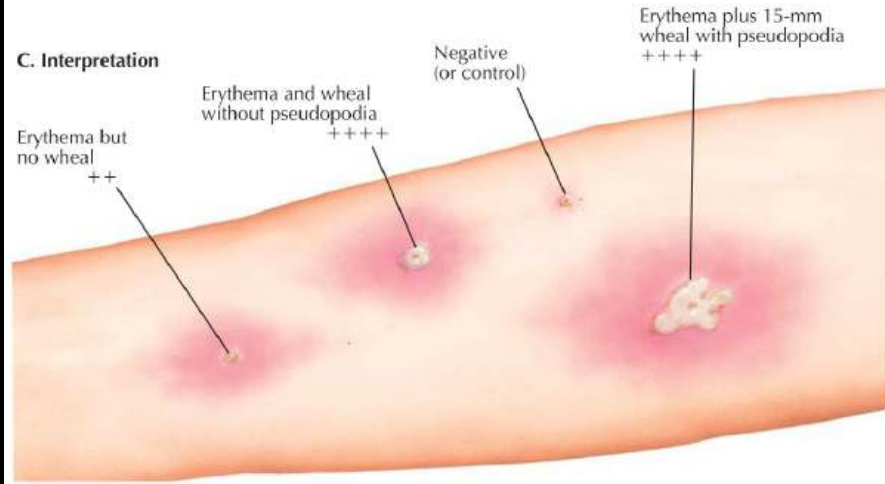
A. Scratch test:
 1. Single drops of control and suspected antigens applied to volar surface of forearm (or other nonhirsute skin surface)



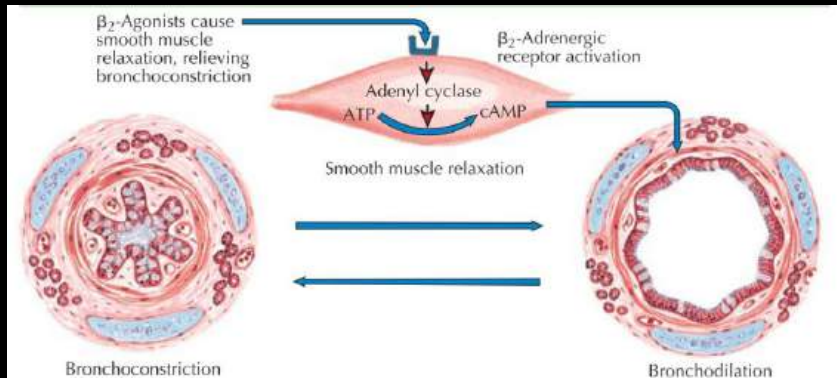
2. Small prick or scratch made through each droplet; clean stylet used for each

B. Intradermal test: Method more sensitive but more likely to produce systemic reaction

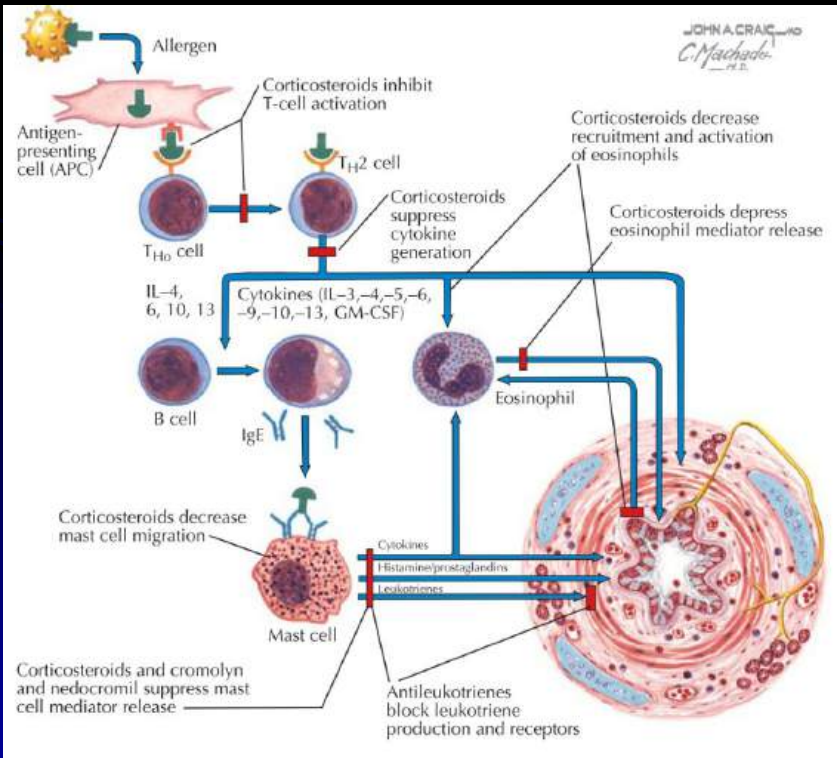
C. Interpretation



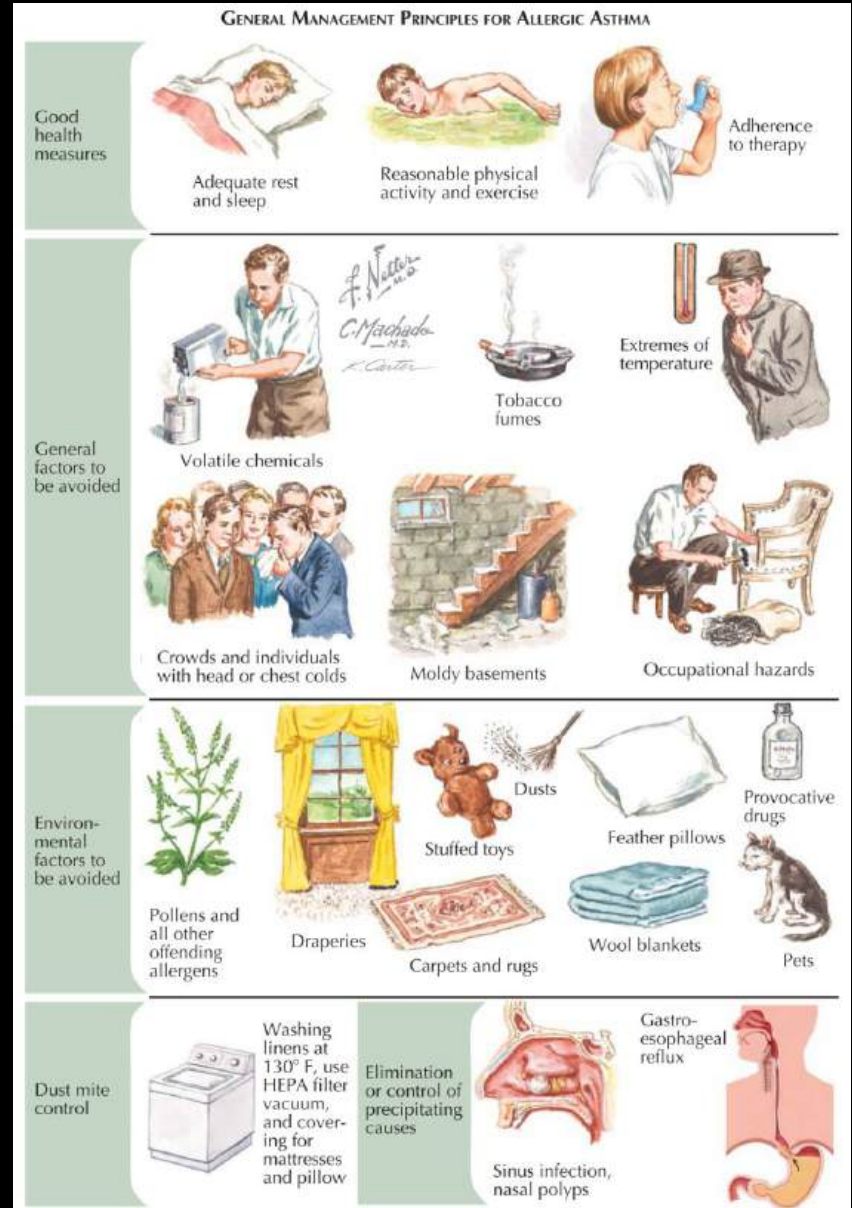
Beta2 mimetics




Corticosteroids



Verbal description during the lecture.





COPD

COPD

- **Def.:** Progressive disease state characterized by the presence of airflow obstruction, hypoxia and/or hypercarbenia (dyspnoea) (60ties – 80ties 20 th century)
- Clinically state which may represent a mixture of 1 or 2 or even 3 obstructive diseases: **chronic bronchitis and emphysema (also certain asthmatic)**
- Other: cystic fibrosis, alpha-1 antitrypsin deficiency, bronchiectasis, bullous lung diseases
- Each case of COPD is unique in the blend of processes; 2 main types of the disease are recognized
- **Epi.:** 4th leading cause of death; 480 mil. people globally (2020), 592 - 600 mil.(2050); 3 millions deaths yearly; more often in man than women (older than 40 y.)
- **Path:** Various, depending on phenotype (form)
 - COPD affects large (central) airways (chron. bronchitis) or the small pathways (chronic bronchiolitis), alveolar ducts, alveoli (emphysema)
 - Predominance of neutrophils and peribronchial distribution of fibrotic changes; massive purulent sputum (ChB), less opalescent sputum (Emph) destruction of alveolar septa)

Causes

Etiology

Cigarette smoke
Smoke from burning

Mechanism(s)

Smoke → inflammatory response → macrophage + neutrophil infiltration into the lungs → release of cytokines, chemokines, elastase + ROS → damages the lung parenchyma.

Occupational exposures to dust and chemicals

Irritants → inflammation → damage to the alveoli.

Alpha-1 antitrypsin deficiency

Alpha-1 antitrypsin (serine protease inhibitor (SERPIN) secreted by the liver into the blood; inhibits the enzyme neutrophil **elastase**

Deficiency a-1 AT leads to **elasteolysis** (destruction of the elastin fibers in alveolar walls) and development of early emphysema (**protease-antiprotease hypothesis** of emphysema development).

Chronic IV drug use

IV drug users of cocaine, methadone and heroin are at higher risk for developing COPD; this is attributed to the **vascular damage induced by the insoluble filler** (cornstarch, cellulose, talc, fiber etc) found in IV drugs.

COPD - Phenotypes

CB predominant in COPD

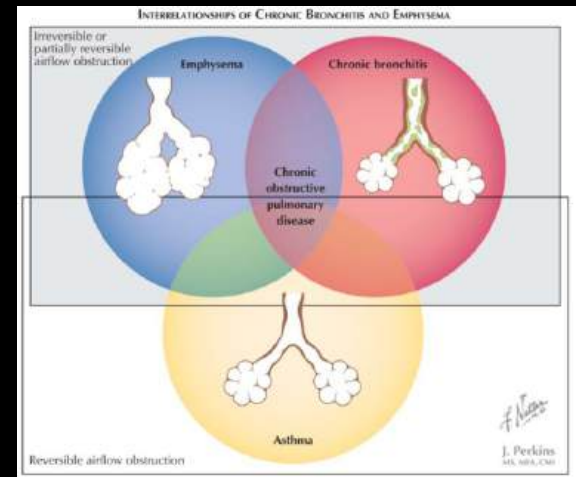
- Cough – persists, worsens after UAW infection
- Sputum - mucopurulent yellow, green, tan, or brown
- Paroxysms of coughing+ expiratory wheezes + splitting pus
- **Cyanosis** - carbon dioxide retention- advanced stages of CB; „blue bloaters" overweight + cyanosis

Emphysema predominant

- Exertional breathlessness - insidious in onset, not prone to carbon dioxide retention.
- Barrel shaped chest, sounds are distant
- Exhalation - prolonged and the lips are pursed during expiration - "pink puffers."

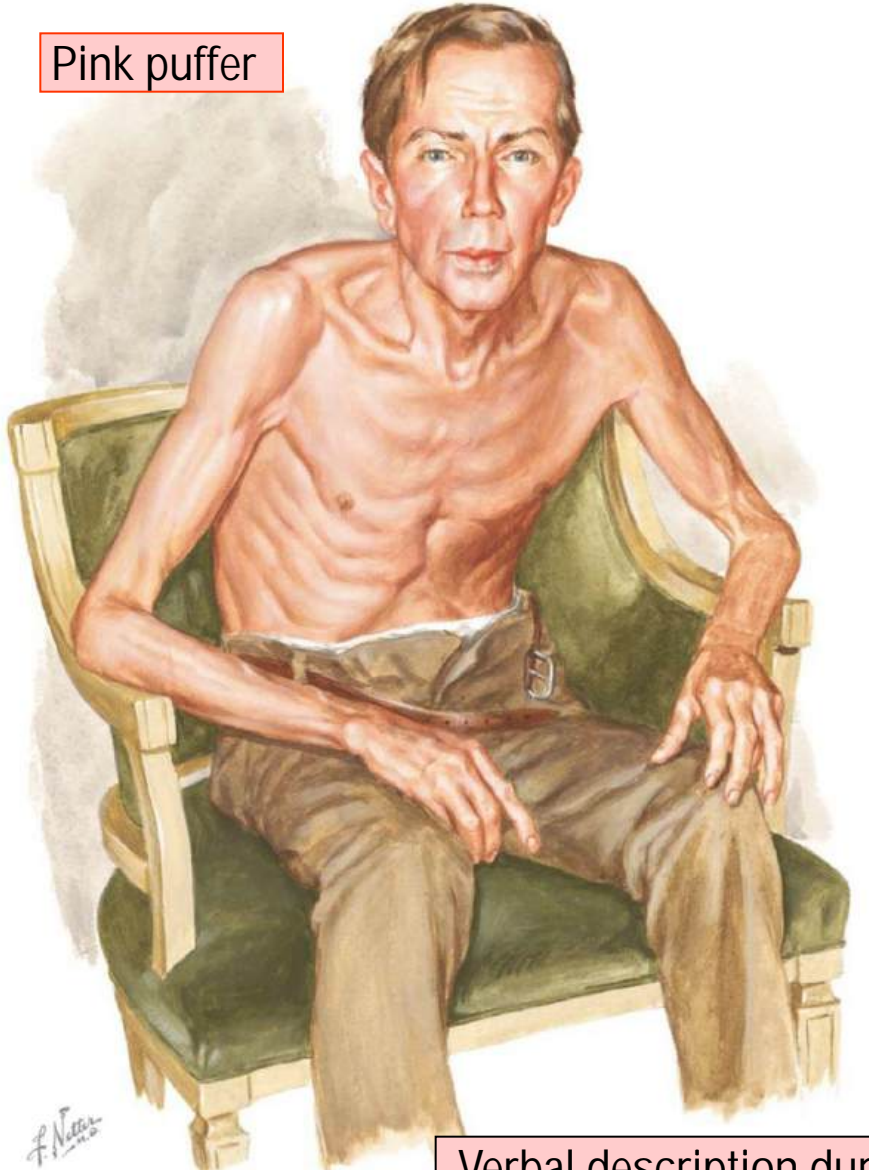
Endstage COPD

- Right heart failure (cor pulmonale); Cough - change in sputum character and volume,
- Breathlessness, wheeze, chest tightness can be triggered by cold, exposure to irritants, or high concentrations of pollutants




COPD - Phenotypes

Pink puffer



Blue bloater



Verbal description during the lecture.

COPD – Laboratory findings

Lab:

- **Chest radiographs** : chronic bronchitis (ChB): increased interstitial markings (but not specific for COPD or ChB). In emphysema, is quite striking. Marked overdistention of the lung fields, flattened diaphragms, and increased retrosternal space are the obvious and classic findings.
- **Sputum analysis**: Gram's staining ChB : Mo/Mf , Neu, T- Ly, Epi,
- **Blood** - a secondary polycythemia (CB or emphysema) ; evidence of eosinophilia → asthmatic bronchitis. During exacerbations, Leu and a left shift may indicate superimposed acute bronchitis or pneumonia.
- **ECG** - evidence of right atrial enlargement and/or right ventricular hypertrophy ← right axis deviation and a posterior axis deviation.

COPD – Laboratory findings

■ **Spirometry** - only criterion standard to demonstrate an obstructive defect -forced expiratory volume in 1 second/forced vital capacity (FEV1/ FVC)

- FEV1/FVC defect is largely irreversible,
- FEV1 fluctuates with bouts of bronchospasm.
- If ratio corrects with therapy, the diagnosis of "asthma,"

Staging of COPD

FEV ₁ actual/predicted	Degree of obstructive defect
>70%	Mild
60%-70%	Moderate
50%-60%	Moderately severe
34%-50%	Severe
<34%	Very severe

overlap syndrome - features both asthma and CB

Histologically eosinophilic bronchitis

Clinically:

CB with asthma features: exposure to tobacco + features of classic asthma, allergies, history of childhood asthma.

Asthma w/o CB: lack of a smoking history. Irreversible chronic airflow obstruction

Chronic bronchitis

- Badham (1808), Laennec (1827) classic description in early 19th century
- presence of a chronic productive cough for 3 months during each of 2 consecutive years
- Occurrence: Prevalence: 300 - 480 million cases globally;
- Histology:
 - Hypertrophy focal of the mucus-producing glands found in the mucosa of large cartilaginous airways
 - Airway smooth muscle hyperplasia, inflammation, and bronchial wall thickening
 - squamous metaplasia, immobilisation of cilia + abnormalities,
 - Neutrophilic infiltrates in the submucosa. Mononuclear inflammation in bronchioles
- Functional:
 - **Lumen narrowing** - mucous plugging, goblet cell metaplasia, + airway distortion due to fibrosis
 - **Airway trapping** – expiratory airflow limitation

Chronic bronchitis

Histology of chronic bronchitis

Pulmonary hypertension Right heart failure in COPD

Elevation of pulmonary artery pressure

Systolic 60
Diastolic 25

Normal readings <25 mm Hg <10 mm Hg

Reduction of pulmonary arterial bed (loss of vessels plus reflex hypoxic vasoconstriction)

Hypoxic vasoconstriction

Ascites, portal hypertension

Peripheral edema

Edemas

Hematocrit increased

Normal Cor pulmonale

Electrocardiogram indicative of right ventricular hypertrophy

I II III aV_R aV_L aV_F
V₁ V₂ V₃ V₄ V₅ V₆

Right heart failure in COPD

Venous distension

Radiograph showing typical enlarged pulmonary artery shadows and outflow tract of right ventricle

Hypertrophy and dilatation of right ventricle, leading to hypertrophy and dilatation of right atrium and to tricuspid insufficiency terminally

Bulge of septum to left may impair left ventricular filling (reverse Bernheim phenomenon)

Enlargement of liver (passive congestion)

Chronic bronchitis

Large cartilaginous airways

Hypoxic vasoconstriction

Mucous gland hyperplasia (elevated Reid index)

Dilated duct of gland

Thickened basement membrane

Squamous metaplasia

Inflammatory infiltrate

Hyperemia

Edema

Fibrosis

Profuse exudate in lumen

Epithelial desquamation

Cartilage intact

Small airways

Goblet cell hyperplasia

Thickened basement membrane

Hyperemia

Inflammatory infiltrate

Exudate in lumen

Edema

Squamous metaplasia

Fibrosis

Chronic bronchitis

Classification:

- **Simple chronic bronchitis** - mucoid sputum production,
- **Chronic mucopurulent bronchitis** - persistent or recurrent purulent sputum production in the absence of localized suppurative disease, such as bronchiectasis,
- **Chronic bronchitis with obstruction** - distinguished from chronic infective asthma (long history of productive cough and late onset of wheezing, in asthma - long history of wheezing with late onset of productive cough).

Causes

Cigarette smoking

- impairs ciliary movement, inhibits function of alveolar macrophages, and leads to hypertrophy and hyperplasia of mucus-secreting glands.
- also increases airway resistance via vagally mediated smooth muscle constriction.

Air pollution


- US (1990): 50,000 to 120,000 premature deaths are associated with exposure to air pollutants."
- Ozone, carbon monoxide, sulfur dioxide etc.

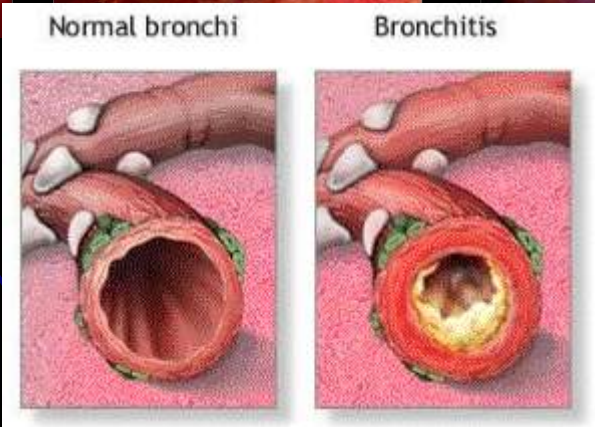
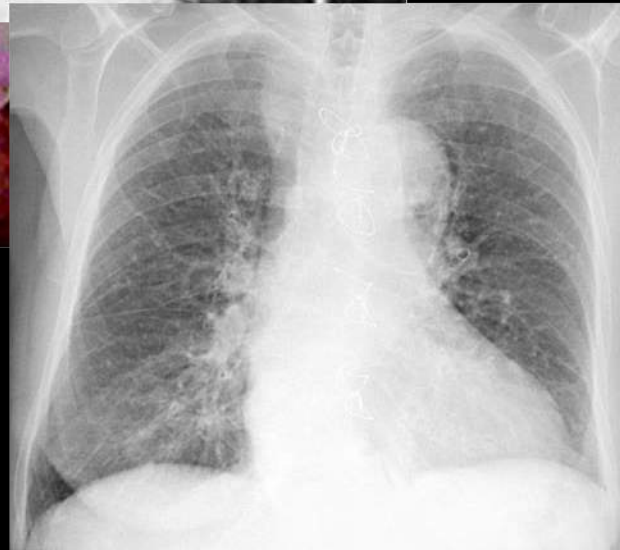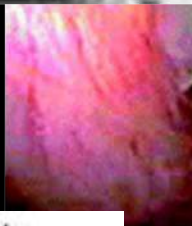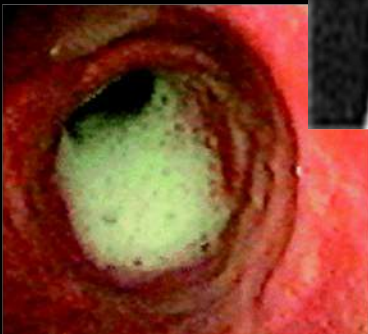

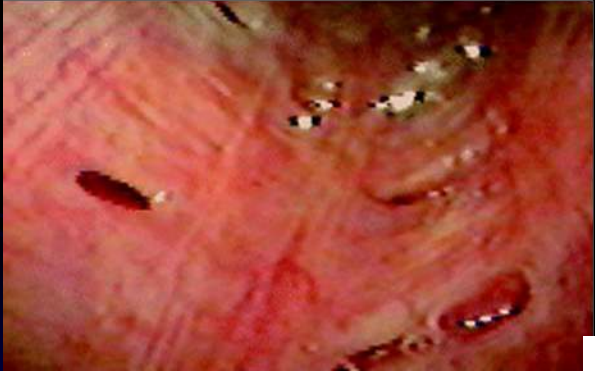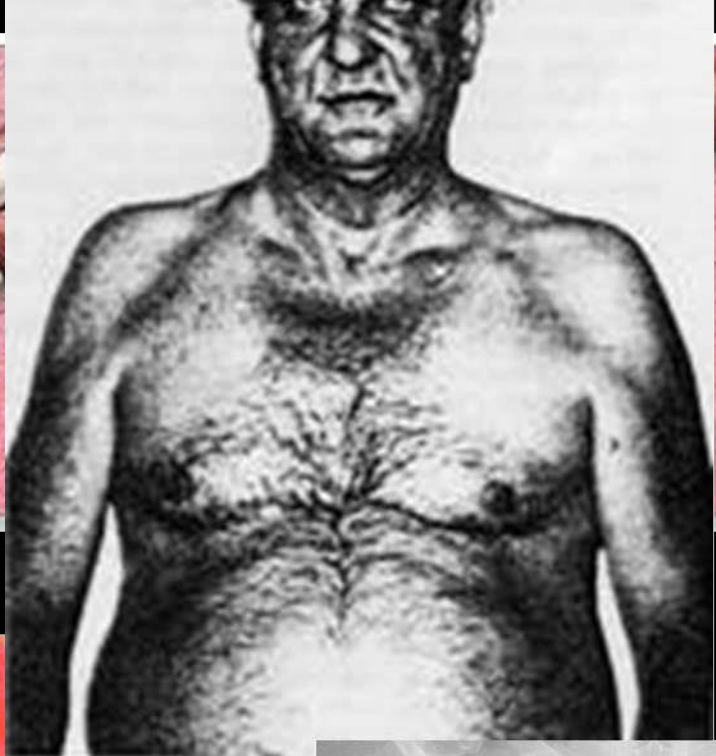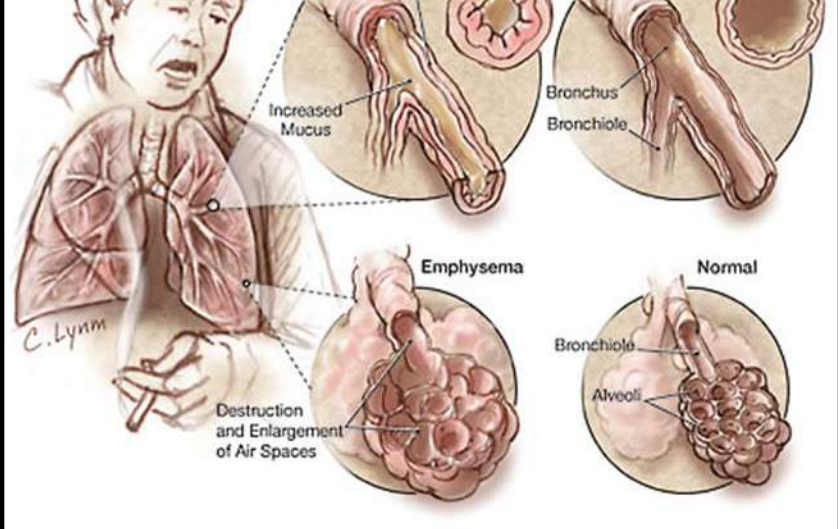
Chronic bronchitis

Key indicators for considering COPD

Indicator	Comments
Chronic cough	Intermittently or every day; often throughout the day, seldom only at night
Chronic sputum	Any pattern could suggest COPD Voluminous, often purulent
Acute bronchitis	Recurrent episodes of bacterial or viral infections superimposed on COPD
Dyspnea	Persistent and progressive; worse after URTI; exercise or activities limited
Risk factors	Tobacco use; pollution; occupational dusts and fumes

Key: COPD, chronic obstructive pulmonary disease; URTI, upper respiratory tract infection.



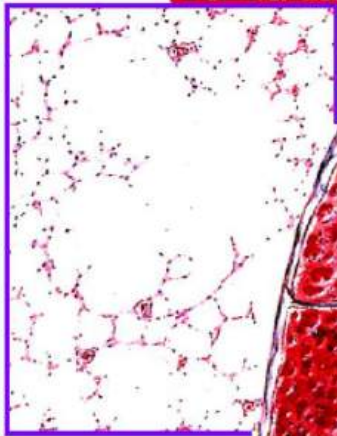
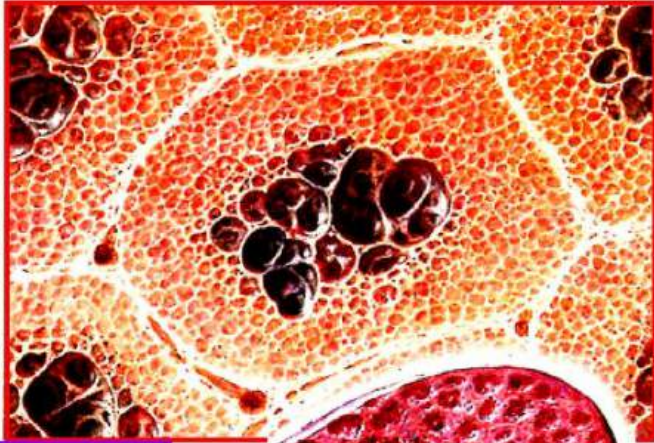


Emphysema

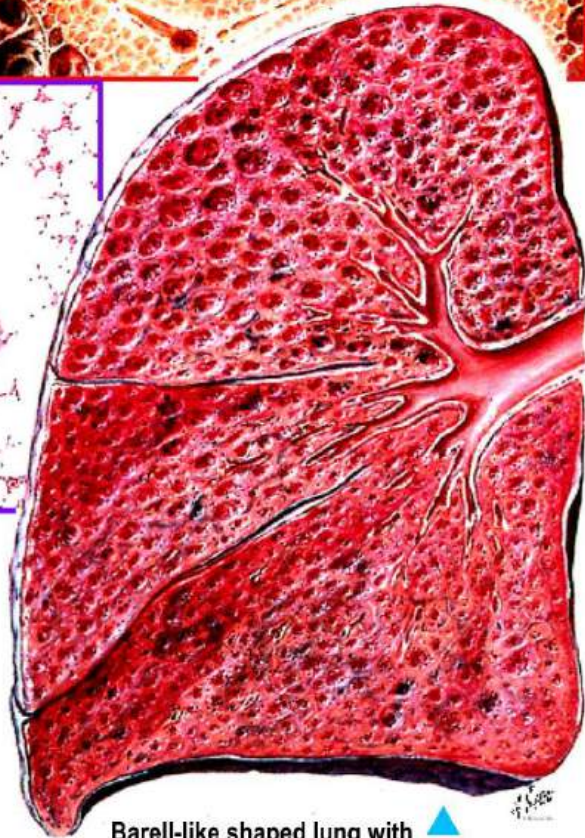
- **Definition:** pathoanatomical: abnormal, permanent enlargement and destruction of the air spaces distal to the terminal bronchioles without obvious fibrosis, progressively lose elasticity and eventual rupture of alveoli.
- **Occurrence:** 2 million in US, most disabling pulmonary disease, more common in males than females
- **Etiology:**
 - Inherited susceptibility - hereditary emphysema – antitrypsin deficiency
 - Acquired in terminal stage of COPD – cigarette smoking
 - Smoking - mortality 20 x greater than nonsmokers, reduced to 5 x in smokers who have quit.
 - Air Pollution – sulphur, chlorine, CO, ozone
- **Pathogenesis:** smoking -> damage of cilia in airways irritating agents stimulate chronic inflammation -> loss of elastin in parenchyme
- **Pathoanatomy:**
 - **Panlobular (panacinar)**- all lung fields, particularly the bases, loss of all portions of the acinus from the respiratory bronchiole to the alveoli, typical for alpha-1-antitrypsin deficiency
 - **Centrilobular (centriacinar)** - upper lobes, loss of bronchioles in the proximal portion of the acinus, and alveolar ducts sparing of distal alveoli. in central portion of lungs, most typical for smokers

Centriacinar emphysema

Distended and communicating sac-like spaces in central area of acini



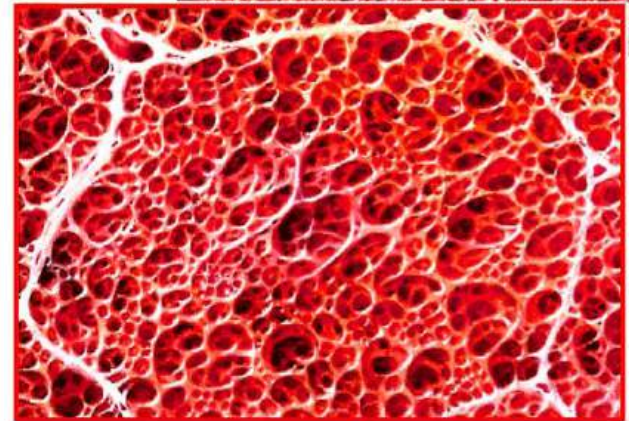
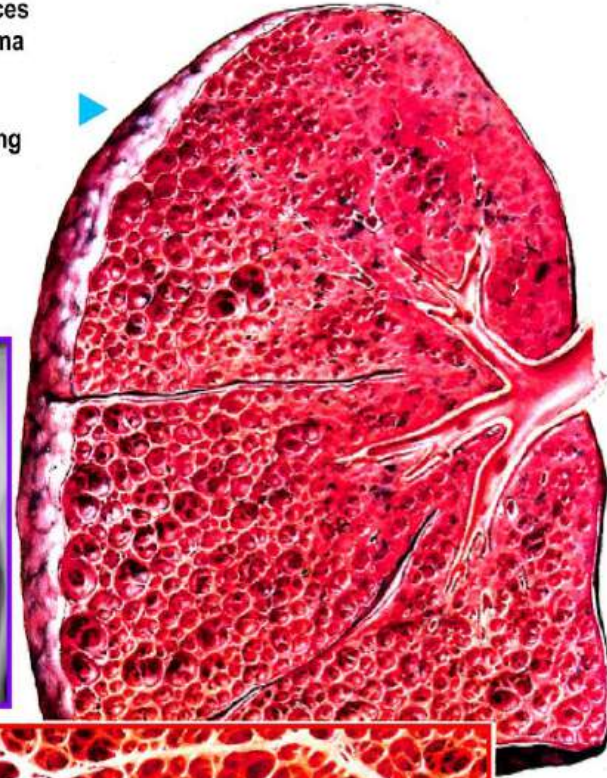
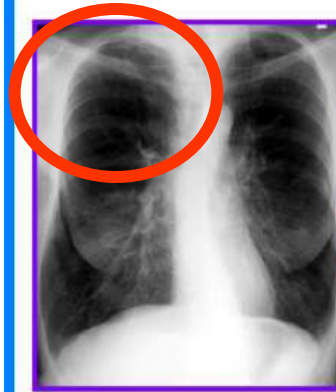
Distended airspaces with rupture of alveolar wall



Barrel-like shaped lung with upper part being mostly affected

Panacinar emphysema

Dilated saccular airspaces in panlobular emphysema due to α 1 - antitrypsin deficiency. Barrel - like shape of lung with lower part being more affected

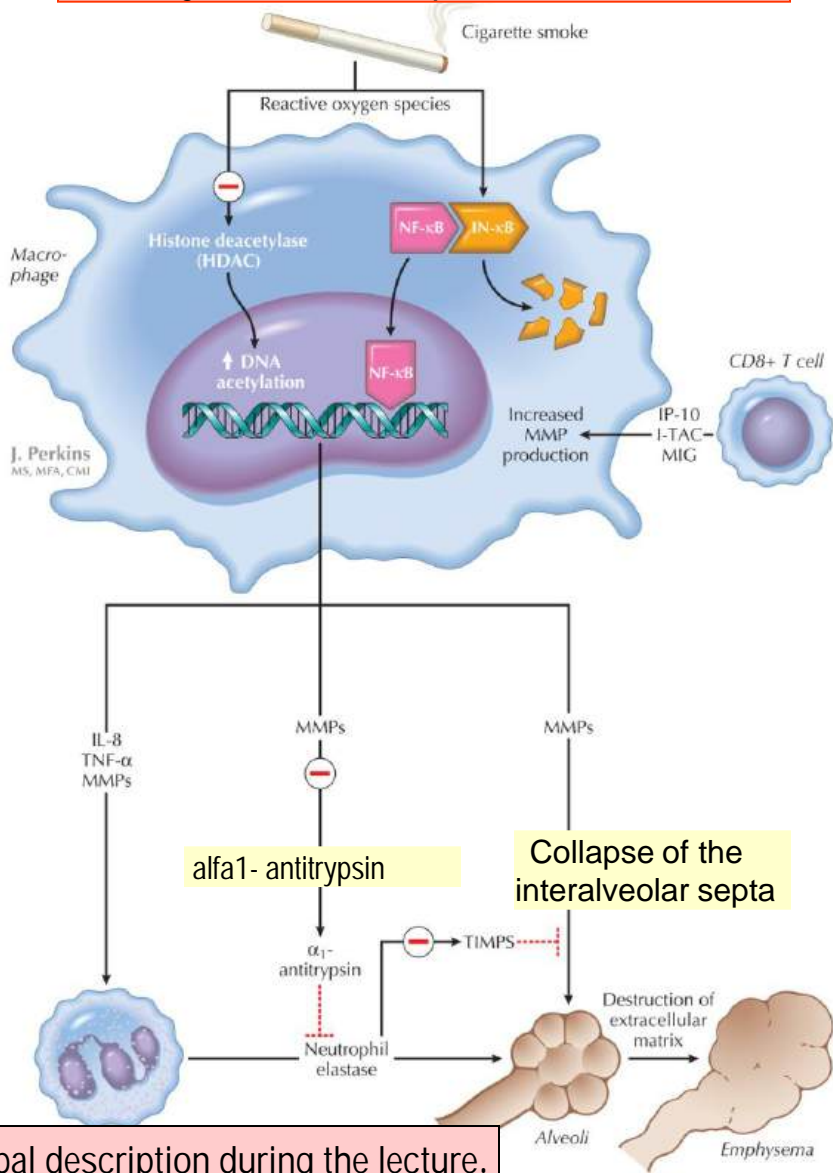


Diffusely enlarged saccular spaces of all portions of acini

Verbal description during the lecture.

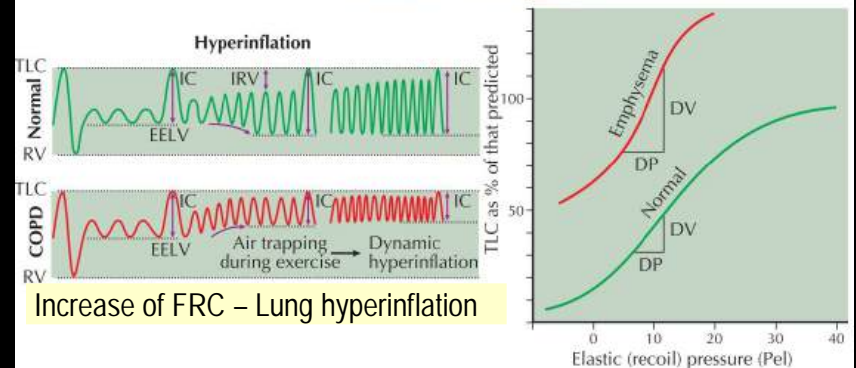
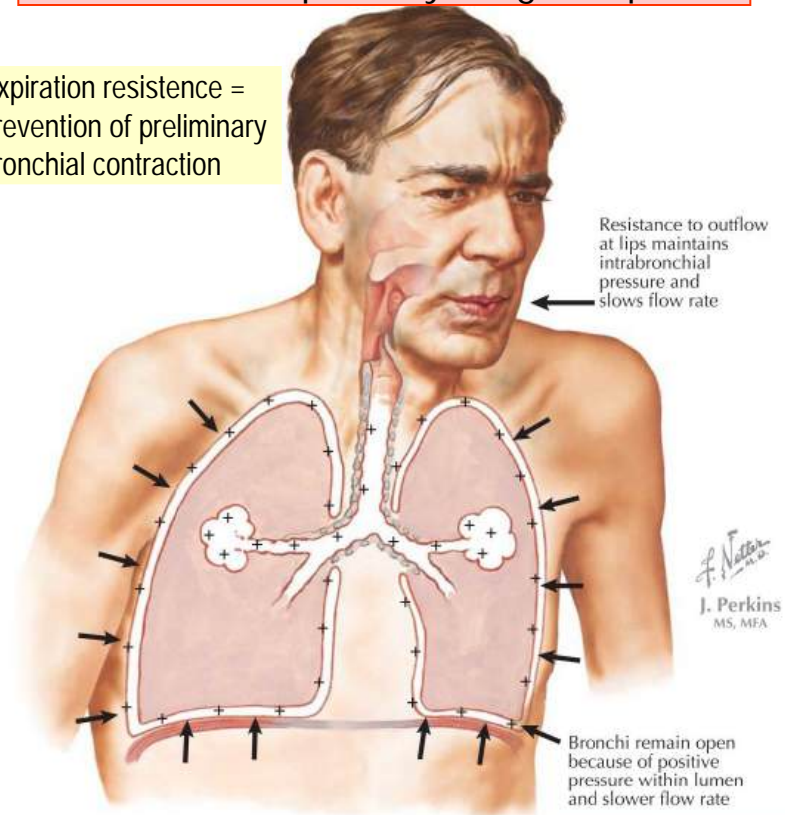
Emphysema

Elastolytic effect of repeated inflammation



Prevention of expiratory lung collapse

Expiration resistance = prevention of preliminary bronchial contraction



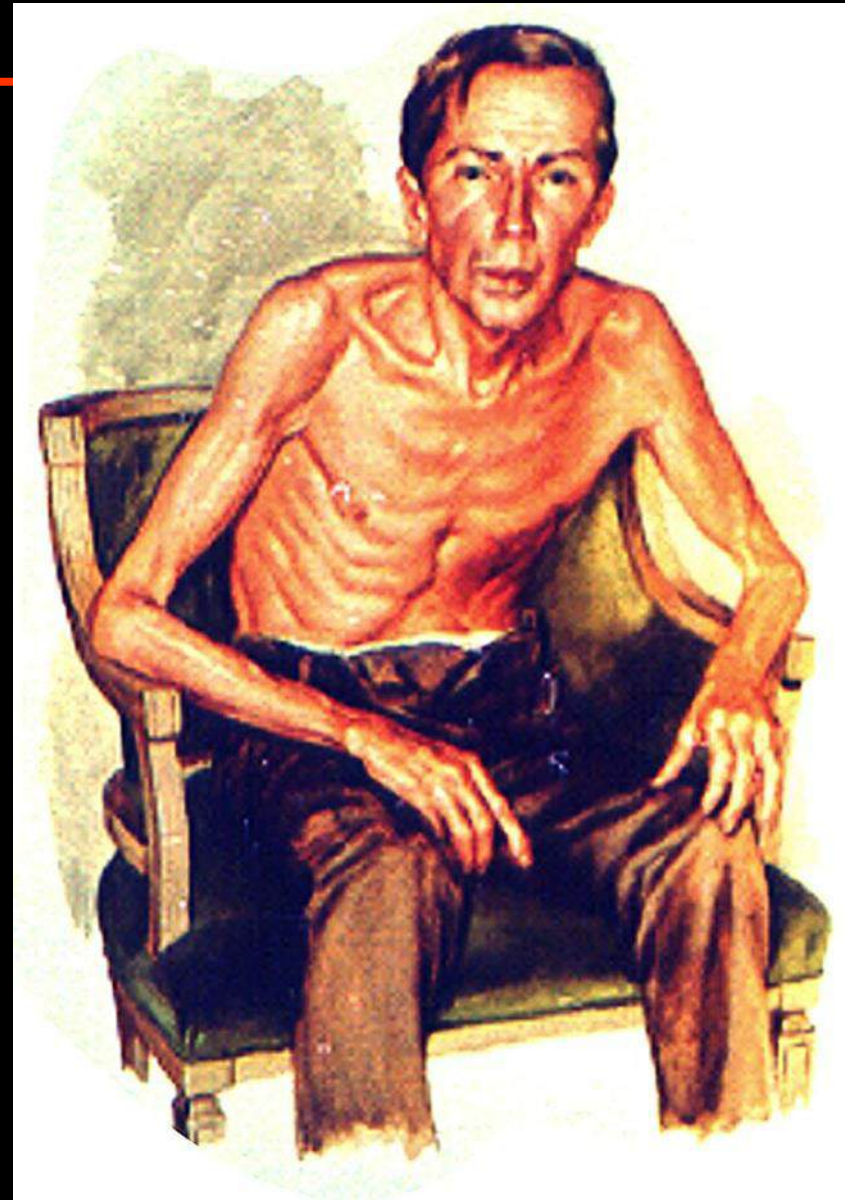Emphysema

■ Signs and Symptoms

- Dyspnea (labored breathing into apical parts of lungs, movement in the fossa above the clavicle, wheezing) even in rest; cough, sputum
- Pursed lip to maximize ventilation (**pink puffer**)
- Right heart failure- labored breathing, husky cough and labored heart rate (less common)
- Hypoxia, resp. acidosis ($\uparrow \text{CO}_2$) (less common)
- Mental vagueness, headache, twitching of fingers and eventual cyanosis (on exertion)

■ Lab. Evaluation

- \uparrow TLV (Hyperinflation), \uparrow RV, \uparrow FRC, \uparrow FEV1
- Diaphragm extended downwards and flattened
- Respiratory muscles are weakened
- X-ray, m CT: barrel chest



Chronic bronchitis vs. emphysema

	Chronic bronchitis (Blue Boater)	Emphysema (Pink Puffer)
General appearance	Overweight, dusky, warm extremities	Thin, often emaciated Pursed-lip breathing – accessory muscles, anxious, cool extremities
Age onset	40-45 y	50-75 y
Symptoms	Cough – very prominent Sputum copious, dark yellow	Dyspnea, cough almost none Sputum scanty, clear
Acute exacerbations	Recurrent infections common	Occasional infections
Cardiovascular changes	Cor pulmonale; fast progress into right heart failure, edema,	During exacerbation & terminal illness cor pulmonale, prolonged course,

Bronchiectasis

- **Def.:** Bronchiectasis = chronic pulmonary condition characterized by the permanent and abnormal dilation of the bronchi and bronchioles ← destruction of the elastic and muscular components of the bronchial walls ← cycle of chronic inflammation and recurrent infection.
- **Epi: Prevalence:** "neglected disease":, elderly women (> 65). **Geography:** developing countries (sequel to childhood infections - measles, pertussis, tuberculosis. In industrial countries: associated with cystic Fibrosis or underlying immune deficiencies.
- **Classification:** Often split into two categories: CF-Bronchiectasis and Non-CF Bronchiectasis
- **Forms (Morphological Types)** Pathologists and radiologists 3 shapes depending on the severity
 - **Cylindrical (Tubular):** The mildest form; bronchi are dilated but maintain a straight, regular outline.
 - **Varicose:** Bronchi are irregularly dilated, resembling varicose veins.
 - **Saccular (Cystic):** The most severe form; bronchi end in large, blind sacs. This is where mucus loves to pool and throw a "bacteria party."
- **Etiology.** anything that impairs lung defense or causes severe inflammation
 - **Post-Infectious:** TB, pneumonia, pertussis (whooping cough), or fungal infections.
 - **Congenital/Genetic:** Cystic Fibrosis (the most common cause in the US), Primary Ciliary Dyskinesia (PCD), and Alpha-1 antitrypsin deficiency.

Bronchiectasis

- Immunodeficiency: Hypogammaglobulinemia (low antibody levels).
- Airway Obstruction: Foreign body aspiration, tumors, or enlarged lymph nodes. Autoimmune/Systemic: Rheumatoid arthritis, Inflammatory Bowel Disease (IBD), or Sjogren's syndrome.
- **Pathogenesis:** accepted model = Cole's "Vicious Cycle" hypothesis of self-perpetuating loop: Initial trigger → infection, genetic defect → impairs mucociliary clearance → Stasis: → Infection: Bacteria (*Pseudomonas aeruginosa*) colonize the stagnant mucus. → Inflammation: neutrophils → proteases / reactive oxygen species → elastin degradation → bronchial wall weakens and dilates → harder to clear mucus out of bronchioles → cycle repeats.
- **Manifestations:**
 - Chronic Productive Cough: The hallmark symptom. Patients often cough up large amounts of foul-smelling, purulent (pus-like) sputum.
 - Hemoptysis: Coughing up blood due to the rupture of hypertrophied bronchial arteries
 - Dyspnea: Shortness of breath and wheezing.

Bronchiectasis

Physical Exam:

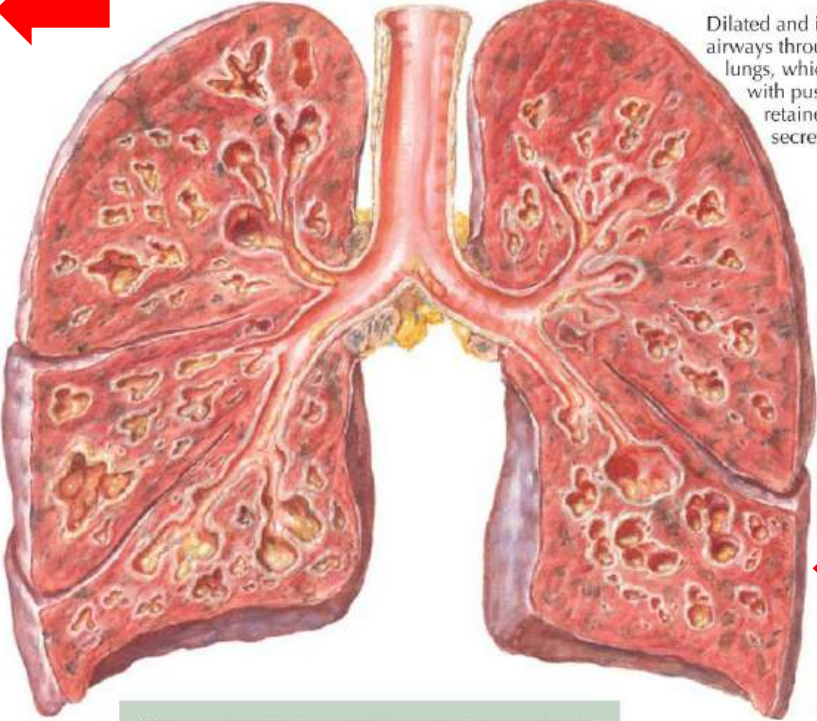
- Crackles (Rales) and rhonchi on lung auscultation.
- Digital Clubbing: A rounding of the fingertips seen in chronic hypoxic states (though less common now with better treatments).

Laboratory Data & Diagnostics

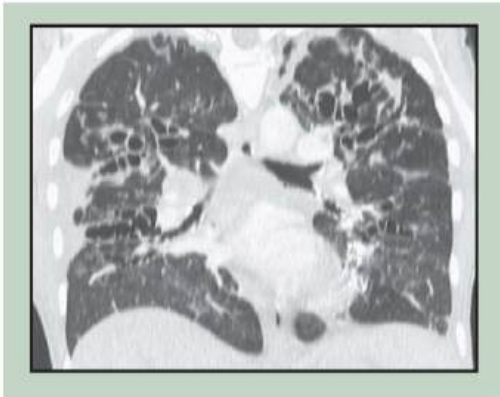
Test	Findings
High-Resolution CT (HRCT)	Signet Ring Sign (airway diameter > accompanying artery) and Tram Tracks (parallel thickened walls).
Pulmonary Function Tests	Usually an Obstructive pattern (low FEV1/FVC ratio).
Sputum Culture	Common finds: <i>H. influenzae</i> , <i>P. aeruginosa</i> , <i>S. aureus</i> .
CBC	Elevated White Blood Cell count (leukocytosis) during flare-ups.
Sweat Chloride Test	Elevated chloride levels indicate CF.

Bronchiectasis

Complicated bilateral form

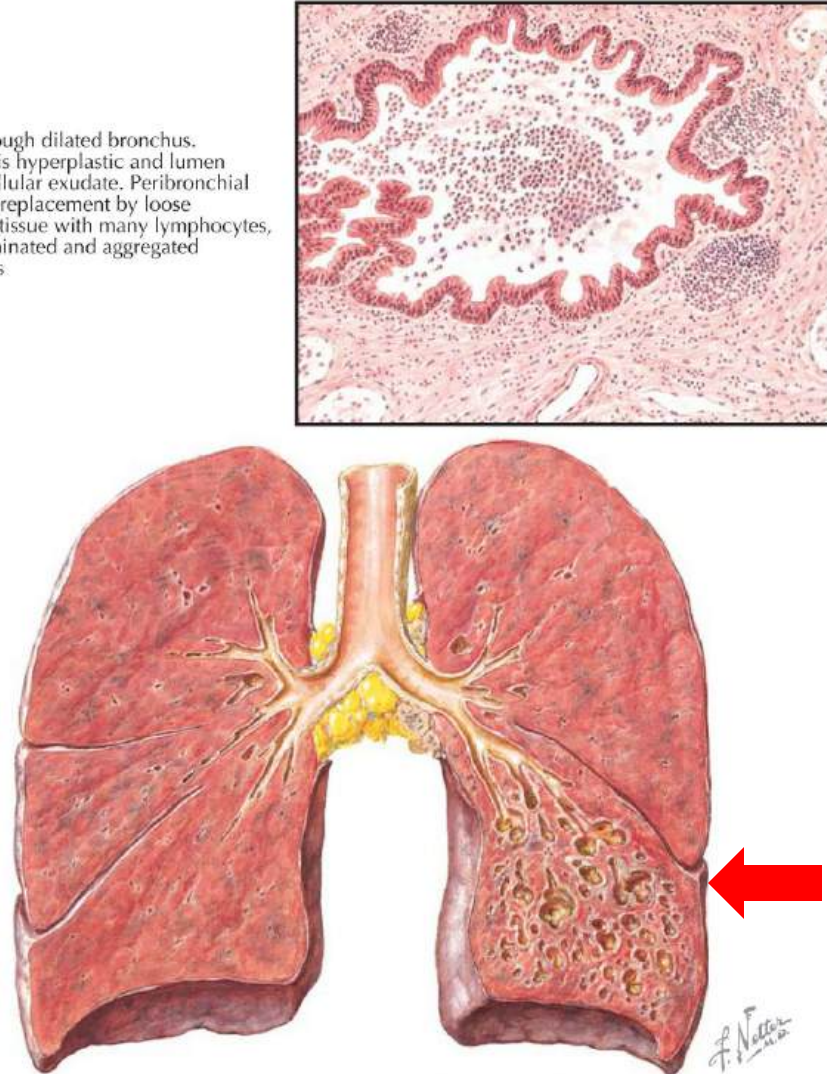


Dilated and inflamed airways throughout the lungs, which are filled with pus and retained secretions.



Extensive bronchiectasis in a patient with rheumatoid arthritis

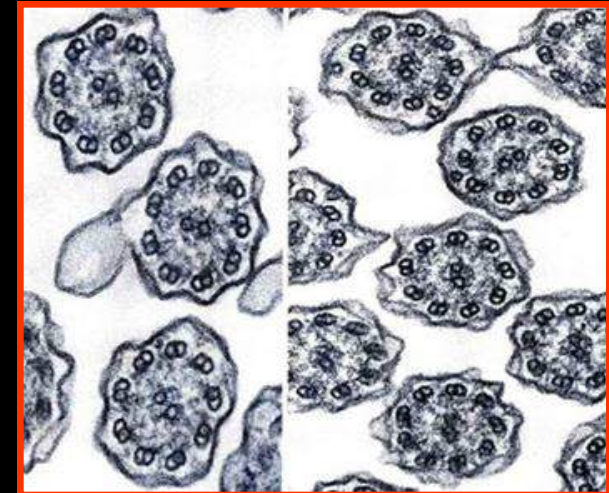
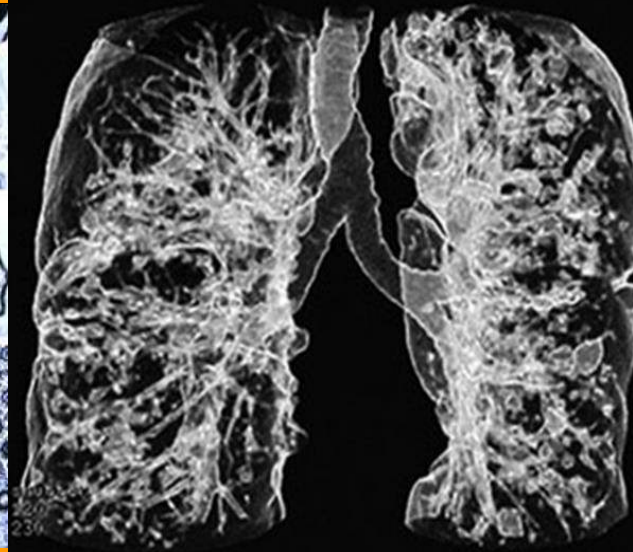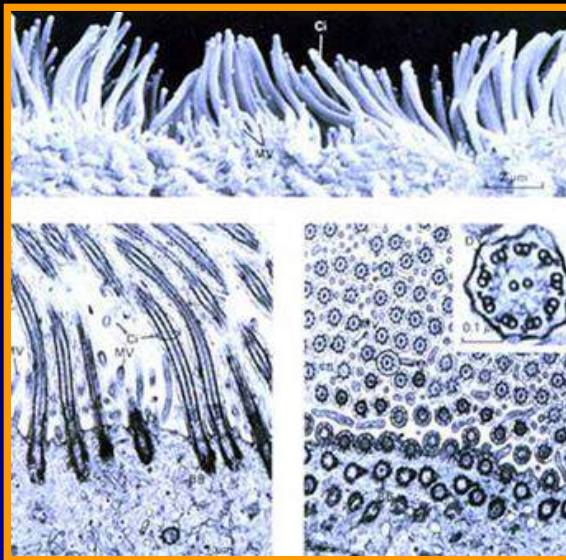
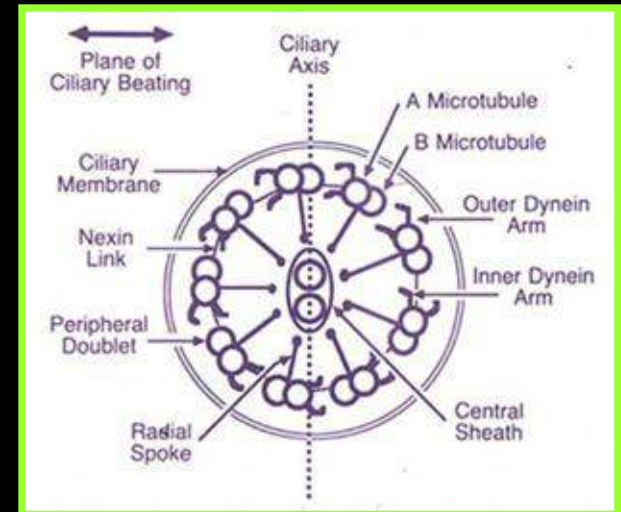
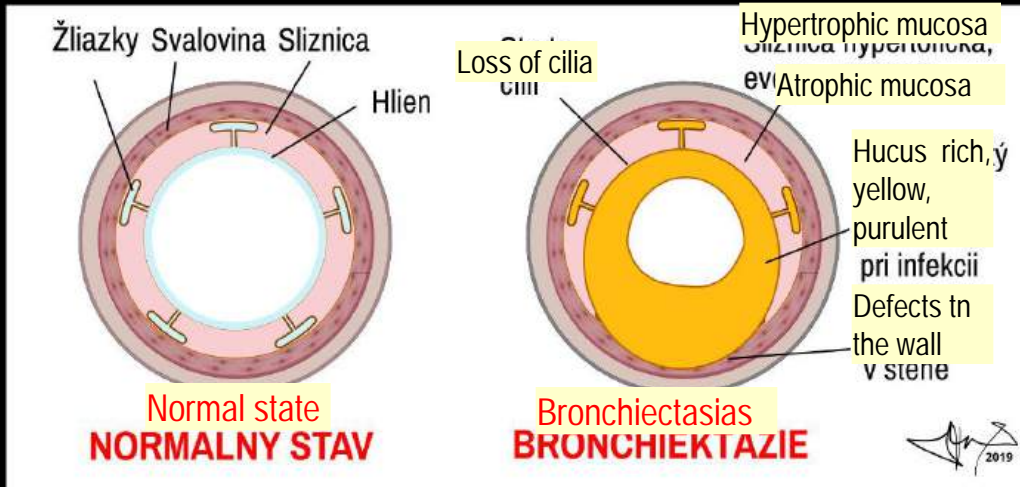
Simple localized form



Section through dilated bronchus. Epithelium is hyperplastic and lumen contains cellular exudate. Peribronchovascular area shows replacement by loose connective tissue with many lymphocytes, both disseminated and aggregated into follicles.

Focal bronchiectasis. Saccular dilations of bronchi, confined to left lower lobe. Such limited pathology may be amenable to surgery

Bronchiectasis - Characteristics

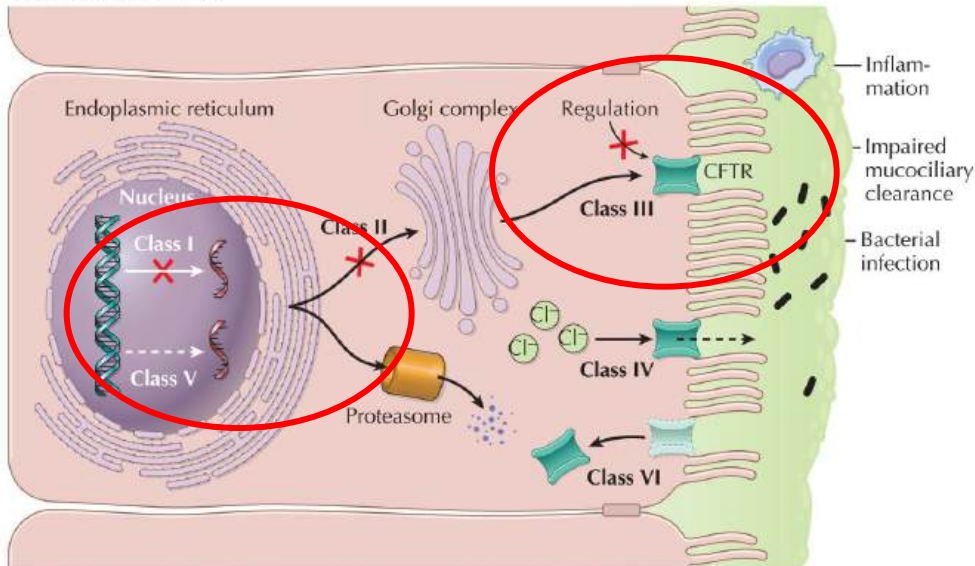


Defective dynein gene may lead to ciliary dyskinesia

Cystic Fibrosis (CF)

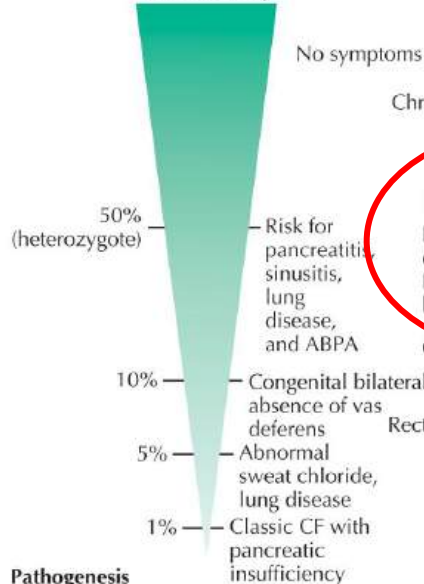
- **Def.:** AR-inherited disease; Ch7q31.2 ; CRTF gene; ABC – chloride/ bicarbonate transporter defect
- **Occ:** 1:2000-3000 living neonates; most common lethal genetic disease amongst children, **Etiology:** genetic disease, affects exocrine gland function, alters chloride transport, thick mucus → bronchial plugs, lung infections
- **Etiology:** defective production of CRTF transporter (class 1-6)
- **Manifestations:**
 - Viscous mucus depositions in lungs → obturation of airways + infections → bronchiectasis → respiratory failure
 - Obturation of pancreatic ducts + choledochus → cholestasis → maldigestion + malabsorption of fat; fat-soluble vitamins; meconium ileus in neonates and kids → exocr. pancreatic insufficiency
 - Reduced fertility (aspermia, defect of ductus def.); nasal polyps
- **Funct. eval.**
 - FEV1 levels drop below 80%
 - FRC (functional reserve capacity) increase due to hyperinflation of lungs during inspiration.
- **Treatment:**
 - replacement of pancreatic enzymes, antibiotics
 - life expectancy can be increased from 12 years to over 30.

CFTR mutation classes

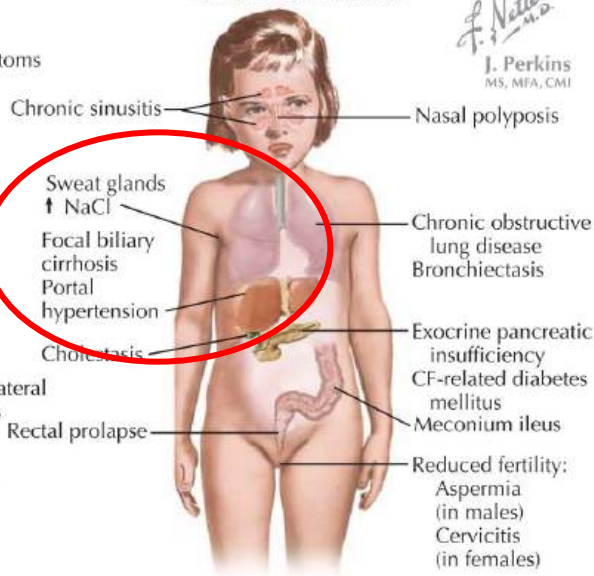


Class I Absent protein synthesis due to defective transcription; **Class II** Defective protein maturation and degradation; **Class III** Defective regulation; **Class IV** Defective chloride conductance; **Class V** Reduced protein synthesis due to reduced transcription; **Class VI** Defective chloride channel stability

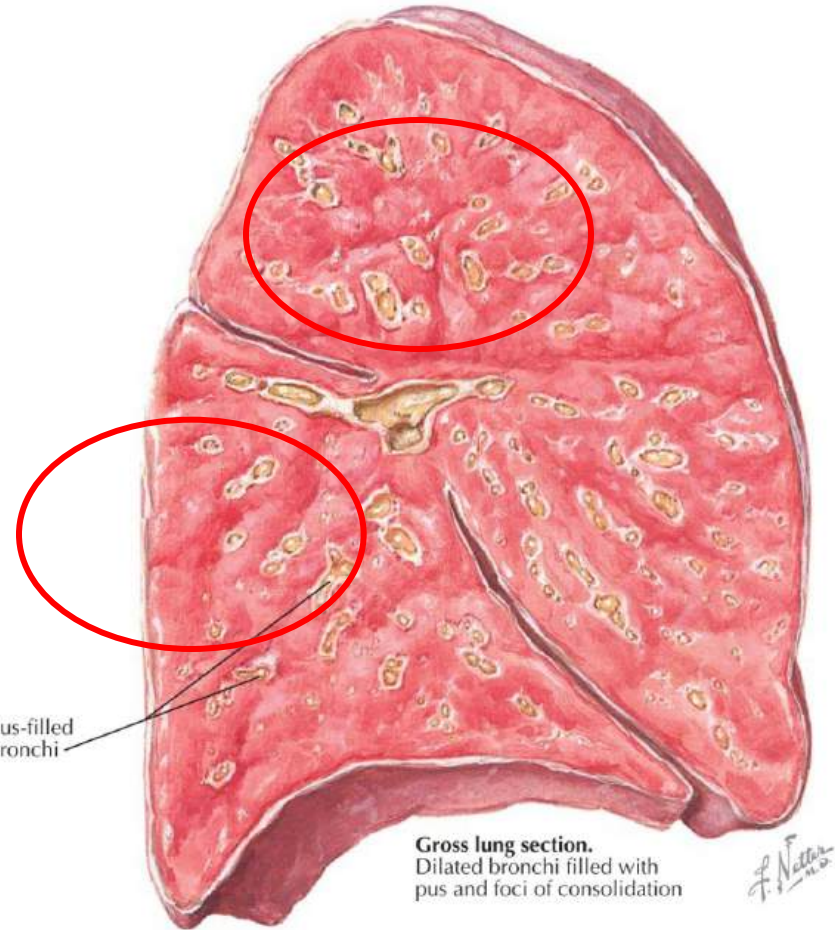
CFTR activity



Clinical manifestations

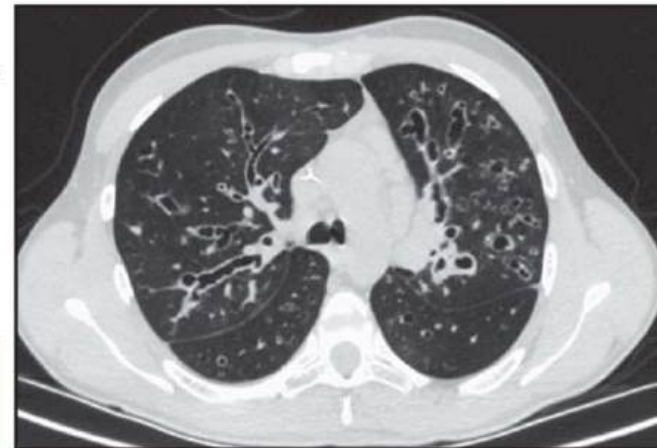


F. Netter M.D.
J. Perkins
MS, MFA, CMI

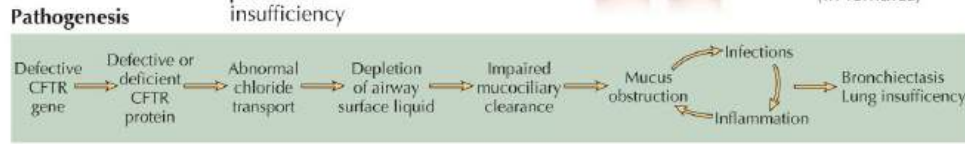


Gross lung section. Dilated bronchi filled with pus and foci of consolidation

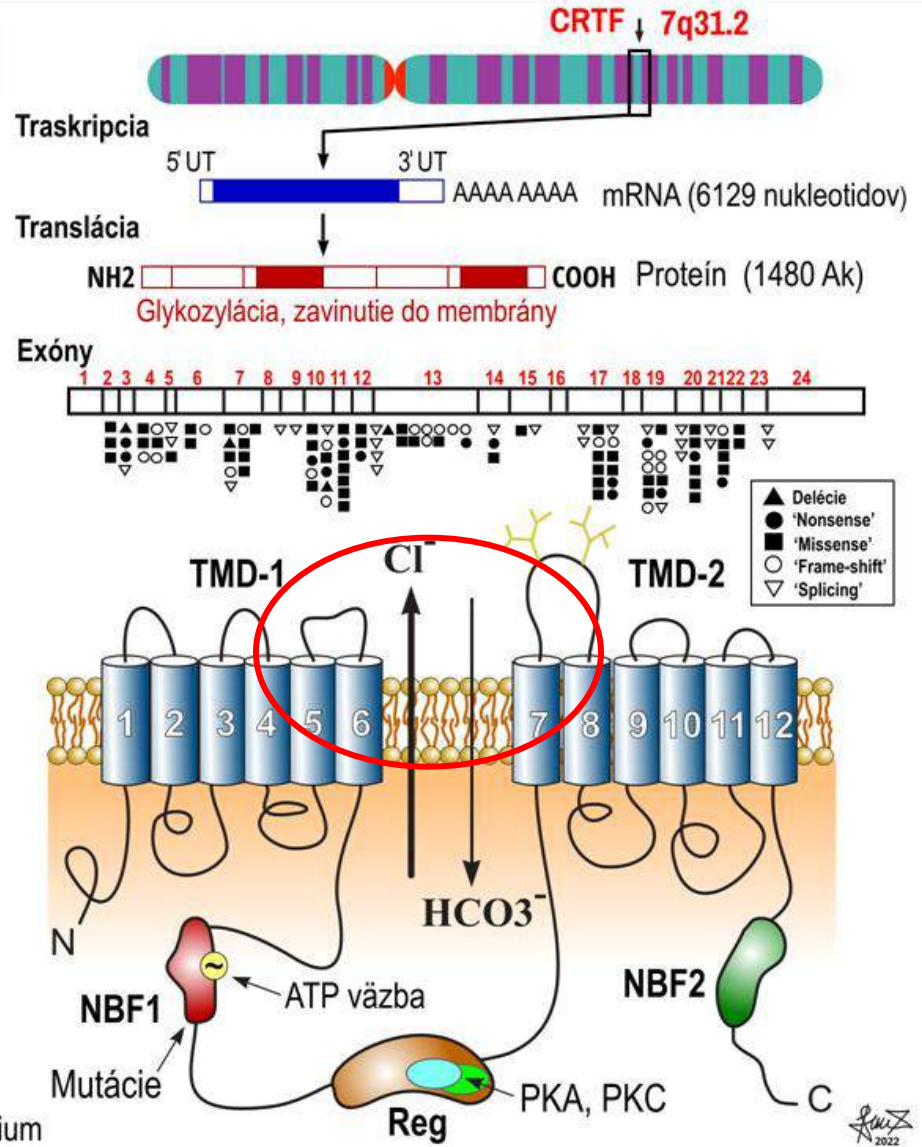
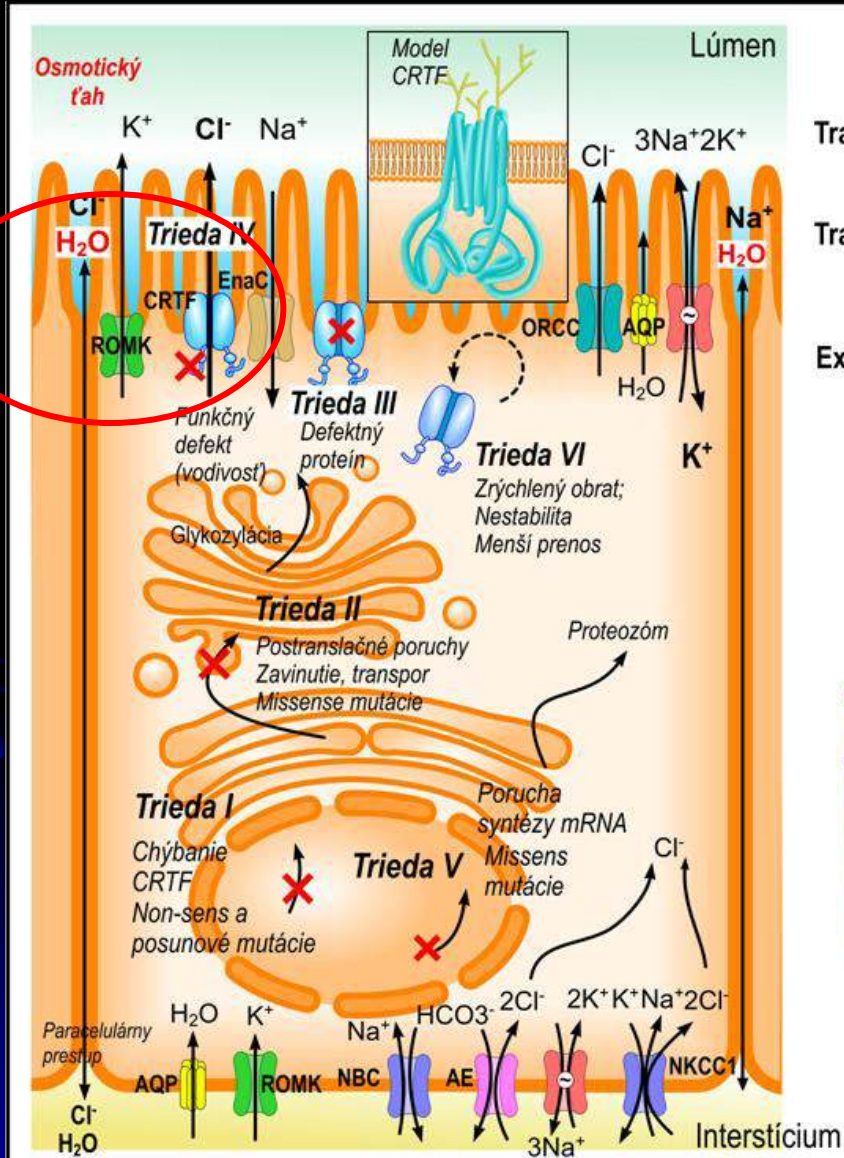
F. Netter M.D.



Bilateral, severe bronchiectasis seen on chest CT in a young patient with cystic fibrosis



Molecular defects



Verbal description during the lecture.