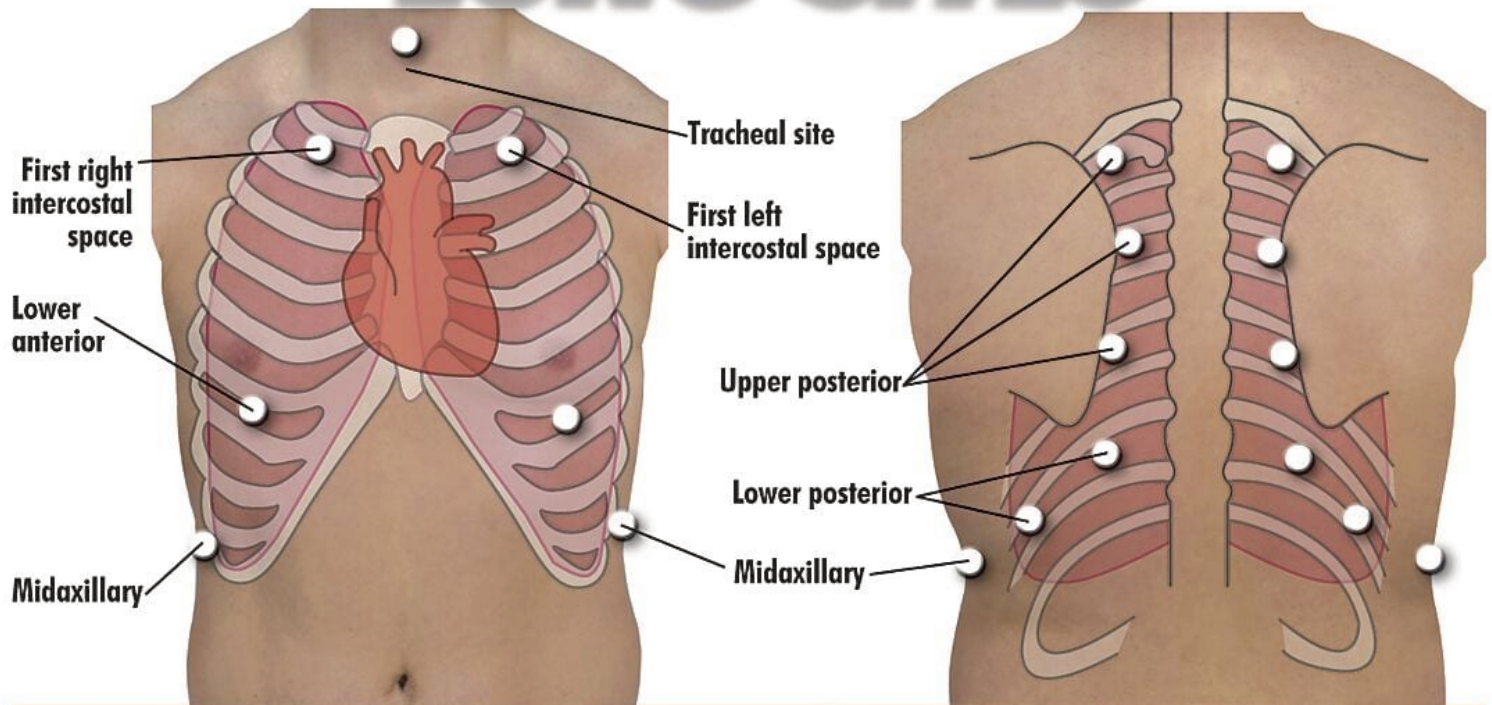


Anterior & Posterior **LUNG SITES**



	Tracheal Site	First Left & Right Intercostal Sites	Upper Posterior Lung Sites	Lower Posterior Lung Sites Two Midaxillary Sites Two Lower Anterior Sites
1. Normal Lung	Tracheal	Bronchovesicular	Normal Vesicular	Normal Vesicular
2. Normal Vesicular	Tracheal	Bronchovesicular	Normal Vesicular	Normal Vesicular
3. Wheezes	Wheeze	Wheeze	Wheeze	Wheeze Lower Volume
4. Mono Wheeze	Mono Wheeze	Mono Wheeze	Mono Wheeze	Mono Wheeze Lower Volume
5. Fine Crackle	Fine Crackle	Fine Crackle	Fine Crackle	Fine Crackle
6. Coarse Crackle	Coarse Crackle	Coarse Crackle	Coarse Crackle	Coarse Crackle
7. Ronchi	Ronchi	Ronchi	Ronchi	Ronchi
8. Stridor	Stridor	Stridor	Stridor Lower Volume	Stridor Lower Volume
9. Cavernous	Cavernous	Cavernous	Cavernous	Cavernous
10. Bronchovesicular	Tracheal	Bronchovesicular	Normal Vesicular	Normal Vesicular
11. Bronchial	Bronchial	Bronchial	Normal Vesicular	Normal Vesicular
12. Pulmonary Edema	Pulmonary Edema	Pulmonary Edema	Pulmonary Edema	Pulmonary Edema
13. Infant	Infant	Infant	Infant	Infant
14. Friction Rub	Tracheal	Bronchovesicular	Friction Rub	Friction Rub
15. Egophony	Egophony	Egophony	Egophony	Egophony
16. Pecoriloquy	Pectoriloquy	Pectoriloquy	Pectoriloquy	Pectoriloquy